



The results of reverse-flow island flaps in pulp reconstruction

Murat KAYALAR, Emin BAL, Tulgar TOROS, Kemal ÖZAKSAR, S. Tahir SÜĞÜN, Yalçın ADEMOĞLU

Hand and Microsurgery Hospital, İzmir, Turkey

Objective: The aim of this study was to retrospectively review the results of homodigital reverse-flow proximal or middle phalanx dorsal skin island flaps.

Methods: We reviewed the overall results of 67 dorsal skin flap reconstructions performed on 61 proximal phalanxes and 6 middle phalanxes at our hospital during an 11-year period. The results were evaluated with static two-point discrimination, Semmes-Weinstein monofilament test, occurrence of nail deformities, loss of interphalangeal joint motion, scar appearance of flap donor area, the incidence of vascular insufficiency in postoperative period, and subjective evaluation of patient satisfaction.

Results: The highest incidence of defect types were palmar oblique pulp defects in 18 patients (26.8%), transverse pulp defects in 16 patients (23.8%), and hemipulp oblique amputations in 11 patients (16.4%). Crush injuries were the cause of injury in 66% of patients. The average follow-up time was 40 months and long-term results were available in 21 patients. Total necrosis of flap in one patient (1.4%), superficial epidermolysis in 4 patients (5.9%), and nail deformity in 4 patients (5.9%) were seen. According to Semmes-Weinstein monofilament test results, protective sensation was achieved in 76% of patients. Static two-point discrimination data showed variable distribution between 2 mm and 11 mm. The subjective patient satisfaction level was 95%.

Conclusion: Homodigital reverse-flow proximal or middle phalanx dorsal skin island flaps give satisfactory cosmetic and sensorial results outside the pinch area, even if the dorsal branch of the digital nerve is not included.

Key words: Homodigital; reverse-flow; phalanx; pulp reconstruction.

The reconstruction of the pulp sensory pad is important to preserve functional hand capacity. Attempts have been made to restore all 3 tissues (bone, nail bed and palmar sensory pad) in the pulp via reconstruction techniques. For this reason, tissue transfer for the fingertip, grafts for the nail bed and bone grafts for the distal phalanx are used. An ideal technique for fingertip reconstruction should provide a stable and pain-free finger with sensation.

Reverse-flow island flap was defined by Weeks and Wray in 1973.^[1] Its indications and results were further evaluated through Lai and Kojima's patient

groups.^[2-5] Direct-flow neurovascular island flaps, direct-flow dorsal middle phalanx flaps (MPF) and reverse-flow proximal phalanx flaps (PPF) are options that can be used from the same finger.^[6-18]

Whilst acknowledging that they attain less sensation quality, proximal and middle phalanx flaps have a wider rotation arc. They can also be lifted both homodigitally and heterodigitally. Dorsal side defects of proximal and distal interphalangeal joint (PIP/DIP), hemipulp oblique amputations and losses of over 1.5 cm of the palmar sensory pad are different indications for reverse-flow flaps.^[2-5,7,8,19-22]

Table 1. Number of injured fingers and the distribution of the flap sites.

Finger	Number of flaps	Location	Percentage
Second finger	24	18 ulnar, 6 radial	%75 ulnar, %25 radial
Third finger	27	15 ulnar, 12 radial	%55.5 ulnar, %44.5 radial
Fourth finger	12	8 ulnar, 4 radial	%66.6 ulnar, %33.3 radial
Fifth finger	4	3 radial, 1 ulnar	%75 radial, %25 ulnar

In this study, we retrospectively evaluated the long-term sensorial and functional results of homodigital reverse-flow island flaps, using proximal phalanx and middle phalanx dorsal skin. Our aim was to clarify the indications for direct or reverse-flow flaps in pulp reconstruction.

Patients and methods

Patients who underwent reverse-flow skin flaps, using proximal or middle phalanx dorsal tissue at our hospital between June 1997 and September 2008 were included in this study. Heterodigital, thumb-related or direct-flow MPF / PPF were not included in the study. A total of 67 fingers of 60 patients (57 male, 3 female), whose records were taken from the hospital database, were found to match the criteria.

Thirty-one patients had right hand injuries and 29 had left hand injuries. The injuries of 40 patients (66.6%) were crush-related. The most common injuries were of the 3rd finger (n=27, 40%). Other fingers included were the 2nd (n=24), the 4th (n=12), and the 5th (n=4) (Table 1). Eighteen patients (30%) had adjacent finger injuries. The average age of the patients was 30.8 (range: 8 to 54) years. Injury types in order of frequency were; palmar oblique pulp loss in 18 fingers (26.8%), transverse pulp loss in 16 fingers (23.8%), hemipulp oblique amputation in 11 fingers (16.4%), DIP joint dorsal loss in 10 fingers (14.9%), dorsal oblique loss in 8 fingers (11.9%), PIP joint dorsal loss in 3 fingers (4.47%), and hook nail correction in one finger (1.4%). All patients received operations on their first day. Of the 60, five patients came into the hospital with an average delay of 20 (range: 7 to 30) days after the injury. Of these, three were treated in other health centers and showed distal tip necrosis. In the other two patients, one had an atonic wound and the other presented with an injury caused by a belt.

Flap coverage was performed on 67 fingers of 60 patients. Flaps where the proximal phalanx dorsal

skin flap was used were performed on 61 fingers and 6 patients underwent reverse-flow dorsal middle phalanx flap. Seven patients underwent flap procedures on two fingers (Fig. 1).

All surgeries were conducted according to Lai's description.^[2] The injury was assessed whether to include the interarterial anastomosis areas within the injury site as a precaution against flap circulation failure. The decision for reverse-flow flap was taken in this regard. The skin on the proximal phalanx and the middle phalanx was marked as wide as the defect area (Fig. 2). The skin island was determined to be up to the opposite mid-lateral line. An incision was made over the mid-lateral line and the neurovascular bundle was found between the Grayson's and Cleland's connections. The pedicle proximal to the flap island was found to be healthy. The dissection was extended toward the skin island, the perivascular fatty tissue was preserved for venous return, and

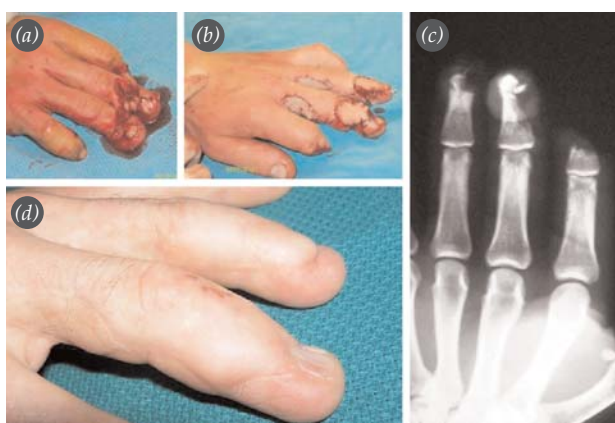

Fig. 1. PPF procedure performed on two adjacent fingers. (a) Injury where the palmar sensory pad is preserved in the third-fourth finger DIP joint and which involves soft tissue and bone loss in the dorsal. (b) Soft tissue repair was performed using a reverse-flow proximal phalanx flap. (c) For bone insufficiency, the DIP arthrodesis was constructed using a bone graft. (d) 9-year follow-up image of the flap. SWM=6.65, s-TPD=7 mm. [Color figure can be viewed in the online issue, which is available at www.aott.org.tr]

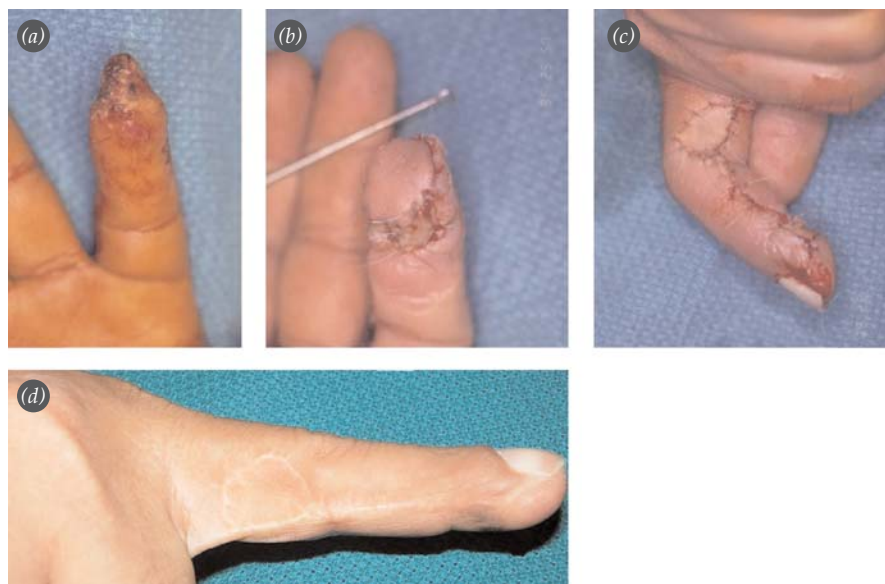


Fig. 2. (a) Loss in the second finger pulp as a result of injury caused by a belt, (b, c) Reconstruction of the volar tissue via a reverse-flow PPF from the ulnar side of the finger. (d) Pulp and nail appearance twelve years later. In order to avoid compression over the pedicle in the distal, covering with a skin graft was the preferred method. SWM=4.31, s-TPD=4 mm. [Color figure can be viewed in the online issue, which is available at www.aott.org.tr]

the flap island was elevated. The digital artery was cut proximally and it was then dissected along with pedicle toward the distal. Where necessary, the dorsal sensory division of the digital nerve was included in the flap skin island for MPF. During the dissection of the digital artery toward the distal, its branches in the middle phalanx or the DIP joint level were preserved in order to receive flap's blood supply from the opposite digital artery. The flap was carried to the pulp not through a subdermal tunnel, but a skin incision. In cases where the skin was tensioned, skin graft coverage was performed.

Additional procedures included dorsal sensory division anastomosis on three patients, DIP arthrodesis on one patient, bone graft in one patient (Fig. 1), and a tendon graft in one subject, with anastomosis of the vein belonging to the transferred flap to the superficial veins (Table 2).

Standard plaster cast immobilization was used for seven days after surgery. Wound coverage was then continued with finger dressings. Active finger movement was introduced in the second week. Physiotherapy was recommended for cases with a PIP movement below 60 degrees during the first 15 days. All patients were followed for three months postoperatively. Follow-up ceased when healing was complete and active PIP movement reached 90 degrees.

In follow-up, the finger's PIP/DIP range of motion, nail deformity, donor area assessment,

Weber's static two-point discrimination (s-TPD), Semmes-Weinstein monofilament test (SWM) and cold intolerance were assessed. The patients' personal satisfaction, regarding the performed surgery, was also questioned subjectively.

Results

Following a mean follow-up period of 39.7 (range: 3 to 117) months, only one flap developed necrosis, which was later recovered with a cross finger flap.

Hook nail deformity developed in 4 fingers (5.9%). A 10 degree flexion contracture in the PIP joint was also detected in one patient and one patient showed mallet deformity as a result of 30 degrees of extension loss in the DIP joint. In the early postoperative period, skin margin necrosis and superficial epidermolysis was observed in four tissue transplantations (5.9%). All these complications were resolved through wound care and treatment. Hyperaemia and warmth were

Table 2. Additional procedures.

Additional procedures	
Arthrodesis	n=1
Tendon graft	n=1
Bone graft	n=1
Vein anastomosis	n=1
Dorsal sensory branch reinnervation	n=3
Deepithelialized cross finger flap	n=1

detected in one patient in the flap postoperatively. The superficial infection was treated with antibiotics. Early and late complications are listed in Table 3.

The skin island surface area ranged between 3.5x2 cm and 1x1.5 cm. For one patient, who underwent MPF, the vein that was included in the skin island in order to prevent venous insufficiency was anastomosed to the superficial veins. No circulation problems were observed in this patient.

In the 21 patients who were available to their last follow-up evaluation (an average of 9 years of follow-up) 25 flaps were assessed for range of motion. As a result of the sensory assessment, s-TPD in 15 patients (71%) were found to be 7 mm and above, whilst 6 patients were found to have it below 7 mm (2, 6, 4, 4, 4, and 6 mm). SWM values were measured as; 3.61 in two patients, 4.31 in nine patients, 4.56 in five patients and 6.65 in five patients (76% protective sense). The data of other flaps performed on the same hand were measured to be equal. Cold intolerance was detected in only one patient. Patient satisfaction with the procedure was 95%. No patient had complaints regarding the donor site at the time of this study.

Discussion

Indication is dependent on proper identification of the injury site. In injuries that go beyond the DIP joint, it is assumed that the furthestmost distal interdigital artery anastomosis is damaged; therefore, it is more advantageous not to perform flap for the pulp. Using PPF, in cases where the palmary tissue is preserved, can be considered safe with regard to flap circulation.^[2-7,9,23-27]

When direct-flow flap is possible, the choice of reverse-flow flap is not clear. One of the aims of this study was to contribute to the clarification of this point.

We have defined the direct-flow version of MPF in cases of large palmar oblique pulp losses.^[28] In cases of palmary pulp losses, direct-flow neurovascular island flaps which have better sensation are usually the first option.^[16-18] However, in losses of more than 1.5-2 cm toward the DIP proximal, a wider skin island is necessary. Elevating the MPF in a direct-flow rotational way in order to cover up the pulp meets this necessity. A reverse-flow PPF and MPF from the same finger when the sensory division of digital nerve is included also serves this purpose.

Table 3. Complications.

Complications	
Complete necrosis	n=1
Partial loss, epidermolysis	n=4
Superficial infection	n=1
PIP joint flexion contracture	n=1
DIP joint extension lag	n=1
Cold intolerance	n=1

In our series, palmary oblique pulp loss was evident in 18 cases (%26.8). For palmary oblique injuries, PPF and MPF were used 3 times on the second finger and 6 times on the third finger. However, the number of second and third finger injuries totaled 51. Unless the loss in the pinch area of the first three fingers required a larger skin island, reverse-flow flaps were not our first choice (Fig. 3).

Indications for the use of PPFs in pulp reconstruction procedures have narrowed. Currently applicable indications; dorsal, dorsolateral, hemipulp oblique not on the touching surface, and transverse amputations, and atypical losses (DIP and middle phalanx or PIP dorsal) are also involved within the PPF/MPF rotation arc. Third finger pulp losses are also special indications for PPF and MPF. This is due to the fact that, because of its length, the third finger is not eligible for tissue transplantation from adjacent fingers (Fig. 4). In most cases, not much thought has been given to elevating the flap from the side where the digital artery is dominant. Keramidas et al. also noted a reverse-flow flap indication for dorsal losses.^[6]

In our patient group, the largest flap dimension was 3.5x2 cm and in some cases included the dorsal skin from the ulnar to the radial side. However, it is not recommended to cross the Lai's line toward the palmary side. The ideal skin island includes as many of the dorsal perforating palmary digital artery (PDA) branches as possible.^[2-7,29]

The inter-anastomosis of digital arteries, their perforating branches leading into the dorsal skin, and the territories formed by these branches have been studied in detail.^[26,29-32] Flaps that make use of the connections between the dorsal metacarpal artery (DMA) system in the hand dorsal and the dorsal

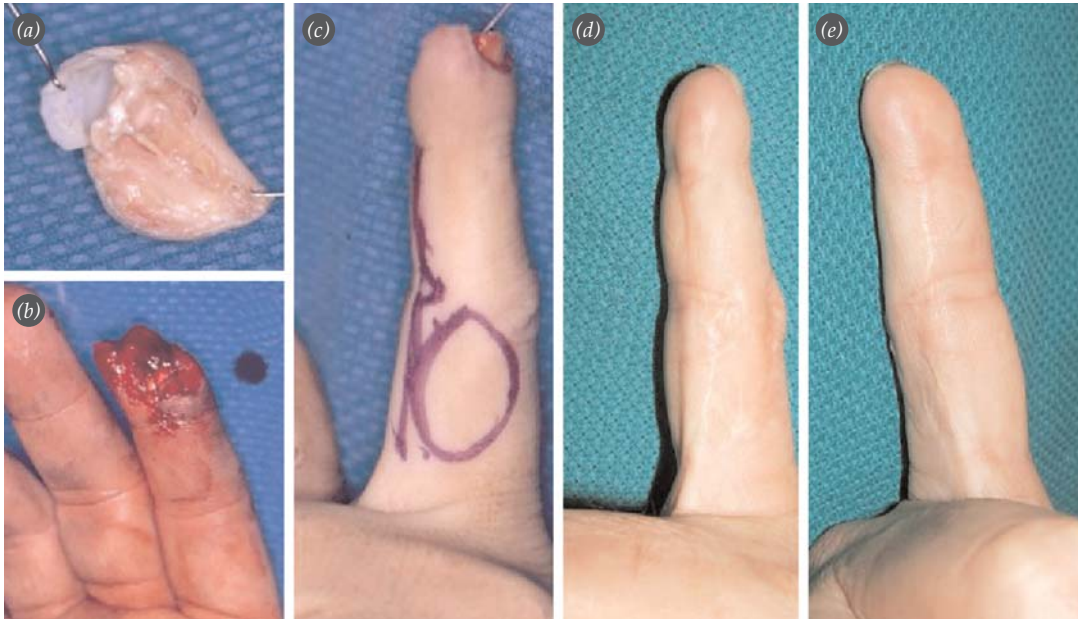


Fig. 3. (a, b) After being caught by machinery, avulsion type distal tip amputation of the index finger. It was not possible to detect any tissue appropriate for replantation on the distal part. (c) Soft tissue reconstruction by PPF from the ulnar side of the finger. (d, e) SWM=4.31, s-TPD=4.31 mm. At the end of twelve years, a slight formation of hook nail is evident. [Color figure can be viewed in the online issue, which is available at www.aott.org.tr]

branches from PDA in the finger (dorsal digito-metacarpal flaps) have also been defined.^[6,24,33-35]

As information about arterial anatomy increases, it appears more practical to use reverse-flow flaps taken from the same finger (homodigitally) which is connected to the closest perforant and provides safe blood flow. Koshima et al. describe the use of small lateral flaps that are based on the digital artery perforants and elevates these to the perforating branches closest to the injured area.^[29,31] Less damage is inflicted than in reverse-flow (that uses proximal phalanx dorsal skin and performs a neurovascular bundle dissection) tissue transfer.

Del Bene et al. have elevated a flap without including the palmary digital artery. That flap includes the dorsal vascular territories and their dorsal skin island. The authors asserted that the thickest perforants are placed in the distal one-third of the proximal phalanx, in the middle-third of the middle phalanx and in the DIP level. They chose the perforants that fed the flap among these. In their group of subjects, no venous problems were observed and only one patient (%8.3) presented with marginal necrosis.^[19]

Shibu et al. described taking the DIF joint dorsal skin coming as close as 4 mm to the eponychium

(over dorsal arterial branches) and turning it toward the finger tip.^[25] However, the pedicle length of these particular flaps, which were close to the injured area, were short. They required microsurgical dissection. Because the pedicle includes smaller veins, it is more susceptible to skin compression and pedicle torsion. Narrow rotation arcs are also synonymous with this procedure.^[22,25,29,31]

In the years that followed, some specialists worked on flaps close to the injured area without sacrificing the digital artery.^[22,25,29,31] They used either direct or reverse-flow flaps. Li et al., in order to avoid using the digital artery in the flap, drew a skin island over the last dorsal branch of the digital artery.^[22] Our series contained 6 MPFs that were performed this way. No loss was observed within these flaps. Kayıkçıoğlu et al. used arterialized venous flaps.^[34] In the “Boomerang” flap, the proximal phalanx dorsal skin is elevated on PDA-DMA junctions.^[33,35] Keeping donor area defects on the same finger is usually a desired situation in single finger injuries.

Lai et al. found that by using the dorsal sensory branch of the proper digital nerve in palmary losses, satisfactory results were achieved.^[2,4,5] In the group of Orhun et al., SWM was detected as 4.56 in only one patient. The other scores were more positive.^[36]

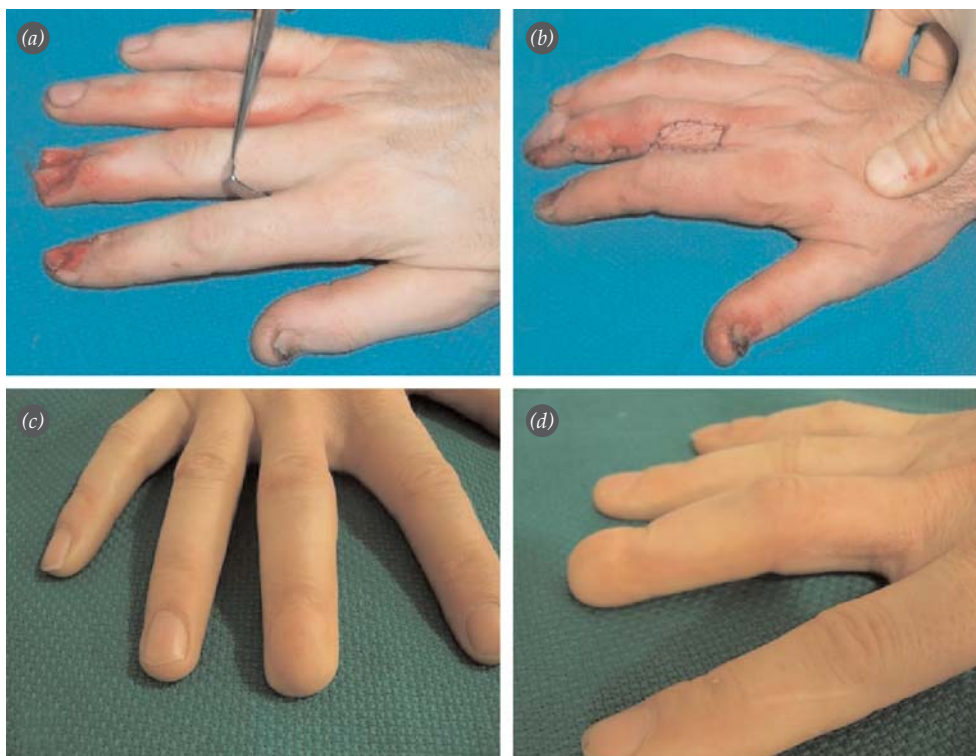


Fig. 4. (a) Dorsal injury creating sterile + germinative nail matrix loss on the third finger. (b) Soft tissue provided by a flap from the radial side. (c, d) Appearance four years after surgery. [Color figure can be viewed in the online issue, which is available at www.aott.org.tr]

Instead of reverse-flow PPF without the addition of nerve repair, Lai et al. described a PPF that included bilateral nerve repair (superficial sensory branch + dorsal sensory branch of the palmary digital nerve).^[4] The sensory values of this flap were much better (innervated PPF s-TPD=3.9 mm, non-innervated s-TPD= 6.8 mm). Lai et al. also showed that thin nerve endings from the digital nerve dorsal branch were found on the proximal phalanx dorsal skin. The branch leading to this area could not be shown in only 4% of cadavers. Generally, if the PPF is innervated, sensory results tend to be better.^[6,7,11,20,27]

Other than a few MPFs, our group did not include any sensory repair. Regardless of this fact and with only one minor exception, none of the patients had functional or sensory complaints, as confirmed by Semmes-Weinstein values (76% protective sense). Moreover, in 75% of the cases involving the second finger, the ulnar side was used for the flap and the tactile area was not involved. As mentioned above, for second or third finger pulp losses, direct-flow neurovascular tissue transplantation was our first choice.

s-TPD values within our group presented an irregular distribution in accordance with the specific literature (range: 2 to 11 mm). Even though dorsal sensory branch repair was not included in our PPFs, 95% of the patients reported satisfaction.

Vascular insufficiency within the flap and the loss as a result of venous congestion is a common problem in reverse-flow flaps. The loss of flap varies in different groups of patients at the rate of 0 to 13%.^[4-7,10,11,20,27,36]

In our series, a loss in one flap (%1.4) and superficial epidermolysis in four flaps (%5.9) were observed. The low rate of loss in our series may be related to factors, such as careful dissection, provision of blood flow to the flap before replacement, the inclusion of veins to the skin island and skin grafting over the pedicle. Del Bene et al. recommended that the reverse-flow skin island dimension be smaller than the proximal phalanx middle-third and a healthy tissue of 3-5 mm be left at the pedicle pivot point.^[19] We also recommend that the tourniquet be opened after the dissection and a wait of 10-15 min-

utes in order to fill up the vascular bed in reverse-flow flaps. Following this, the tissue can be transferred to the recipient area.

Lai et al. discussed the capillaries and the venules in the perivascular tissue.^[5] We witnessed infrequently that the flap can present with venous congestion. In direct-flow flaps, however, these kinds of problems are rare.^[16-18] One of the veins belonging to the donor flap skin can be included in the skin island and can then be connected primarily or secondarily to the local veins in the defect area. In one of our cases, a primary vein-to-vein anastomosis was performed. In cases where a venous insufficiency develops within the first 24 hours after the surgery, a secondary anastomosis can be performed on the veins within the surgical area. Overnight stays for patients who develops circulation insufficiency, following reverse-flow flaps, are not customary. However, the opinion of the surgeon determines the nature of clinical follow-up.

In conclusion, we believe that our study will be instructive for cases in which reverse-flow PPF and MPF are applicable. In long-term follow-ups, PPF and MPF have presented satisfactory results in single finger injuries where the donor site remained in the area between the fingers and healed with a single line of repair tissue. Vascular insufficiency is rarely seen in cases, where the flaps were used for the pulp and lifted through careful dissection. However, it should not be the first choice in early stages of the microsurgery learning curve. It can be safely used outside the pinch area without the inclusion of any nerves. For this area, we recommend the use of flaps that have been prepared in such a way as to include sensory elements.

Conflicts of Interest: No conflicts declared.

References

- Weeks PM, Wray RC. Management of acute hand injuries. 2nd ed. St Louis: Mosby; 1973. p. 140-3.
- Lai CS, Lin SD, Yang CC. The reverse digital artery flap for fingertip reconstruction *Ann Plast Surg* 1989;22:495-500.
- Kojima T, Tsuchida Y, Hirase Y, Endo T. Reverse vascular pedicle digital island flap. *Br J Plast Surg* 1990;43:290-5.
- Lai CS, Lin SD, Chou CK, Tsai CW. Innervated reverse digital artery flap through bilateral neurotomy for pulp defects. *Br J Plast Surg* 1993;46:483-8.
- Lai CS, Lin SD, Chou CK, Tsai CW. A versatile method for reconstruction of finger defects: reverse digital artery flap. *Br J Plast Surg* 1992;45:443-53.
- Keramidas E, Rodopoulou, Metaxotos N, Panagiotou P, Iconomou T. Reverse dorsal digital and intercommissural flaps used for digital reconstruction. *Br J Plast Surg*. 2004; 57:61-5.
- Momeni A, Zajonc H, Kalash Z, Stark B, Bannasch H. Reconstruction of distal phalangeal injuries with the reverse homodigital island flap. *Injury* 2008;39:1460-3.
- Hirase Y, Kojima T, Matsuura S. A versatile one stage neurovascular flap for fingertip reconstruction: the dorsal middle phalangeal finger flap. *Plast Reconstr Surg* 1992; 90:1009-15.
- Alagöz SA, Uysal CA, Kerem M, Şensöz Ö. Reverse homodigital artery flap coverage for bone and nail bed grafts in fingertip amputations. *Ann Plast Surg* 2006;56: 279-83.
- Nuzumlalı ME, Öztürk K, Bayrı O, Çepel S, Gürbüz C. The versatile reverse flow digital artery cross finger flap. *Tech Hand Up Extrem Surg* 2007;11:259-61.
- Han SK, Lee BI, Kim WK. The reverse digital artery island flap: clinical experience in 120 fingers. *Plast Reconstr Surg* 1998;101:1006-11.
- Niranjan NS, Armstrong JR. A Homodigital reverse pedicle island flap in soft tissue reconstruction of the finger and the thumb. *J Hand Surg Br* 1994;19:135-41.
- Takeishi M, Shinoda A, Sugiyama A, Ui K. Innervated reverse dorsal digital island flap for fingertip reconstruction. *J Hand Surg Am* 2006;31:1094-9.
- Adani R, Busa R, Scagni R, Mingione A. The heterodigital reversed flow neurovascular island flap for fingertip injuries. *J Hand Surg Br* 1999;24:431-6.
- Wilson ADH, Stone C. Reverse digital artery island flap in the elderly. *Injury* 2004;35:507-10.
- Lim GJS, Yam AKT, Lee JYL, Chuan TL. The spiral flap for fingertip resurfacing: short-term and long-term results. *J Hand Surg Am* 2008;33:340-7.
- Varitidimis SE, Dailiana H, Zibis AH, Hantes M, Bargiotas K, Malizos KN. Restoration of function and sensitivity utilising a homodigital neurovascular island flap after amputation injuries of the fingertip. *J Hand Surg Br* 2005;30:338-42.
- Adani R, Busa R, Castagnetti C, Bathia A, Caroli A. Homodigital neurovascular island flaps with direct flow vascularisation. *Ann Plast Surg* 1997;38:36-40.
- Del Bene M, Petrolati M, Raimondi P, Tremolada C, Muset A. Reverse dorsal digital island flap. *Plast Reconstr Surg* 1994;93:552-7.
- Adani R, Marcoccio I, Tarallo L, Fregni U. The reverse heterodigital neurovascular island flap for digital pulp reconstruction. *Tech Hand Up Extrem Surg* 2005;9:91-5.
- Lee YH, Baek GH, Gong HS, Lee SM, Chung MS. Innervated lateral middle phalangeal finger flap for a large pulp defect by bilateral neurotomy. *Plast Reconstr Surg* 2006;118:1185-93.
- Li YF, Cui SS. Innervated reverse island flap based on the end dorsal branch of the digital artery: Surgical technique. *J Hand Surg Am* 2005;30:1305-9.

23. Yıldırım S, Avcı G, Akan M, Aköz T. Complications of the reverse homodigital island flap in fingertip reconstruction. *Ann Plast Surg* 2002;48:586-92.
24. Beldame J, Havet E, Auckbur IA, Levebvre B, Mure JP, Duparc F. Arterial anatomical basis of the dorsal digito-metacarpal flap for long fingers. *Surg Radiol Anat* 2008;30:429-35.
25. Shibu M.M, Tarabe MA, Graham K, Dickson MG, Mahaffey PJ. Fingertip reconstruction with a dorsal island homodigital flap. *Br J Plast Surg* 1997;50:121-4.
26. Braga Silva J. Anatomic basis of dorsal finger skin cover. *Tech Hand Up Extrem Surg* 2005;9:134-41.
27. Yang D, Morris S. Reversed dorsal digital and metacarpal island flaps supplied by the dorsal cutaneous branches of the palmar digital artery. *Ann Plast Surg* 2001;46:444-9.
28. Özaksar K, Toros T, Sügün TS, Bal E, Ademoğlu Y, Kaplan İ. Reconstruction of finger pulp defects using homodigital dorsal middle phalangeal neurovascular advancement flap. *J Hand Surg Eur Vol* 2010;35:125-9.
29. Endo T, Kojima T, Hirase Y. Vascular anatomy of the finger dorsum and a new idea for coverage of the finger pulp defect that restores sensation. *J Hand Surg Am* 1992;17:927-32.
30. Strauch B, De Maura W. Arterial system of the fingers. *J Hand Surg Am* 1990;15:148-54.
31. Koshima I, Urushibara K, Fukuda N, Ohkochi M, Nagase T, Gonda K, et al. Digital artery perforator flaps for fingertip reconstructions. *Plast Reconstr Surg* 2006;118:1579-784.
32. Karamürsel S, Çelebioğlu S. Reverse flow first dorsal metacarpal artery flap for index fingertip reconstruction. *Ann Plast Surg* 2005;54:600-3.
33. Chen SL, Chou TD, Chen SG, Cheng TY, Chen TM, Wang HJ. The boomerang flap in managing injuries of the dorsum of the distal phalanx. *Plast Reconstr Surg* 2000;106:834-9.
34. Kayıkçıoğlu A, Akyürek M, Şafak T, Özkan Ö, Keçik A. Arterialised venous dorsal digital island flap for fingertip reconstruction. *Plast Reconstr Surg* 1998;102:2368-72.
35. Legaillard P, Grangier Y, Casoli V, Martin D, Baudet J. Boomerang flap. A true single- stage pedicled cross finger flap. *Ann Chir Plast Esthet* 1996;41:251-8.
36. Orhun E, Öztürk K, Nuzumlalı E, Polatkan S, Polatkan O. Parmak ucu yaralanmalarında kullandığımız ters akımlı dijital arter ada flebi ile sonuçlarımız. *Acta Orthop Traumatol Turc* 2000;34:147-51.