



## Functional results of lower extremity lengthening by motorized intramedullary nails

Hakan DİNÇYÜREK<sup>1</sup>, Mehmet KOCAOĞLU<sup>2</sup>, İ. Levent ERALP<sup>3</sup>, F. Erkal BİLEN<sup>2</sup>, Göksel DİKMEN<sup>3</sup>, İlker EREN<sup>3</sup>

<sup>1</sup>Department of Orthopedics and Traumatology, Burhan Nalbantoglu State Hospital, Nicosia, The Turkish Republic of Northern Cyprus;

<sup>2</sup>Department of Orthopedics and Traumatology, Memorial Hospital, Şişli, İstanbul, Turkey;

<sup>3</sup>Department of Orthopedics and Traumatology, Istanbul Faculty of Medicine, Istanbul University, İstanbul, Turkey

**Objective:** The aim of this study was to evaluate the outcome of patients undergoing limb lengthening using motorized intramedullary nails.

**Methods:** This study included eleven femora and 4 tibiae from 14 patients (9 male, 5 female; mean age: 26.9 years; range: 14 to 51 years) who underwent limb lengthening using motorized intramedullary femoral nails (Fitbone® TAA). Average preoperative limb shortening was 4.9 (range: 2.5 to 7.5) cm. Distraction was initiated on the seventh postoperative day. Serial radiographs and Paley's bone and functional outcome scoring systems were used to evaluate the results.

**Results:** Mean follow-up period was 33.5 (range: 7 to 88) months. Mean distraction index value was 1.2 (range: 0.7 to 2.1) days/mm and mean bone-healing index value was 43.7 (range: 13.8 to 144) days/cm. The average lengthening achieved was 51.7 (range: 25 to 75) mm. The distraction mechanism of the nail did not function properly in two patients, restricted transient knee motion was observed in four patients, and delayed consolidation was observed in four patients. Other complications included valgus deformities and superficial infections surrounding the antenna of the intramedullary nail, as well as femur fractures at the proximal end of the nail. Bone scores were excellent in 11 segments and were good in one segment. Functional scores were excellent for all 12 patients.

**Conclusion:** While usual complications related to the external fixators, such as pin-track infections and mobilization difficulties were not encountered, the development of additional complications such as dysfunction of the distraction mechanism should be monitored with the use of motorized intramedullary nails in limb lengthening.

**Key words:** Complication; distraction; external fixator; intramedullary femoral nails; limb lengthening.

Limb lengthening by distraction osteogenesis is most commonly accomplished using conventional external fixators of either the circular or monolateral type. However, lengthening procedures performed with external fixators are often associated with complications, which can occur at a frequency of 1.0 to 2.8 per patient.<sup>[1-6]</sup> Pin-track and/or deep soft tissue infections

and pain caused by Schanz pins or Kirschner wires are the most frequent adverse effects resulting in decreased postoperative patient satisfaction. Additionally, the relative muscle shortening commonly creates joint contractures. Secondary axial deformities are occasionally created during limb lengthening as a result of the external fixators, and the regenerate may easily fracture

**Correspondence:** Göksel Dikmen, MD. İstanbul Üniversitesi, İstanbul Tıp Fakültesi, Ortopedi ve Travmatoloji Anabilim Dalı, İstanbul, Turkey.

Tel: +90 212 - 414 20 00 Ext.3154 e-mail: gdkmen@yahoo.com

**Submitted:** April 28, 2011 **Accepted:** July 25, 2011

©2012 Turkish Association of Orthopaedics and Traumatology

Available online at  
www.aott.org.tr  
doi:10.3944/AOTT.2012.2671  
QR (Quick Response) Code:



following the removal of the external fixator.<sup>[1,7,8]</sup> As a result of these concomitant complications, external fixation must remain in place for a greater length of time. Furthermore, increased external fixation time results in a challenging rehabilitation period and a longer recovery period before a return to daily activities.

A number of new techniques have recently been developed to decrease external fixation time. In 1956, Bost and Larsen combined the use of intramedullary nails with the use of temporary external fixators to overcome malalignment difficulties following external fixator application.<sup>[9]</sup> Lengthening over an intramedullary nail, as described by Paley et al. in 1997, provides a significantly decreased external fixation time and can reduce the infection rate for femoral lengthening cases.<sup>[10]</sup> This combination technique, known as the combined technique, is also used for the treatment of non-unions, infected non-unions, defected non-unions, and other indications to decrease the external fixation times and the infection rate.<sup>[11-14]</sup> As a result, patient satisfaction has increased and full range of motion (ROM) of the adjacent joints can be obtained much earlier.

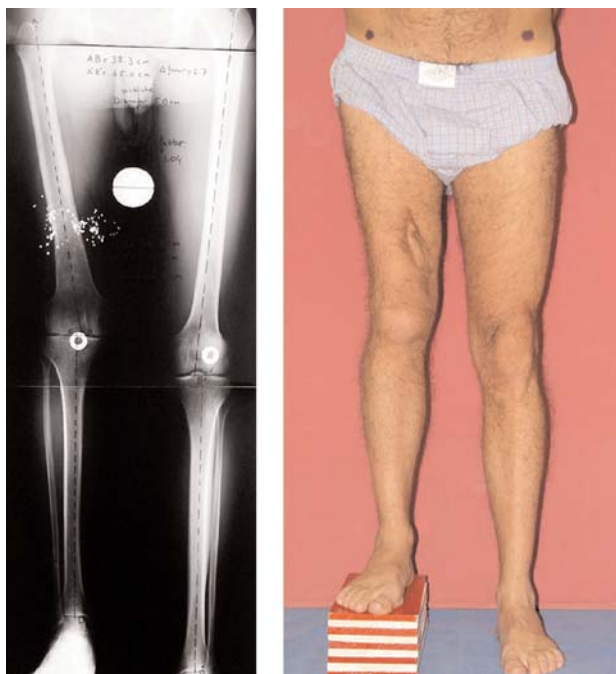Subsequent to the development of these combination techniques, newer devices have been designed to function without the need for external fixators. Betz et al. developed an intramedullary lengthening device

with a subcutaneous receiver.<sup>[15]</sup> Baumgart et al. described a series of 12 patients who underwent lengthening with such an intramedullary device without any major problems.<sup>[16]</sup> Krieg et al. reported positive results with good patient compliance and low infection rates in his case series of 8 adolescents who were given a motorized intramedullary device.<sup>[17]</sup> A study by Kenaway et al. reported a series of 57 patients who were given an intramedullary skeletal kinetic distractor (ISKD) device.<sup>[18]</sup> Currently, however, there is insufficient evidence to recommend the use of motorized intramedullary devices.

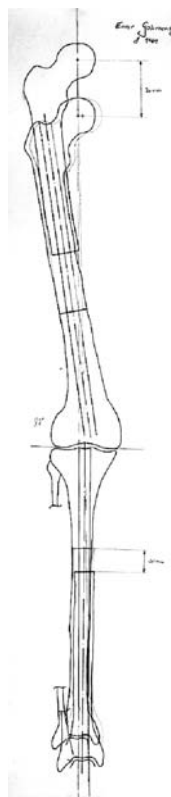
Our aim was to report results of the use of a motorized intramedullary device to lengthen the femur and/or tibia in regards to lengthening times, bone healing indices, early and late complications, and functional results.

## Patients and methods

This study included 14 patients (9 male, 5 female; mean age: 26.9 years; range: 14 to 51 years) who underwent limb lengthening with a motorized intramedullary device (Fitbone® Telescope Active Actuator (TAA) nail; Wittenstein intens GmbH, Igersheim, Germany) between 2003 and 2010 at our clinic. Eleven femora and 4 tibiae were lengthened (Figs. 1-5), and the mean pre-



**Fig. 1.** 39-year-old male patient with an aggregate of 9.4 cm shortening of the femur and tibia, following a gunshot injury. (Patient no: 2, Table 1). [Color figure can be viewed in the online issue, which is available at [www.aott.org.tr](http://www.aott.org.tr)]

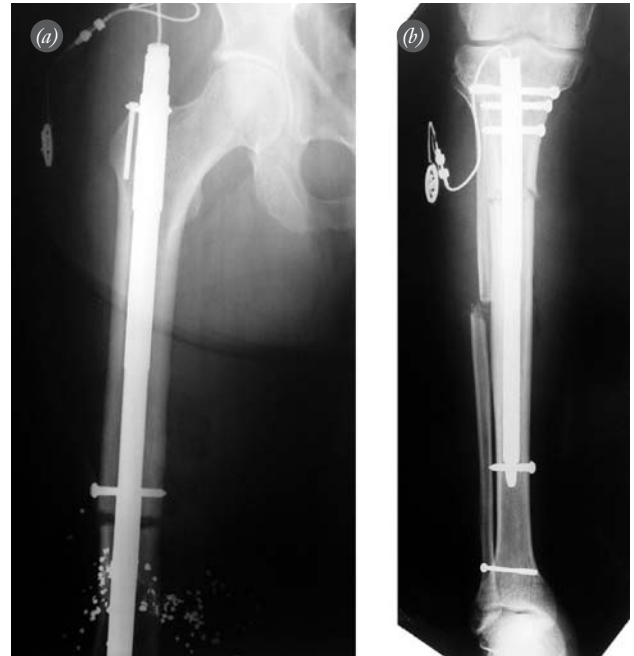

**Fig. 2.** Planning and postoperative estimate of the lengthening schematized preoperatively.

operative limb shortening was 4.9 (range: 2.5 to 7.5) cm. The patient group consisted of 5 cases with poliomyelitis sequelae, 2 with hemihypertrophy, 2 with epiphysitis sequelae, 2 with post-traumatic shortening, 2 with constitutional shortening, and one case with shortening as a result of a previous surgical intervention for developmental dysplasia of the hip (Table 1).

The criteria for inclusion in the study consisted of: limb shortening greater than 2.5 cm and less than 8 cm, absence of a deep soft tissue or osteomyelitis condition within last 2 years, the absence of a non-union, either longitudinal or rotational malalignment in the segment to be lengthened, the absence of metabolic bone disease, the absence of steroid or tobacco use, stability at the adjacent joints, the existence of at least 4/5 muscle power in the extremity to be lengthened, proper knee extension, and the assurance that the patient fully understood his or her role in the lengthening procedure.

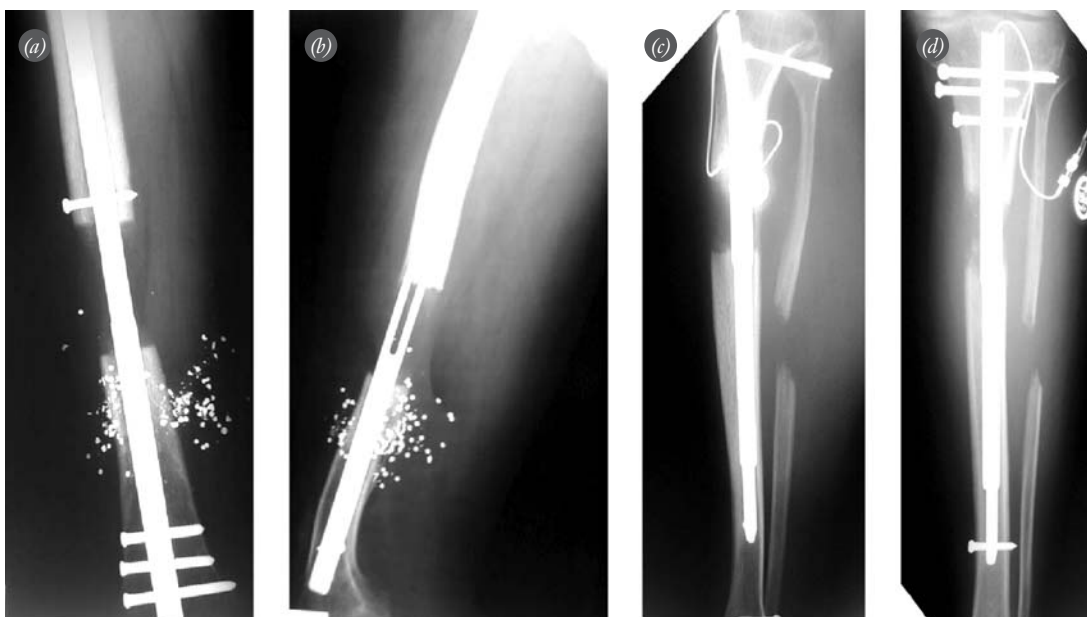
Prior to surgery, limb length was measured to establish any discrepancies, and malalignment and malorientation tests were conducted. The motorized intramedullary device (Fitbone® TAA) used was straight and, therefore, differed from the current intramedullary devices used for trauma cases.<sup>[16,19,20]</sup> As a result, preoperative planning was important. Surgical complications were classified into three groups: minor (could be remedied without the need for surgical intervention), major (could only be remedied with another surgical intervention), and true complications (sequelae). Patients were



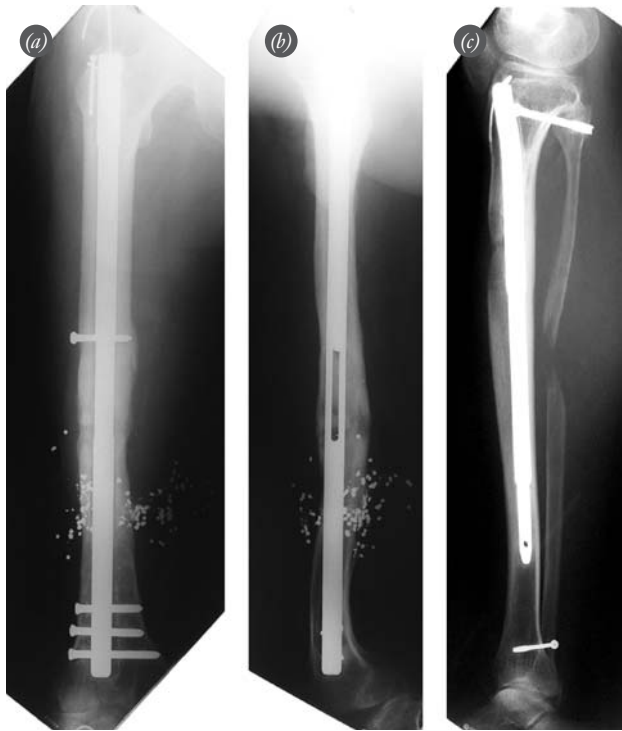
**Fig. 3.** Early period postoperative anteroposterior radiographs showing application of Fitbone® with subcutaneous antenna to (a) the femur and (b) the tibia.

postoperatively evaluated using the bone and functional scoring systems described by Paley et al.<sup>[10]</sup>

The motorized intramedullary devices (Fitbone® TAA) used for femoral and tibial lengthening differ in size.<sup>[21]</sup> The device designed for the femur is straight and made of stainless steel, and allows for a maximum dis-



**Fig. 4.** Lateral and anteroposterior radiographs of the patient's (a, b) femur and (c, d) tibia after the distraction phase.



**Fig. 5.** Patient with delayed maturation of the femur regenerate and knee motion stiffness. Anteroposterior and lateral radiographs showing complete union at (a, b) the femur and (c) the tibia, after hamstring release and grafting with posterior femoral cortex autograft.

traction of 40 to 80 mm. The tibial nail, conversely, can either be straight or angulated proximally. The motor unit is at the proximal end of the tibial nails and is connected to the subcutaneous antenna via a thin flexible wire. The main power for the motor unit is generated by an external unit and is in the form of a high frequency electrical current that passes directly through the skin. The patient can palpate the internal antenna under the skin and place the external unit over this area to transmit the signal. The motor unit transforms the signals into axial motions in one plane. The sound of the motor unit can be heard simultaneously with a stethoscope, allowing the patient to learn how the motor unit functions (Fig. 6). Lengthening was initiated at the 7th postoperative day at a rate of 0.75 mm or 1 mm per day. Next, the distraction rate was altered according to the obtained amount of distraction and the quality of the regenerate. Only one patient in our study failed to obtain the planned amount of distraction, and the distraction rate was increased for this patient.

Prior to surgery, patients were prepared on a radiolucent table. Schanz screws of 5-mm size were placed into the proximal and distal segments before osteoto-

my to prevent rotational malalignment. Next, the osteotomy was performed at the planned site at the metaphyseal arc using the multiple drill hole technique. The alignment of the frontal plane was checked with a radiolucent goniometer, any malalignment was subsequently corrected, and the malalignment test was repeated. The medullary canal was overreamed with rigid reamers 0.5 mm larger than the nails used. The motorized nail was introduced into the medullary canal slowly and gently to avoid malfunction of the mechanism and misplacement of the nail. In the tibial nails, the subcutaneous receiver antenna was located at the proximal site. In the femoral nails, the flexible wire connecting the antenna with the motor unit could be placed into a hole at the femoral cortex to prevent displacement of the antenna into the knee joint.

Mobilization using two crutches and without weight bearing was allowed until the end of the lengthening period. Upon radiological confirmation of bone healing, weight-bearing was initiated and gradually increased. Patient follow-up was conducted weekly during the lengthening period and every two weeks during the consolidation phase. Once bone healing in the three cortices was confirmed radiologically, patients were followed at monthly intervals. At each visit, hip and knee ROM, as well as any complications, were recorded. Following the distraction period, orthoroentgenograms were obtained and an alignment test was performed to check for any deformities or limb length discrepancies. Distraction indices were calculated by dividing the time of distraction in days by the amount of the distraction in millimeters (days/mm). Bone-healing indices were calculated by dividing the time spent for consolidation in days by the length of the consolidated regenerate in centimeters (days/cm).

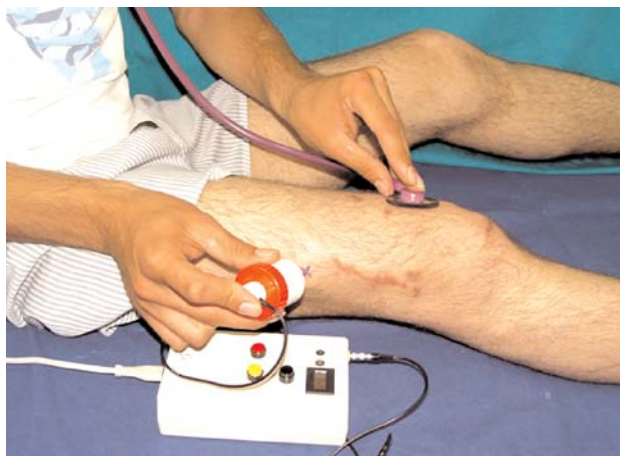## Results

Mean patient follow-up period was 33.5 (range: 7 to 88) months. Average distraction index value was 1.2 (range: 0.7 to 2.1) days/mm and the average bone-healing index value was 43.7 (range: 13.8 to 144) days/cm. The average lengthening achieved was 51.7 (range: 25 to 75) mm. Six patients exhibited minor complications and another six patients displayed major complications, although no true complications (sequelae) were encountered. Temporary knee joint stiffness was present in 3 patients during the distraction phase and completely resolved in each case after physiotherapy. Delayed consolidation was observed in three patients, each of whom ultimately exhibited consolidation without grafting. There were two major types of complica-

**Table 1.** Demographic characteristics of patients.

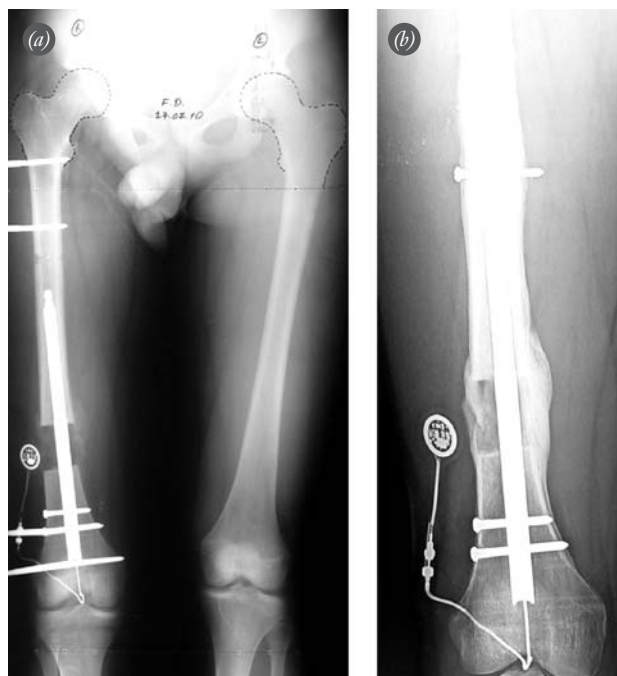Patient no/ Segment no	Gender/ age	Reasons for etiological shortening	Site/ Segment	Follow-up time (month)	Shortening (mm)	Distraction index (day/mm)	Consolidation index (day/cm)	Functional score	Bone score	Major complication
1/1	18/M	Hemihypertrophy	R femur	38	45	1.8	53.3	Excellent	Excellent	Superficial antenna site infection
2/2 and 3	39/M	Posttraumatic (Gunshot injury)	R femur/ R tibia*	88	67 / 27*	1.2 / 1*	77/144*	Excellent/ Excellent*	Excellent/ Good*	Hamstring release + grafting with femur posterior cortex autograft/Achilles release*
3/4	31/F	Poliomyelitis	R femur	86	45	1.3	53.3	Excellent	Excellent	None
4/5	45/M	Constitutional	R femur	34	40	2.1	22.5	Excellent	Excellent	None
5/6	21/F	Poliomyelitis	L tibia	34	40	1.1	73	Excellent	Excellent	None
6/7	14/F	Sequel of epiphysitis	R femur	31	30	1.1	29	Excellent	Excellent	None
7/8	21/M	Operated DHD (THA)	R femur	16	75	1.2	16	Excellent	Excellent	None
8/9	13/F	Hemihypertrophy	R femur	36	65	1.52	14.2	Excellent	Excellent	Subtrochanteric femur fracture proximal to the nail, following a fall, treated with plate fixation
9/10	23/M	Poliomyelitis	L femur	10	65	0.76	13.8	Excellent	Excellent	None
10/11	17/M	Constitutional	R femur	14	55	**	**	**	**	Fitbone® failed to provide distraction intra operatively. Lengthening over nails
11/12	16/M	Sequel of epiphysitis (Purpura fulminans)	R tibia	7	70	1.07	17.4	Excellent	Excellent	None
12/13	34/M	Poliomyelitis	R femur	7	35	1.42	25	Excellent	Excellent	None
13/14	51/M	Post-traumatic (traffic accident)	L femur	7	35	**	**	**	**	Fitbone® failed to provide distraction at postoperative 16th day. Lengthening over nails
14/15	34/F	Poliomyelitis	R tibia	7	50	0.8	30	Excellent	Excellent	None

\*Patient that received simultaneous Fitbone® application on tibia and femur. \*\*Patients excluded from clinical evaluation due to Fitbone® failure to provide distraction.



**Fig. 6.** Photo showing the patient simultaneously checking the mechanical lengthening during distraction with the help of a stethoscope. [Color figure can be viewed in the online issue, which is available at [www.aott.org.tr](http://www.aott.org.tr)]

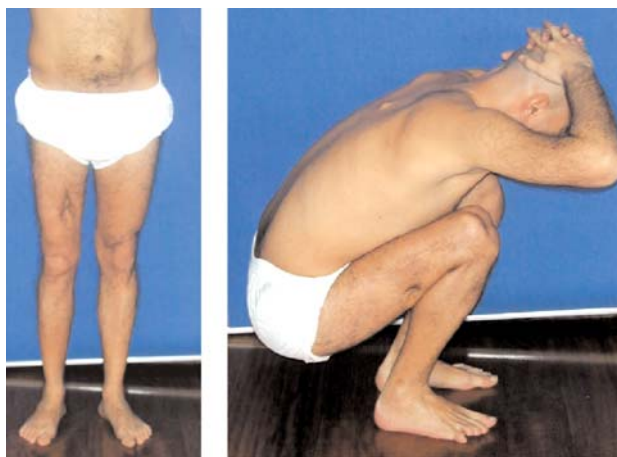tions. For two patients, the motorized intramedullary nails failed to provide distraction (one was discovered during the initial operation, and the other was discovered on the 16th postoperative day) and as a result, a monolateral, external fixator was applied for distraction (Fig. 7). Another patient developed a superficial infection 11 months after the surgery at the subcutaneous antenna site. For this patient, the antenna was removed, soft tissue debrided, and 6 weeks of culture-specific oral antibiotics were administered to eradicate the infection. Another patient developed a 20-degree loss of knee extension despite physiotherapy and underwent a hamstring release procedure to achieve subsequent full knee ROM (Fig. 8). This same patient displayed delayed consolidation of the regenerate and ultimately received an autologous graft during a hamstring release procedure. This patient's delay in consolidation was attributed to periosteal damage at the osteotomy site due to a previous trauma, which delayed weight-bearing. Another patient sustained a subtrochanteric femur fracture proximal to the nail following a fall, requiring an open reduction and plate fixation. This patient exhibited excellent bone healing at the regenerate site, as well as the subtrochanteric site. According to Paley's bone scoring system, 12 segments were excellent, and one segment was good. According to Paley's functional scoring system, each of the 12 patients was excellent. The two patients who failed to distract the nail and who were subsequently given conventional lengthening procedures were excluded from the evaluation with Paley's scoring system.



**Fig. 7.** Anteroposterior radiographs of the patient showing (a) the distraction phase following lengthening with Fitbone® and (b) union after the removal of external fixator.

## Discussion

An alternative technique to the conventional lengthening procedures uses an intramedullary nail and has recently gained popularity. This technique allows for a shorter rehabilitation period, lower complication rate and eliminates limb length discrepancies. However, the clinical and functional results of lengthening using a motorized intramedullary nail (Fitbone® TAA) have not



**Fig. 8.** The pelvic obliquity and shortening have been repaired. Knee motion stiffness, as a major complication, is also remedied with surgery. [Color figure can be viewed in the online issue, which is available at [www.aott.org.tr](http://www.aott.org.tr)]

yet been evaluated in the literature. Appropriate patient selection is required due to the complexity of the nail mechanism and its application, explaining the small number of patients in the reported case series.

The complications encountered in adult distraction osteogenesis procedures have been correlated with the amount of lengthening, the number of pins in the extremity, and the age of the patient.<sup>[1-3,21]</sup> Conventional lengthening procedures can result in serious complications in as many as rates of 24 to 119% (multiple complications on a single segment).<sup>[3,7,10,22]</sup> Persistently high complication rates have been reported when the use of conventional, external fixators was combined with the use of intramedullary nails, despite decreased external fixation time.<sup>[12,13]</sup> On the other hand, the combined technique yielded much lower complication rates in the pediatric age group.<sup>[23]</sup> These complications may also occur following the removal of the external fixator, which can lead to a loss of alignment or a fracture of the regenerate.<sup>[8,24,25]</sup> In this study, however, the combined technique was shown to prevent the loss of alignment and fracture of the regenerate, although it did not prevent infection.<sup>[10,26]</sup>

The currently used intramedullary lengthening devices use Albizzia (DePuy, Villeurbanne, France), Fitbone® TAA and ISKD® (Orthofix Inc., Lewisville, TX, USA) nails. The main difference between the Fitbone® and the other two devices is its use of a motorized lengthening unit, where the other two devices provide mechanical lengthening.<sup>[16,19,20,27-29]</sup> A second procedure may be required during the distraction period with Albizzia or ISKD® nails, as rotational correction of the nail or mobilization under general anesthesia may be warranted.<sup>[27,28]</sup> These additional procedures decrease patient comfort and increase the rate of complication. The complication rates reported for ISKD® and Albizzia nails were 11 to 47% and 20%, respectively, although those reports were based on a small number of patients.<sup>[29,30]</sup>

The largest Fitbone® case series reported consisted of 150 patients, and the complication rate was 13%.<sup>[31]</sup> In our series, there were 6 major and 6 minor complications. The minor complications were managed with conservative methods, whereas the major complications were treated with secondary surgical procedures. Additionally, 2 patients failed to obtain distraction with the intramedullary device, and these cases were then treated with conventional lengthening procedures, i.e., the distraction was obtained via monolateral external fixators. None of the patients displayed true complications (sequelae).

In the literature, the consolidation indices reported were 35.2 days/cm with Albizzia nails, 29 days/cm with ISKD® nails, and 26 to 42 days/cm with Fitbone® applications.<sup>[17,27,30,32]</sup> In comparison, the mean consolidation index in our series was 43.7 (range: 13.8 to 144) days/cm. This wide range was attributed to the delayed consolidation of one patient. In this patient (no. 2) the periosteal damage due to a previous trauma at the osteotomy site and delayed weight-bearing was considered to be the reason for the delayed consolidation. For the pediatric age group, the process of consolidation is much faster, and bone healing indices of 43.6 days/cm have been reported.<sup>[22]</sup> Our study, as well as these published data, suggest that with this method, similar bone healing indices can be obtained without the complications that are encountered with the use of conventional external fixator methods, such as secondary malalignment, fracture of the regenerate, and pin-track infections.

The accelerated physiotherapy enabled by the motorized intramedullary nails leads to early progress toward normal joint ROM. Therefore, we believe that motorized intramedullary nails may be an appropriate method for the treatment of limb-length discrepancies. Patient selection is of paramount importance for a successful outcome. The application of this method requires surgical experience and technical knowledge, and in some cases, the distraction mechanism of the nail may not function properly during surgery or during the distraction phase. At this point, the surgeon must be familiar with combined methods, such as lengthening over the nail with the use of an external fixator technique. We conclude that high degrees of patient satisfaction can be obtained using this technique when patients are first selected appropriately.

**Conflicts of Interest:** No conflicts declared.

## References

1. Paley D. Problems, obstacles, and complications of limb lengthening by the Ilizarov technique. *Clin Orthop Relat Res* 1990;(250):81-104.
2. Noonan KJ, Leyes M, Forriol F, Canadell J. Distraction osteogenesis of the lower extremity with use of monolateral external fixation. A study of two hundred and sixty-one femora and tibiae. *J Bone Joint Surg Am* 1998;80:793-806.
3. Kocaoglu M, Eralp L, Kilicoglu O, Burc H, Cakmak M. Complications encountered during lengthening over an intramedullary nail. *J Bone Joint Surg Am* 2004;86-A: 2406-11.
4. De Bastiani G, Aldegheri R, Renzi-Brivio L, Trivella G. Limb lengthening by callus distraction (callotaxis). *J Pediatr Orthop* 1987;7:129-34.
5. Faber FW, Keessen W, van Roermund PM. Complications of leg lengthening. 46 procedures in 28 patients. *Acta Orthop Scand* 1991;62:327-32.

6. Tjernström B, Olerud S, Rehnberg L. Limb lengthening by callus distraction. Complications in 53 cases operated 1980-1991. *Acta Orthop Scand* 1994;65:447-55.
7. Young N, Bell DF, Anthony A. Pediatric pain patterns during Ilizarov treatment of limb length discrepancy and angular deformity. *J Pediatr Orthop* 1994;14:352-7.
8. Simpson AH, Kenwright J. Fracture after distraction osteogenesis. *J Bone Joint Surg Br* 2000;82:659-65.
9. Bost FC, Larsen LJ. Experiences with lengthening of the femur over an intramedullary rod. *J Bone Joint Surg Am* 1956;38-A:567-84.
10. Paley D, Herzenberg JE, Paremian G, Bhav A. Femoral lengthening over an intramedullary nail. A matched-case comparison with Ilizarov femoral lengthening. *J Bone Joint Surg Am* 1997;79:1464-80.
11. Eralp L, Kocaoglu M. Distal tibial reconstruction with use of a circular external fixator and an intramedullary nail. Surgical technique. *J Bone Joint Surg Am* 2008;90 Suppl 2 Pt 2:181-94.
12. Kocaoglu M, Eralp L, Rashid HU, Sen C, Bilsel K. Reconstruction of segmental bone defects due to chronic osteomyelitis with use of an external fixator and an intramedullary nail. *J Bone Joint Surg Am* 2006;88:2137-45.
13. Tsuchiya H, Tomita K, Minematsu K, Mori Y, Asada N, Kitano S. Limb salvage using distraction osteogenesis. A classification of the technique. *J Bone Joint Surg Br* 1997;79:403-11.
14. Vidyadhara S, Rao SK. A novel approach to juxta-articular aggressive and recurrent giant cell tumours: resection arthrodesis using bone transport over an intramedullary nail. *Int Orthop* 2007;31:179-84.
15. Betz A, Baumgart R, Schweiberer L. First fully implantable intramedullary system for callus distraction--intramedullary nail with programmable drive for leg lengthening and segment displacement. Principles and initial clinical results. [Article in German] *Chirurg* 1990;61:605-9.
16. Baumgart R, Betz A, Schweiberer L. A fully implantable motorized intramedullary nail for limb lengthening and bone transport. *Clin Orthop Relat Res* 1997;(343):135-43.
17. Krieg AH, Speth BM, Foster BK. Leg lengthening with a motorized nail in adolescents : an alternative to external fixators? *Clin Orthop Relat Res* 2008;466:189-97.
18. Kenaway M, Krettek C, Liodakis E, Wiebking U, Hankemeier S. Leg lengthening using intramedullary skeletal kinetic distractor: results of 57 consecutive applications. *Injury* 2011;42:150-5.
19. Baumgart R, Bürklein D, Hinterwimmer S, Thaller P, Mutschler W. The management of leg-length discrepancy in Ollier's disease with a fully implantable lengthening nail. *J Bone Joint Surg Br* 2005;87:1000-4.
20. Baumgart R, Krammer M, Winkler A, Hinterwimmer S, Muensterer O, Mutschler W. Reduction of high dislocation of the hip using a distraction nail before arthroplasty. *J Bone Joint Surg Br* 2005;87:565-7.
21. Singh S, Lahiri A, Iqbal M. The results of limb lengthening by callus distraction using an extending intramedullary nail (Fitbone) in non-traumatic disorders. *J Bone Joint Surg Br* 2006;88:938-42.
22. Donnan LT, Saleh M, Rigby AS. Acute correction of lower limb deformity and simultaneous lengthening with a monolateral fixator. *J Bone Joint Surg Br* 2003;85:254-60.
23. Saraph V, Roposch A, Zwick EB, Linhart WE. Tibial lengthening over nails in children using modified Ender nails: preliminary results of a new treatment. *J Pediatr Orthop B* 2004;13:383-8.
24. Leyes M, Noonan KJ, Forriol F, Cañadell J. Statistical analysis of axial deformity during distraction osteogenesis of the tibia. *J Pediatr Orthop* 1998;18:190-7.
25. Simpson AH, Cole AS, Kenwright J. Leg lengthening over an intramedullary nail. *J Bone Joint Surg Br* 1999;81:1041-5.
26. Kocaoglu M, Bilen FE, Sen C, Eralp L, Balci HI. Combined technique for the correction of lower-limb deformities resulting from metabolic bone disease. *J Bone Joint Surg Br* 2011;93:52-6.
27. García-Cimbrelo E, Curto de la Mano A, García-Rey E, Cordero J, Marti-Ciruelos R. The intramedullary elongation nail for femoral lengthening. *J Bone Joint Surg Br* 2002;84:971-7.
28. Guichet JM, Deromedis B, Donnan LT, Peretti G, Lascombes P, Bado F. Gradual femoral lengthening with the Albizzia intramedullary nail. *J Bone Joint Surg Am* 2003;85-A:838-48.
29. Hankemeier S, Gössling T, Pape HC, Wiebking U, Krettek C. Limb lengthening with the Intramedullary Skeletal Kinetic Distractor (ISKD). *Oper Orthop Traumatol* 2005;17:79-101.
30. Leidinger B, Winkelmann W, Roedel R. Limb lengthening with a fully implantable mechanical distraction intramedullary nail. [Article in German] *Z Orthop Ihre Grenzgeb* 2006;144:419-26.
31. Baumgart R, Hinterwimmer S, Krammer M, Hierl T, Mutschler W. A fully implantable, programmable distraction nail (Fitbone) - new perspectives for corrective and reconstructive limb survey. In: Leung KS, Taglang G, Schnettler R, editors. *Practice of intramedullary locked nails. New developments in techniques and applications*. Heidelberg: Springer; 2006. p. 189-190.
32. Hankemeier S, Pape HC, Gosling T, Hufner T, Richter M, Krettek C. Improved comfort in lower limb lengthening with the intramedullary skeletal kinetic distractor. Principles and preliminary clinical experiences. *Arch Orthop Trauma Surg* 2004;124:129-33.