



Accessory tendon slip arising from the extensor carpi ulnaris and its importance for wrist pain

Yelda PINAR, Figen GÖVSA, Okan BİLGE, Servet ÇELİK

Department of Anatomy, Faculty of Medicine, Ege University, İzmir, Turkey

Objective: The anatomical variations of the extensor carpi ulnaris (ECU) muscle can cause a functional impairment of the wrist and the little finger. The aim of this study was to determine the number, thickness and type of accessory tendon arising from the ECU.

Methods: The presence of an accessory tendinous slip from the ECU muscle was examined in terms of gross appearance, size, shape, thickness, location and distribution in 54 cadaveric forearms.

Results: The accessory slips arising from the ECU muscle were observed in three specimens (5.6%) (two left, one right). These slips ran to the ulnar side of the extensor digiti minimi tendon, originated from the head of the ECU, and ended on the extensor apparatus of the fifth finger. The mean width of the tendinous slips was 1.4 ± 0.01 mm.

Conclusion: This anatomic variation of the ECU should be considered in diagnostic and surgical procedures involving the dorsum of the hand. Its clinical importance in the treatment of tenosynovitis and subluxation of joints is also stressed.

Key words: Accessory tendon slip; elbow; extensor carpi ulnaris; hand.

Classically, the fibers of the extensor carpi ulnaris (ECU) muscle continue with a tendon above the wrist. The tendon passes behind the lower end of the ulna in an osteofibrous sheath which runs through an osseous groove between the head of the ulna and its articular process.^[1-3] The tendon then inserts onto the medial process of the 5th metacarpal and lies in the 6th compartment formed by duplication of the antebrachial fascia inserted onto the osseous groove.^[4] The extensor retinaculum passes above the five dorsal compartments and the ECU tendon like a bridge. Allowing both pronation and supination, the retinaculum inserts onto the triquetrum and pisiform bones but not to the inferior ulna.^[1,5,6] A fascial sling, the linea jugata, prevents

ECU tendon subluxations during full supination. As the retinaculum prevents subluxation the tendon is in full pronation. In supination, the ECU is stable in the 6th compartment.

These anatomical features play an important role in maintaining ECU stability in the osteofibrous groove. On the other hand, these structures restrict ECU tendon movement and produce stress during pronation and supination of the wrist.^[1,5,6] During pronation, the ECU tendon rests on the medial side of the ulnar head and stabilizes the wrist. When the forearm is supinated, the ECU tendon is exposed to maximal traction. These changes in the anatomical position explain the onset of traumatic injury to the ECU retinaculum,

Correspondence: Yelda Pinar, MD. Ege Üniversitesi Tıp Fakültesi, Anatomi Anabilim Dalı, 35100, İzmir, Turkey.

Tel: +90 232 - 390 39 87 Ext. 3366 e-mail: yeldapinar@gmail.com

Submitted: April 28, 2010 **Accepted:** January 26, 2011

©2012 Turkish Association of Orthopaedics and Traumatology

Available online at
www.aott.org.tr
doi:10.3944/AOTT.2012.2471
QR (Quick Response) Code:



especially in tennis and golf players who constantly change the angle of their wrists.^[7-9] As indicated above, it is evident that once the osteofibrous sheath ruptures or is detached from the ulna, the ECU tendon can subluxate or dislocate within and slide under the intact dorsal retinaculum.^[1,3,7,10-12]

The anatomic variations and prevalence of the extensor muscle tendons have been documented in various clinical and anatomical studies.^[13-17] Nevertheless, only a few of these have examined an accessory tendon arising from the ECU in detail. Anomalous tendon slips are possible predisposing factors in ECU problems of the wrist.^[11] Therefore, we studied the arrangements of the accessory tendon(s) of the ECU on the dorsum of the hand. An extra extensor tendon to the fingers might cause persistence of the extensor carpi ulnaris syndrome. The anatomic variations can facilitate dislocation and tendinopathy of the ECU and can also cause functional impairment of the wrist and the little finger.^[1,18,19]

The aim of this study was to determine the number, thickness and type of accessory tendon arising from the ECU as it may be used as a provocative tissue in the treatment of tenosynovitis and subluxation of the joint.

Materials and methods

Randomly selected adult upper extremities (left and right sides of 24 cadavers and 6 isolated right specimens) of fifty-four Anatolian male cadaver specimens, aged between 38 and 87, were preserved in 10% formalin and studied. The wrists and hands of the cadavers were carefully examined to be sure that they showed no signs of trauma, deformities and significant volume loss. The hands were dissected from the level of the third distal end of the forearm to the middle

phalanx of the fingers. After the removal of the skin and a careful dissection of the superficial fascia on the back of each hand, the extensor retinaculum was divided longitudinally to expose the ECU tendons. Microdissection was performed under a loop at original magnification (3.5x to 6x). Specimens were examined for the presence of accessory slip arising from the ECU tendon as well as gross appearance, size, shape, thickness, location and distribution in the neutral position of the dorsum of the hand. The slips were classified into types A, B, and C depending on their anatomical analysis by Nakashima^[1] in 1993. Allende and Le Viet's tendon type classification was also utilized.^[11] Measurements for this study were recorded by a digital ruler micrometer caliper of 0.01 mm. The Mann-Whitney U test was used for statistical comparison of the values obtained from the right and left side of the slips. P values of <0.05 was considered to be significant. The dissection was approved by a suitably constituted ethics committee of the institution within which the work was undertaken, and the study conforms to the Declaration of Helsinki, 1964.

Results

Three (two left, one right) (5.6%) accessory tendinous slips arising from the ECU were observed. These tendinous slips ran to the ulnar side of the extensor digiti minimi (DM) and ended on the extensor apparatus of the 5th finger. The mean width of the tendinous slips was 1.4 ± 0.01 mm. All accessory slips arose from the ECU with an insertion in the 5th metacarpal bone (Fig. 1).

Accessory slips were classified into types A, B, C according to their insertion point on the 5th metacarpal bone by Nakashima in 1993.^[1] Type A slips arise from the ECU with an insertion on the base of the 5th

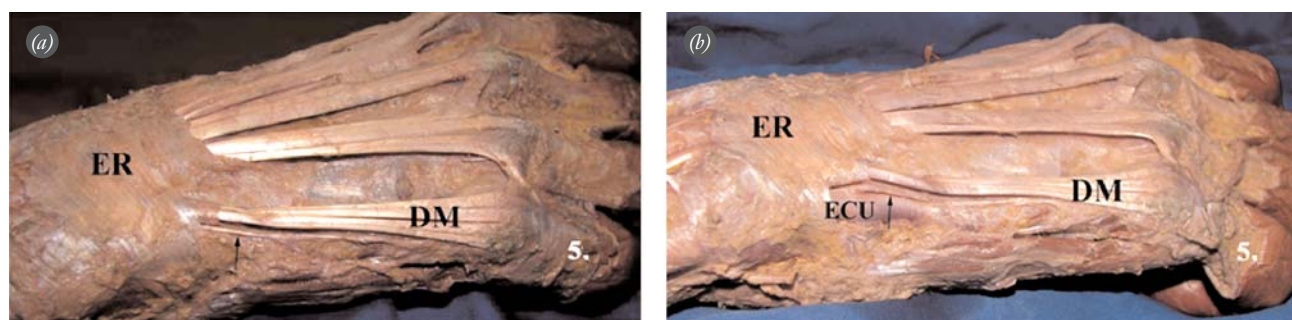


Fig. 1. (a, b) The accessory tendinous slip is shown with an arrow. (b) It is seen that the slip arises from the extensor carpi ulnaris tendon after the sixth compartment was dissected. ER: Extensor retinaculum, DM: extensor digiti minimi tendon, ECU: extensor carpi ulnaris tendon, 5th: fifth digit, arrow: accessory tendinous slip. [Color figure can be viewed in the online issue, which is available at www.aott.org.tr]

metacarpal bone. Type B arose from the ECU with an insertion on the midsection of the 5th metacarpal bone and Type C had an insertion on the head of the 5th metacarpal bone. According to this classification, all cases in this study were Type C.

Discussion

Tendons attached to the 5th finger have previously been recognized in clinical and anatomical studies in terms of their variation, arrangement and incidence. Nevertheless, during dissection, it has been observed that the pattern of the extensor tendons of the hand was not as simple as previously reported by many authors.^[13,17,20-22] The prevalence of an accessory tendinous slip arising from the ECU was given as 10 to 34% in literature.^[1,20] However, most of research reported has been carried out on the Japanese population, with only one study on a European population.^[20] The possible clinical significance of an anomalous ECU tendon slip was first described by Barfred and Adamsen^[10] in 1986. They suggested that an accessory tendinous slip arising from the ECU muscle may cause functional impairment of the wrist and little finger. Pulling of this slip facilitates extension of the little finger. The existence of an anomalous tendon slip was considered to make medical treatment less effective.

In a 2005 study on 27 surgically treated patients with ECU tendon lesions, Allende and Le Viet^[11] described two patterns of anomalous tendon slips between the ECU and the DM found in 7 patients. In the first type, the tendon began proximal to the ECU osteofibrous sheath, passed under it and perforated the wall between the 5th and the 6th compartments to join the DM. In the second type, the tendon slip began under the ECU osteofibrous sheath, perforated the wall between the sixth and fifth compartments and joined the ulnar border of the DM tendon (14.8%). Our results were compatible with Allende and Le Viet's second pattern although we observed this pattern in only 5.6% of patients (Table 1).

Nakashima^[1] observed and classified 82 accessory tendon slips arising from the ECU muscle among 240 upper limbs (34.2%). Classification was made into three types according to the insertion point of the main tendon to the 5th metacarpal bone on; the base (Type A, 29.6%), the mid-portion (Type B, 2.5%), or the head (Type C, 1.7%). The accessory tendinous slip patterns in our study were similar to Type C (Table 1).

The average width of the slips was found to be 1.53 ± 0.37 mm by Nakashima^[1] and 1 mm by Barfred

Table 1. The prevalence of an accessory tendinous slip arising from the ECU tendon.

	Type A (%)	Type B (%)	Type C (%)
Nakashima ^[1]	29.5	2.5	1.7
Allende and Le Viet ^[11]	-	-	14.8
Pinar et al.	-	-	5.6

Table 2. The average width of the accessory tendinous slip arising from the ECU tendon.

	Width (mm)
Nakashima ^[1]	1.53 ± 0.37
Barfred and Adamsen ^[10]	1
Pinar et al.	1.4 ± 0.01

and Adamsen.^[10] The average width in our study was 1.4 ± 0.01 mm (Table 2).

Type C accessory slips have major clinical significance because this type may weaken the function of the wrist and little finger. Particularly, supination of the wrist may be blocked. The pain felt during supination and pronation on the ulnar side of the hand can be an indication of an accessory tendinous slip. Additionally, this tendinous slip can be used as a tendon graft in hand surgery and may be preferred for the repair of tendon deficit in the distal and proximal interphalangeal joint.^[15,23]

In this study, results demonstrated that the accessory slips arise from the ECU with an insertion on the 5th metacarpal bone. Additional studies into the presence of accessory tendon slips arising from the ECU in more populations are necessary.

In conclusion, anatomical variations of the ECU may affect diagnostic and surgical procedures involving the dorsum of the hand, especially in the surgical treatment indicated in ECU tenosynovitis or tendinopathy. During surgical treatment of the ECU the surgeon must be aware of accessory tendinous slips and are recommended to avoid excising the accessory tendinous slips in order to prevent postoperative complications and complaints.^[11,15,19] It should be considered that the accessory slip may cause the persistence of extensor carpi ulnaris lesions, and its removal may decrease the risk of recurrence.

Conflicts of Interest: No conflicts declared.

References

1. Nakashima T. An accessory extensor digiti minimi arising from extensor carpi ulnaris. *J Anat* 1993;182(Pt 1):109-12.
2. Thorne CH, Beasley RW, Aston SJ, Bartlett SP, Gurtner GC, Spear SL (eds). *Grabb and Smith's plastic surgery*. 6th edition. Philadelphia: Lippincott, Williams&Wilkins; 2007: 847-55.
3. Standring S (ed). *Gray's anatomy*. 40th edition. Philadelphia: Churchill Livingstone; 2008:850.
4. Tang JB, Ryu J, Kish V. The triangular fibrocartilage complex: an important component of the pulley for the extensor wrist extensor. *J Hand Surg Am* 1998;23:986-91.
5. Kiyono Y, Nakatsuchi Y, Saitoh S. Ulnar-styloid nonunion and partial rupture of extensor carpi ulnaris tendon: two case reports and review of the literature. *J Orthop Trauma* 2002; 16:674-7.
6. Jupiter JB. Tendon stabilization of the distal ulna. *J Hand Surg Am* 2008;33:1196-200.
7. Montalvan B, Parier J, Brasseur JL, Le Viet D, Drape JL. Extensor carpi ulnaris injuries in tennis players: a study of 28 cases. *Br J Sports Med* 2006;40:424-9.
8. MacLennan AJ, Nemechek NM, Waitayawinyu T, Trumble TE. Diagnosis and anatomic reconstruction of extensor carpi ulnaris subluxation. *J Hand Surg Am* 2008;33(1):59-64. Comment in: *J Hand Surg Am* 2008;33:1682-3.
9. Tagliafico AS, Ameri P, Michaud J, Derchi LE, Sormani MP, Martinoli C. Wrist injuries in nonprofessional tennis players: relationships with different grips. *Am J Sports Med* 2009;37:760-7.
10. Barfred T, Adamsen S. Duplication of the extensor carpi ulnaris tendon. *J Hand Surg Am* 1986;11:423-5.
11. Allende C, Le Viet D. Extensor carpi ulnaris problems at the wrist – classification, surgical treatment and results. *J Hand Surg Br* 2005;30:265-72.
12. Egi T, Inui K, Koike T, Goto H, Takaoka K, Kazuki K. Volar dislocation of the extensor carpi ulnaris tendon on magnetic resonance imaging is associated with extensor digitorum communis tendon rupture in rheumatoid wrist. *J Hand Surg Am* 2006;31:1454-60.
13. Gonzalez MH, Gray T, Ortinau E, Weinzweig N. The extensor tendons to the little finger: an anatomic study. *J Hand Surg Am* 1995;20:844-7.
14. Tan ST, Smith PJ. Anomalous extensor muscles of the hand: a review. *J Hand Surg Am* 1999;24:449-55.
15. Zilber S, Oberlin C. Anatomical variations of the extensor tendons to the fingers over the dorsum of the hand: a study of 50 hands and a review of the literature. *Plast Reconstr Surg* 2004;113:214-21.
16. Tanaka T, Moran SL, Zhao C, Zobitz ME, An KN, Amadio PC. Anatomic variation of the 5th extensor tendon compartment and extensor digiti minimi tendon. *Clin Anat* 2007;20:677-82.
17. Celik S, Bilge O, Pinar Y, Govsa F. The anatomical variations of the extensor tendons to the dorsum of the hand. *Clin Anat* 2008;21:652-9.
18. Spinner M, Kaplan EB. Extensor carpi ulnaris. Its relationship to the stability of the distal radio-ulnar joint. *Clin Orthop Relat Res* 1970;(68):124-9.
19. Carneiro RS, Fontana R, Mazzer R. Ulnar wrist pain in athletes caused by erosion of the floor of the sixth dorsal compartment: a case series. *Am J Sports Med* 2005;33:1910-3.
20. Mestdagh H, Bailleul JP, Vilette B, Bocquet F, Depreux R. Organization of the extensor complex of the digits. *Anat Clin* 1985;7:49-53.
21. Godwin Y, Ellis H. Distribution of the extensor tendons on the dorsum of the hand. *Clin Anat* 1992;5:394-403.
22. von Schroeder HP, Botte MJ. Anatomy of the extensor tendons of the fingers: variations and multiplicity. *J Hand Surg Am* 1995;20:27-34.
23. Kayalar M, Bal E, Toros T, Süğün T, Keleşoğlu B, Kaplan I. The results of treatment for isolated zone 3 extensor tendon injuries. *Acta Orthop Traumatol Turc* 2009;43:309-16.