



Effect of platelet-rich plasma on tendon-to-bone healing after rotator cuff repair in rats: an in vivo experimental study

Onur HAPA¹, Hüsamettin ÇAKICI², Aysel KÜKNER³, Hayati AYGÜN⁴, Nazlı SARKALKAN⁵, Gökhan BAYSAL⁵

¹Department of Orthopedics and Traumatology, Faculty of Medicine, Dokuz Eylül University, İzmir, Turkey;

²Department of Orthopedics and Traumatology, Faculty of Medicine, Abant İzzet Baysal University, Bolu, Turkey;

³Department of Histology and Embryology, Faculty of Medicine, Abant İzzet Baysal University, Bolu, Turkey;

⁴Department of Orthopedics and Traumatology, Faculty of Medicine, Kafkas University, Kars, Turkey;

⁵Department of Mechanical Engineering, Faculty of Mechanical Engineering, İstanbul Technical University, İstanbul, Turkey

Objective: The purpose of this experimental study was to analyze the effects of local autologous platelet-rich plasma (PRP) injection on tendon-to-bone healing in a rotator cuff repair model in rats.

Methods: Rotator cuff injury was created in 68 left shoulders of rats. PRP was obtained from the blood of an additional 15 rats. The 68 rats were divided into 4 groups with 17 rats in each group; PRP group (Week 2), control group (Week 2), PRP group (Week 4), and control group (Week 4). Platelet-rich plasma or saline was injected to the repair area intraoperatively. Rats were sacrificed 2 and 4 weeks after the surgery. Histological analysis using a semiquantitative scoring was performed on 7 rats per group. Tendon integrity and increases in vascularity and inflammatory cells and the degree of new bone formation were evaluated and compared between the groups. The remaining tendons (n=10) were mechanically tested.

Results: Degree of inflammation and vascularity were less in the study group at both time intervals (p<0.05). Tendon continuity was better in the study group at 2 weeks (p<0.05). Obvious new bone formation was detected in the control group at 4 weeks (p<0.05). Biomechanically, platelet-rich plasma-treated specimens were stronger at 2 weeks (p<0.05).

Conclusion: Local autologous PRP injection may have beneficial effects on initial rotator cuff tendon-to-bone healing and enhance initial tendon-to-bone healing remodeling. This may represent a clinically important improvement in rotator cuff repair.

Key words: Platelet-rich plasma; rotator cuff tendon; tendon-to-bone healing.

Despite advances in surgical technique, a high incidence of rotator cuff tears regardless of the repair occur.^[1] Rotator cuff repair requires attachment of the tendon to the bone. After repair, fibrovascular interface tissue forms between the tendon and the bone with later establishment of collagen fiber continuity between the two.

Healing of the tendon to the bone is a gradual process with the tendon-bone attachment site being the weakest link.^[2] Most studies focused on the methods to improve the initial strength between the tendon and the bone with attention to fixation device type, suture pattern or suture material with little emphasis on methods to

Correspondence: Onur Hapa, MD. Dokuz Eylül Üniversitesi, Ortopedi ve Travmatoloji Anabilim Dalı, İzmir, Turkey.

Tel: +90 505 - 776 94 31 e-mail: onurhapa@gmail.com

Submitted: April 5, 2011 **Accepted:** November 29, 2011

©2012 Turkish Association of Orthopaedics and Traumatology

Available online at
www.aott.org.tr
doi:10.3944/AOTT.2012.2664
QR (Quick Response) Code:



improve the biology of tendon-bone healing.^[3] Tissue failure occurs before anchor, suture or knot failure.^[4] Delivery of growth factors or cells to augment tendon-to-bone healing is an attractive option to optimizing rotator cuff healing.^[4]

Platelet-rich plasma (PRP) is a rich source of autologous growth factors, with a platelet concentration above the baseline (whole blood) and including platelet-derived growth factor (PDGF), transforming growth factor (TGF- β), fibroblastic growth factor (FGF), insulin-like growth factor (IGF), vascular endothelial growth factor (VEGF), and epithelial cell growth factor (EGF).^[5] These growth factors are secreted from the α -granules upon platelet activation and delivered to the injury site to facilitate healing.^[6-8] These have roles at various stages of the ligament and tendon healing.^[7]

Autogenously used PRP poses no risk of transmissible disease and provides a simple, low-cost, minimally-invasive way to apply many growth factors. It has been used in various fields of medicine including orthopaedics and sports medicine.^[9] Different results have been reported for various clinical and animal studies for fracture healing, nonunion treatment, Achilles tendon repair, various chronic tendinous elbow, patellar tendon treatment, cartilage healing, muscle strain and rotator cuff repair.^[8-15] Castricini et al. failed to show the beneficial effects of PRP on small to medium sized rotator cuff repairs in their clinical prospective study.^[14] Barber et al. reported a higher percentage of healing with autologous local application of PRP on postoperative MRI of the rotator cuff repairs.^[15] Various growth factors or growth factor mixtures have been reported to influence early rotator cuff tendon-to-bone healing in animal models, enhancing both histological and biomechanical parameters.^[16-18] However, there has been no experimental study reporting the effect of PRP on rotator cuff tendon healing.

The aim of this study was to demonstrate the effect of local autogenous PRP on healing of the rotator cuff tendon to the bone using a previously described rat rotator cuff injury model.^[19] We hypothesized that PRP will enhance the histological score for rotator cuff tendon healing and increase the strength of the repaired tendon-bone unit postoperatively.

Materials and methods

Eighty-three adult male Sprague Dawley rats with a mean body weight of 324 (range: 300 to 360) grams were used. The study was approved by institutional animal board and ethics committee of Abant İzzet Baysal University. Three rats were housed per cage at 21 °C in a 12-hour light and dark cycle and given food

and water ad libitum. Sixty-eight rats were included in the study and underwent left shoulder rotator cuff repair surgery. The 15 remaining rats were used to collect blood and produce PRP.

The rats were divided into two groups; the PRP group (n: 34) and the control group (n: 34). The left shoulders of the rats were operated under ketamine and xylazine anesthesia using the sterile technique. After the anterolateral incision, the deltoid and omovertebral muscles were retracted. The acromioclavicular arch was retracted and complete exposure of the rotator cuff tendon was achieved. The supraspinatus tendon was detached from the anterior part with a length and width of 2 mm constituting approximately half of the tendon. The remaining fibrocartilaginous tissue was excised using curettage until bleeding bone. A 1.5-mm wide, 2-mm deep hole was drilled. 150 μ l of PRP was applied to the hole. The raised flap was brought closer to the remaining rotator cuff tendon and sutured with two side-to-side 4.0 Vicryl sutures (Fig. 1). An additional 150 μ l of PRP was injected to the repair site. In the control group, the same amount of saline injection was applied. The deltoid and trapezius muscles were sutured and layers were closed in an anatomical manner. There was no postoperative immobilization and rats were allowed to move freely.

Rats were divided into 4 groups with 17 rats in each group; PRP group (Week 2), control group (Week 2), PRP group (Week 4) and control group (Week 4). At Week 2, rats in both the PRP and control Week 2 groups (34 rats in total) were euthanized. Seven specimens from each group underwent histological analysis and 10 specimens from each group were used for biomechanical analysis. The remaining two groups (34 rats) were sacrificed at Week 4. Seven specimens from each group underwent histological analysis and 10 specimens from each group were used for biomechanical analysis.

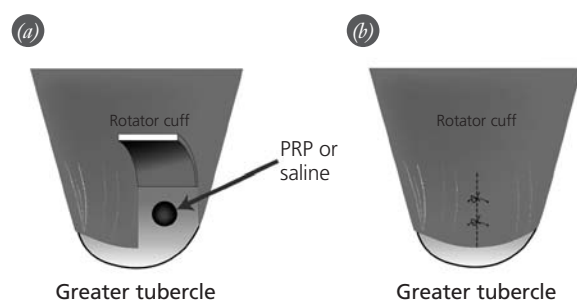


Fig. 1. Schematic drawing of the surgical procedure (PRP: platelet-rich plasma). [Color figure can be viewed in the online issue, which is available at www.aott.org.tr]

Whole blood was collected from 15 male Sprague Dawley rats. The rats were anesthetized with an intraperitoneal injection of ketamine (80 mg/kg) and xylazine (5 mg/kg). Approximately 5 ml of whole blood was collected from the major vessels of each rat. Rats were then killed with an intracardiac injection of overdose of pentobarbital. The anticoagulated blood was then centrifuged at 220 x g for 20 min. Supernatant was again centrifuged at 480 x g for 20 min to form a pellet of rat platelets.^[20] Platelet numbers were counted in the first specimen and found to be 13.8×10^9 platelets/L.^[20]

Histological analysis was performed by an investigator (A.K., Histology and Embryology Specialist) blinded to the study groups. Tissues were fixed with 10% formalin and decalcified in EDTA. Decalcified tissue was embedded in paraffin, and two longitudinal serial sections, each 5- μ m thick, were taken from the injured site 'core area' of the rotator cuff tendon. Hematoxylin and eosin (H&E) staining was performed. Tendon-bone healing area was evaluated for inflammatory cells, tendon continuity, vascularity, the amount of ossification and new bone formation. These components were evaluated and scored between 0 and 3 (0: no increase or change, 1: mild increase or change, 2: moderate increase or change, 3: severe increase or change), using a modified Ide et al.^[19] method.

All specimens harvested from rats (10 for each group) were frozen immediately at -20 °C. Before testing, specimens were thawed. The supraspinatus muscle originating from the scapula and inserting to the greater tubercle on the humerus was cleared from adhesions, capsular attachments, and other soft tissue attachments until only the supraspinatus tendon held the scapula and humerus together. The tendon was trimmed down to a 2x1 mm cross-section area containing the repaired site of the tendon using a no. 11 blade to standardize the amount of tendon tested. The scapula and humerus were mounted with special clamping jaws on the testing machine (MTS Bionix II Universal Testing Machine; MTS Systems Corp., Eden Prairie, MN, USA). The subsequent pullout force test was per-



Fig. 2. Mechanical testing of the specimen. Tendon lengthening just before the rupture. [Color figure can be viewed in the online issue, which is available at www.aott.org.tr]

formed at a velocity of 3 mm/min. Load to failure (Newton [N]) through the mid-substance of the tendon was determined as the ultimate load at the load-elongation curve (Fig. 2).

The Mann-Whitney U test was used to compare histological scores between groups and load to failure values of the groups at two different time periods (Week 2 and Week 4). The Wilcoxon signed-rank test was used to compare different time load to failure values of the groups (control group (Week 2) and control group (Week 4), the same for study groups). P values less than 0.05 were considered significant. Data are presented as mean \pm SD.

Results

There were no postoperative complications. All rotator cuff repairs were found to be grossly intact, macroscopically bridged at the time of sacrifice. No thinning of the repair site was observed.

Histological scores are summarized at Table 1. At Week 2, control group tendon-bone area was deterior-

Table 1. Histological scores for the groups.

(n=7)	Control group (Week 2)	PRP-treated group (Week 2)	Control group (Week 4)	PRP-treated group (Week 4)
Inflammatory cell	2.29 \pm 0.4	1.14 \pm 0.6* ¹	2.43 \pm 0.5	0.86 \pm 0.6* ²
Tendon continuity	2.14 \pm 0.3	1.57 \pm 0.5 [†]	2.41 \pm 0.5	2.00 \pm 0.0
Vascularization	1.86 \pm 0.3	1.14 \pm 0.6* ¹	1.86 \pm 0.9	0.71 \pm 0.4* ²
New bone formation	1 \pm 1.1	0.14 \pm 0.3	1.57 \pm 1.2	0.14 \pm 0.3

*: Significantly less than the control group (1: at 2 weeks, 2: at 4 weeks), [†]: Significantly less than the control group (Week 2), [‡]: Significantly less than the control group (1: at 2 weeks, 2: at 4 weeks).

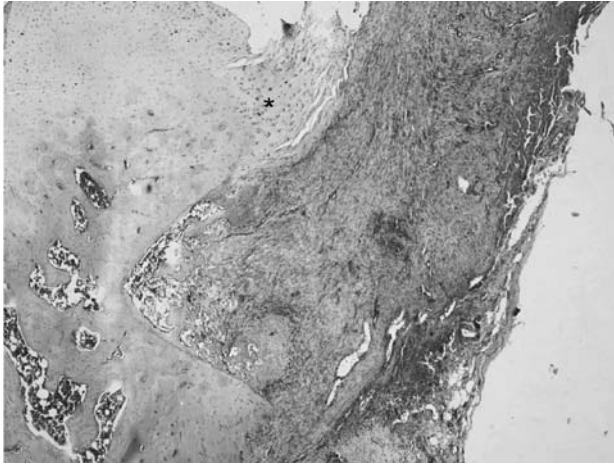


Fig. 3. View from the control group 2 weeks after the surgery. Fibrovascular tissue with increased number of inflammatory cells and capillaries is seen. Fibrocartilage and calcified fibrocartilage layers cannot be differentiated (*: Normal tendon area) (H-E x4). [Color figure can be viewed in the online issue, which is available at www.aott.org.tr]

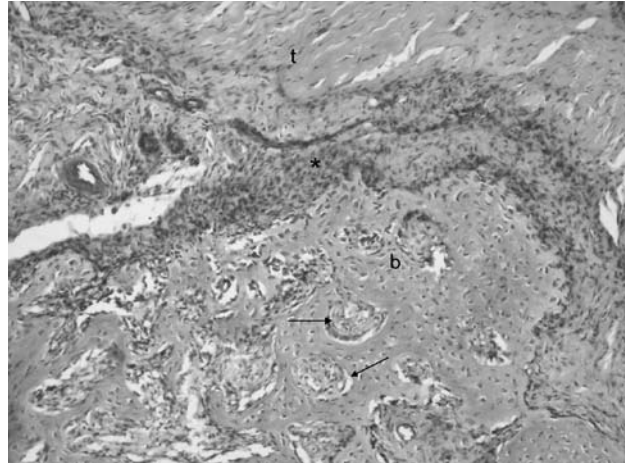


Fig. 4. View from the study group 2 weeks after the surgery. The tendon (t), interface area (*) and the bone (b) can be identified with newly forming spongy bone (arrows) at healing area (H-E x4). [Color figure can be viewed in the online issue, which is available at www.aott.org.tr]

rated with indistinguishable fibrocartilage and calcified fibrocartilage zones and increased volume of inflammatory cells and vascularity (Fig. 3). At some sections, fibrocartilage area was distinguishable and the interface area could be defined between the bone and the tendon. In the Week 2 study group, fibrovascular tissue was also present with newly formed ossification areas in the form of the bony structure (Fig. 4). In the Week 4 control group, there was an increase of lymphocyte-like cells at some areas and remodeling of spongy-like bone at the humerus head (Figs. 5-7). Unlike the other groups,

there was no new bone formation in the Week 4 study group with presence of the mature bone. Tendon continuity was better in study group than the control group, especially at Day 15 ($p=0.04$). In the Week 4 study group, inflammatory cell number and vascularity were decreased at a greater extent with more regular orientation of collagen fibers. Basophilia was evident between cartilage cells at fibrocartilage zone (Figs. 8 and 9). Overall, vascularity and inflammatory cells were less in the study group than the control group. This difference was more obvious in the Week 4 groups (Week 2 vascu-

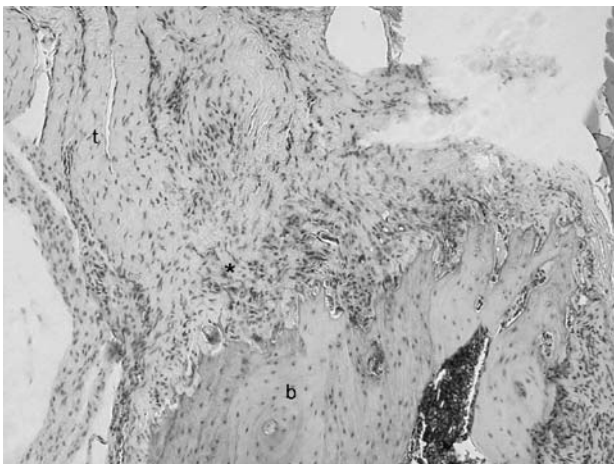


Fig. 5. View from the control group 4 weeks after the surgery. The tendon (t), interface area (*) and the bone (b) can be identified. Disorganized collagen fiber orientation with increased number of the capillaries is seen (H-E x10). [Color figure can be viewed in the online issue, which is available at www.aott.org.tr]

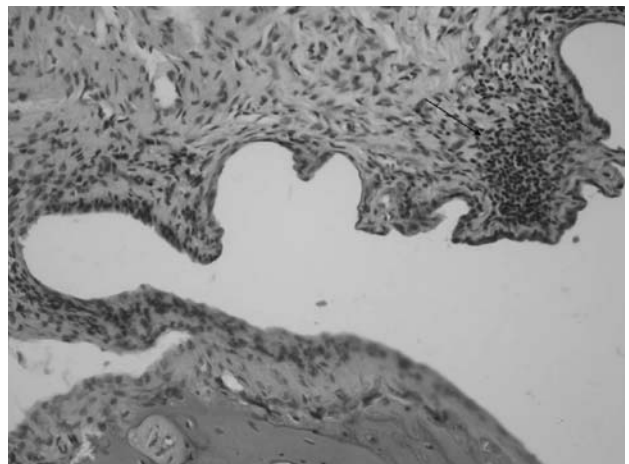


Fig. 6. View from the control group 4 weeks after the surgery. Lymphocyte dominant inflammatory cell infiltrate into fibrovascular tissue (arrow) (H-E x20). [Color figure can be viewed in the online issue, which is available at www.aott.org.tr]

larity: $p=0.03$, inflammation: $p=0.007$; Week 4 vascularity: $p=0.01$, inflammation: $p=0.003$).

Two specimens from the Week 4 study group and one specimen from the Week 4 control group were excluded from the study because of different failure modes, such as bone fracture or the slippage of the specimen at the holding jaw while testing.

Failure mode was elongation of the tendon with avulsion of the repair site from the bony insertion area. Load to failure value of the study group at Week 2 was 10.2 ± 3.5 N, which was higher than the Week 2 control group (6.9 ± 2.0 N) ($p=0.03$). There was no significant difference between the Week 4 study group (11.1 ± 3.3 N) and Week 4 control group (10.4 ± 7.3 N) ($p>0.05$). There was no significant difference between different time periods (Week 2 and Week 4) for each group ($p>0.05$).

Discussion

Currently there is little information on biologic methods to improve tendon-to-bone healing or remodeling. Biologic improvement of the rotator cuff tendon healing to the bone is an attractive option and several growth factors have been utilized to enhance rotator cuff tendon healing to the bone.^[18,21] PRP has several advantages over recombinant growth factors or products of animal origin. First, the autologous preparation of PRP avoids complex regulatory pathways. In addition, safety issues such as immunological reactions or carcinogenesis are of much less concern. Finally, PRP costs are less than those associated with the use of recombinant proteins.^[12]

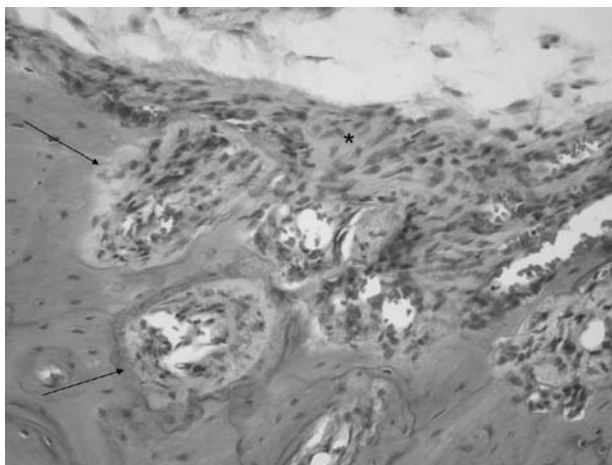


Fig. 7. View from the control group 4 weeks after the surgery. Newly forming bone (arrows) and the interface area (*) are shown. (H-E x10). [Color figure can be viewed in the online issue, which is available at www.aott.org.tr]

In the present study, the degree of inflammation and angiogenesis were less in the study group than the control group. Tendon thickness and continuity was better in the study group two weeks postoperatively. Study group tendons failed at a higher load than the control groups at two weeks postoperatively.

Platelet-rich plasma contains up to 8 times the concentration of platelets found in whole blood. These platelets contain α -granules, which can release a multitude of growth factors, such as PDGF, IGF-1, TGF- β , FGF, VEGF, EGF, and HGF. The fact that PRP contains several different growth factors, present in physi-

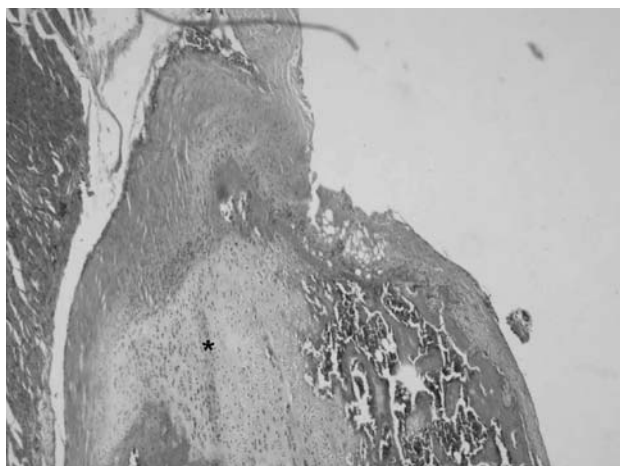


Fig. 8. View from the study group 4 weeks after the surgery. Decrease in the volume of the inflammatory cells and the capillaries with obvious basophilia between cartilage cells at the fibrocartilage area (*) is seen. (H-E x4). [Color figure can be viewed in the online issue, which is available at www.aott.org.tr]

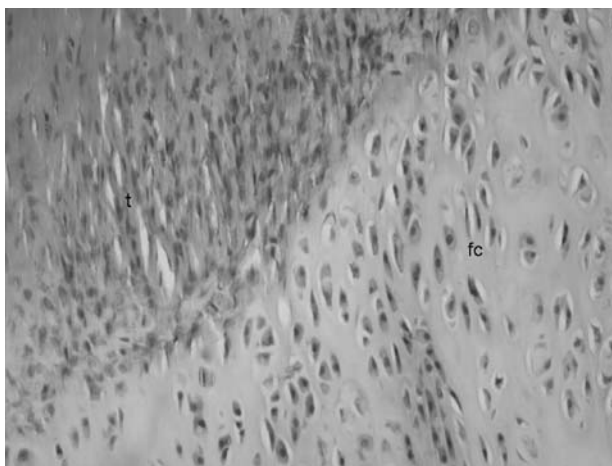


Fig. 9. View from the study group 4 weeks after the surgery. Regular orientation of the collagen fibers is observed. (t: tendon, fc: fibrocartilage) (H&E, x10). [Color figure can be viewed in the online issue, which is available at www.aott.org.tr]

ological proportions, is an appealing benefit compared to isolated growth factors. Additionally, the individual roles of these factors could be modified by the presence of other molecules.^[11,13,22]

The lower degrees of inflammation and angiogenesis in the study group was caused by the proven effect of PRP on the increased expression of the matrix degrading enzymes in addition to the increased cell proliferation and collagen production at tendon cells, resulting in accelerated remodeling of the injured tendon.^[6,7] Additionally, Hammond et al. reported improvement and recovery from muscle strain with limitation of the inflammation in a rat muscle injury model as early as possible, 3 days after the injection.^[13]

Positive effects of PRP on rotator cuff tendon healing could only be biomechanically reported at Week 2 groups. This may be due to the early effects of platelets on tendon healing. Kajikawa et al. reported increased circulation-derived cells infiltration to the wounded area and proliferation of cells with enhanced collagen synthesis at one or two weeks after injury, all of which returned to normal levels thereafter.^[23] Supporting this, Virchenko and Aspenberg reported the early influence of platelets on tendon healing in a rat Achilles tendon injury model and that some mechanical stimulation is a prerequisite for the effect of platelets at 14 days after the injury.^[24] Another reason may be that the rotator cuff heals expeditiously in a rodent model making the difference undetectable 4 weeks after injury.^[25,26]

Platelet-rich plasma has various clinical applications in the field of orthopedics, including rotator cuff surgery.^[8-11,27,28] However, to our knowledge, no prospective randomized controlled clinical trial or experimental in vivo study exists showing the effect of PRP on rotator cuff tendon healing. In the present study, autologous PRP with the addition of calcium chloride 'promoting the gradual formation of native thrombin, mimicking the physiologic clotting process and enabling a more sustained release of growth factors'^[10,29] was proven to affect the early phase of rotator cuff tendon healing with better histological and biomechanical parameters in the study group.

There were some limitations to our study. Our animal model did not reflect the degenerative, age-related large rotator cuff tears commonly seen in humans, who tend to present with intrinsic degenerative changes in the torn rotator cuff tendon (tendinosis), tendon retraction, and osteoporosis of the greater tubercle. However, the relevance of this animal model has been established in the literature.^[19,30,31] The single load-to-failure test construct used in this study did not replicate the clinical

setting, which was more consistent with a cyclic load application. Additionally, the failure mode observed macroscopically was found to be tendon-lengthening with resultant avulsion of the tendon from the repair site. This was dependent, however, on gross examination and possibly requires further microscopic examination to clearly diagnose tendon organization at the repair site and normal site. A third possible limitation was that we did not identify which components of the PRP were responsible for the improvements we found or provided information on the bioavailability or duration of the PRP activity at the repair site. However, because PRP is easily obtainable through several commercial centrifuge devices and no negative side effects have been reported, it may not be necessary to isolate the specific growth factors within PRP that account for the enhanced recovery from injury.

In conclusion, local autologous platelet-rich plasma enhanced initial tendon-to-bone healing in a rat rotator cuff repair model. PRP may have beneficial effects on initial stage of rotator cuff tendon-to-bone healing.

Conflicts of Interest: No conflicts declared.

References

- Galatz LM, Ball CM, Teefey SA, Middleton WD, Yamaguchi K. The outcome and repair integrity of completely arthroscopically repaired large and massive rotator cuff tears. *J Bone Joint Surg Am* 2004;86-A:219-24.
- Rodeo SA, Arnoczky SP, Torzilli PA, Hidaka C, Warren RF. Tendon healing in a bone tunnel. A biomechanical and histological study in the dog. *J Bone Joint Surg Am* 1993;75:1795-803.
- Cohen DB, Kawamura S, Ehteshami JR, Rodeo SA. Indomethacin and celecoxib impair rotator cuff tendon-to-bone healing. *Am J Sports Med* 2006;34:362-9.
- Gamradt SC, Rodeo SA, Warren RF. Platelet-rich plasma in rotator cuff repair. *Tech Orthop* 2007;22:26-33.
- Lopez-Vidriero E, Goulding KA, Simon DA, Sanchez M, Johnson DH. The use of platelet-rich plasma in arthroscopy and sports medicine: optimizing the healing environment. *Arthroscopy* 2010;26:269-78.
- Anitua E, Andía I, Sanchez M, Azofra J, del Mar Zalduendo M, de la Fuente M, et al. Autologous preparations rich in growth factors promote proliferation and induce VEGF and HGF production by human tendon cells in culture. *J Orthop Res* 2005;23:281-6.
- de Mos M, van der Windt AE, Jahr H, van Schie HT, Weinans H, Verhaar JA, et al. Can platelet-rich plasma enhance tendon repair? A cell culture study. *Am J Sports Med* 2008;36:1171-8.
- Mishra A, Pavelko T. Treatment of chronic elbow tendinosis with buffered platelet-rich plasma. *Am J Sports Med* 2006;34:1774-8.
- Kon E, Filardo G, Delcogliano M, Presti ML, Russo A, Bondi A, et al. Platelet-rich plasma: new clinical application:

- a pilot study for treatment of jumper's knee. *Injury* 2009;40:598-603.
10. Sanchez M, Anitua E, Cugat R, Azofra J, Guadilla J, Seijas R, et al. Nonunions treated with autologous preparation rich in growth factors. *J Orthop Trauma* 2009;23:52-9.
 11. Sánchez M, Anitua E, Azofra J, Andía I, Padilla S, Mujika I. Comparison of surgically repaired Achilles tendon tears using platelet-rich fibrin matrices. *Am J Sports Med* 2007;35:245-51.
 12. Sun Y, Feng Y, Zhang CQ, Chen SB, Cheng XG. The regenerative effect of platelet-rich plasma on healing in large osteochondral defects. *Int Orthop* 2010;34:589-97.
 13. Hammond JW, Hinton RY, Curl LA, Muriel JM, Lovering RM. Use of autologous platelet-rich plasma to treat muscle strain injuries. *Am J Sports Med* 2009;37:1135-42.
 14. Castricini R, Longo UG, De Benedetto M, Panfoli N, Pirani P, Zini R, et al. Platelet-rich plasma augmentation for arthroscopic rotator cuff repair: a randomized controlled trial. *Am J Sports Med* 2011;39:258-65.
 15. Barber FA, Hrnack SA, Snyder SJ, Hapa O. Rotator cuff repair healing influenced by platelet-rich plasma construct augmentation. *Arthroscopy* 2011;27:1029-35.
 16. Manning CN, Kim HM, Sakiyama-Elbert S, Galatz LM, Havlioglu N, Thomopoulos S. Sustained delivery of transforming growth factor beta three enhances tendon-to-bone healing in a rat model. *J Orthop Res* 2011;29:1099-105.
 17. Kim HM, Galatz LM, Das R, Havlioglu N, Rothermich SY, Thomopoulos S. The role of transforming growth factor beta isoforms in tendon-to-bone healing. *Connect Tissue Res* 2011;52:87-98.
 18. Rodeo SA, Potter HG, Kawamura S, Turner AS, Kim HJ, Atkinson BL. Biologic augmentation of rotator cuff tendon-healing with use of a mixture of osteoinductive growth factors. *J Bone Joint Surg Am* 2007;89:2485-97.
 19. Ide J, Kikukawa K, Hirose J, Iyama K, Sakamoto H, Fujimoto T, et al. The effect of a local application of fibroblast growth factor-2 on tendon-to-bone remodeling in rats with acute injury and repair of the supraspinatus tendon. *J Shoulder Elbow Surg* 2009;18:391-8.
 20. Virchenko O, Grenegård M, Aspenberg P. Independent and additive stimulation of tendon repair by thrombin and platelets. *Acta Orthop* 2006;77:960-6.
 21. Murray DH, Kubiak EN, Jazrawi LM, Araghi A, Kummer F, Loebenberg MI, et al. The effect of cartilage-derived morphogenetic protein 2 on initial healing of a rotator cuff defect in a rat model. *J Shoulder Elbow Surg* 2007;16:251-4.
 22. Creaney L, Hamilton B. Growth factor delivery methods in the management of sports injuries: the state of play. *Br J Sports Med* 2008;42:314-20.
 23. Kajikawa Y, Morihara T, Sakamoto H, Matsuda K, Oshima Y, Yoshida A, et al. Platelet-rich plasma enhances the initial mobilization of circulation-derived cells for tendon healing. *J Cell Physiol* 2008;215:837-45.
 24. Virchenko O, Aspenberg P. How can one platelet injection after tendon injury lead to a stronger tendon after 4 weeks? Interplay between early regeneration and mechanical stimulation. *Acta Orthop* 2006;77:806-12.
 25. Bedi A, Kovacevic D, Hettrich C, Gulotta LV, Ehteshami JR, Warren RF, et al. The effect of matrix metalloproteinase inhibition on tendon-to-bone healing in a rotator cuff repair model. *J Shoulder Elbow Surg* 2010;19:384-91.
 26. Bedi A, Fox AJ, Kovacevic D, Deng XH, Warren RF, Rodeo SA. Doxycycline-mediated inhibition of matrix metalloproteinases improves healing after rotator cuff repair. *Am J Sports Med* 2010;38:308-17.
 27. Randelli PS, Arrigoni P, Cabitza P, Volpi P, Maffulli N. Autologous platelet rich plasma for arthroscopic rotator cuff repair. A pilot study. *Disabil Rehabil* 2008;30:1584-9.
 28. Everts PA, Devilee RJ, Oosterbos CJ, Mahoney CB, Schattenkerk ME, Knape JT, et al. Autologous platelet gel and fibrin sealant enhance the efficacy of total knee arthroplasty: improved range of motion, decreased length of stay and a reduced incidence of arthrofibrosis. *Knee Surg Sports Traumatol Arthrosc* 2007;15:888-94.
 29. Tsay RC, Vo J, Burke A, Eisig SB, Lu HH, Landesberg R. Differential growth factor retention by platelet-rich plasma composites. *J Oral Maxillofac Surg* 2005;63:521-8.
 30. Carpenter JE, Thomopoulos S, Flanagan CL, DeBano CM, Soslowky LJ. Rotator cuff defect healing: a biomechanical and histologic analysis in an animal model. *J Shoulder Elbow Surg* 1998;7:599-605.
 31. Thomopoulos S, Soslowky LJ, Flanagan CL, Tun S, Keefer CC, Mastaw J, et al. The effect of fibrin clot on healing rat supraspinatus tendon defects. *J Shoulder Elbow Surg* 2002;11:239-47.