



The effect of morphometric relationship between the glenoid fossa and the humeral head on rotator cuff pathology

Nurdan ÇAY¹, Özgür TOSUN¹, Metin DOĞAN², Mustafa KARAOĞLANOĞLU¹, Murat BOZKURT²

¹Department of Radiology, Faculty of Medicine, Yıldırım Beyazıt University, Atatürk Training and Research Hospital, Ankara, Turkey;

²Department of Orthopedics and Traumatology, Faculty of Medicine, Yıldırım Beyazıt University, Atatürk Training and Research Hospital, Ankara, Turkey

Objective: The aim of this study was to investigate the impact of the morphometric association between the glenoid fossa and the humeral head on rotator cuff pathology.

Methods: Shoulder MRI examinations performed for any cause in study centers between August 2008 and August 2009 were retrospectively evaluated. Shoulder MRI exams having rotator cuff pathology, such as trauma, degeneration, and acromion Type 2, 3 and 4 were excluded. The study included 62 shoulder exams with rotator cuff pathology having Type 1 acromion morphology and 60 shoulder exams without rotator cuff pathology (control group). Glenoid anteroposterior distance and the humeral head diameter in axial images, humeral head diameter and glenoid articular surface diameter in coronal images and their ratios were measured in both groups. Subacromial distance was measured using sagittal images. The rotator cuff was evaluated in fat-suppressed T2-weighted and proton density-weighted images.

Results: The difference between subacromial distances in the rotator cuff pathology group (8.94±1.43 mm) and control group (10.96±1.62 mm) was statistically significant (p<0.001). There was no statistical significance between the two groups in humeral head diameter, glenoid articular surface diameter, glenoid anteroposterior distance and their ratios (p>0.05).

Conclusion: There is no association between the humeral head and the glenoid articular surface which can result in rotator cuff pathology. The glenohumeral joint was determined as a compatible joint morphometrically. Therefore, if they cannot be explained by an extrinsic cause, pathologies related to the rotator cuff itself should be investigated in subjects with rotator cuff pathology.

Key words: Glenoid fossa; humerus; morphometry; MRI; rotator cuff pathology.

The most common cause of pain in the shoulder is impingement syndrome in the elderly and glenohumeral instability in younger patients and athletes.^[1] Impingement syndrome is responsible for 44 to 65% of all shoulder complaints.^[2,3] Etiology consists of anatomi-

cal, mechanical or degenerative conditions including narrowing of the subacromial space, thickening of the coracoacromial and acromioclavicular ligaments, rotator cuff muscle weakness or muscle imbalance, scapular muscle dysfunction, and glenohumeral joint instability.^[1,2,4-8]

Correspondence: Nurdan Çay, MD. Yaşamkent Mah. 3222. Cad. 2. Blok (Yakut)

No: 37 D: 27 Çayyolu, Ankara, Turkey.

Tel: +90 505 - 501 73 06 e-mail: nurdancay@yahoo.com

Submitted: January 01, 2012 **Accepted:** August 16, 2012

©2012 Turkish Association of Orthopaedics and Traumatology

Available online at
www.aott.org.tr
doi:10.3944/AOTT.2012.2807
QR (Quick Response) Code:



The glenohumeral joint is the most unstable joint in the body due to its performance of a wide range of movements. Dynamic factors of the rotator cuff muscles and the static factors of the glenohumeral ligaments, the labrum and the joint capsule play a role in glenohumeral joint stability.^[9] Alignment of the humerus and the glenoid articular surfaces is one of the predisposing factors for glenohumeral joint instability which is one of the predisposing factors for rotator cuff pathology.^[9,10] However, no studies have focused on the possible association between the alignment of the humeral head in the glenoid fossa and rotator cuff pathology.

We hypothesized that the difference in size between the humeral head and the glenoid articular surface leads to rotator cuff pathology by extreme movement of the humeral head or by creating direct pressure by the humeral head on rotator cuff during normal joint movement, respectively, or, that the humeral head and the glenoid articular surface are compatible with each other, which in turn does not result in an anatomical condition that will lead to rotator cuff pathology. Based on these hypotheses, we aimed to evaluate the morphometric relationship between the humeral head and the glenoid fossa and to study the effect of this relationship on rotator cuff pathology.

Patients and methods

The Institutional Ethics Committee approved the study protocol and all patients gave informed consent. A total of 841 shoulder MRI examinations of 808 cases performed between August 2008 and August 2009 were retrospectively evaluated. Inclusion criteria were as follows; patients with acromion Type 1 and without arthritis, trauma, surgery, infection, impingement syndrome or labral pathologies. Excluded from the study were 583 exams without acromion Type 1; 12 with evidence of degenerative arthritis, 51 with a history of trauma or operation, 4 with a mass, 50 with impingement syndrome, 16 with superior labrum anterior-posterior (SLAP) lesion, and one with osteomyelitis, avascular necrosis and motion artifact each. The remaining 62 exams (41 females, 21 males; mean age: 48.7 years; range: 25 to 73 years) were included in the study group. The control group included 60 exams of 59 patients (32 females, 27 males; mean age 37.3 years; range: 14 to 61 years) with normal MRI findings.

All exams were performed with 1.5 Tesla MRI (Achieva; Philips, Amsterdam, the Netherlands) and 1.5 Tesla MRI (Intera; Philips, Amsterdam, the Netherlands) devices using a superficial shoulder coil. Fat-suppressed T2-weighted images on the coronal

oblique plane (TR/TE interval 2600-3000/50-80 ms), T1-weighted images on the coronal oblique plane (TR/TE interval 540-720/14-26 ms), fat-suppressed proton density-weighted images on the coronal oblique plane (TR/TE interval 2600-3000/20-30 ms), T2-weighted images on the axial plane (TR/TE interval 2520-3000/60-80 ms), fat-suppressed proton density-weighted images on the axial plane (TR/TE interval 2600-3000/20-30 ms), and T1-weighted images on the sagittal plane (TR/TE interval 450-640/12-24 ms) were obtained. Field of view (FOV) was 18-20 cm, matrix 256x182, slice thickness 4 mm, and section gap 0.3 mm. MRI examinations were reevaluated using the Extreme PACS program (Ekstrem Bir Bil. Ltd., Ankara, Turkey). Rotator cuff muscle tendons, especially the supraspinatus muscle tendon, were evaluated in fat-suppressed T2-weighted and proton density-weighted images on the coronal oblique plane and fat-suppressed proton density-weighted images on the axial plane. Two circles were drawn from both the glenoid articular surface and the humeral head articular surface on the first slice where the glenoid, humeral head, supraspinatus tendon, and acromion could neatly be observed in T1-weighted images in the coronal oblique plane, as the slices progressed from posterior to anterior (Fig. 1). The ratio between these 2 circles was calculated. The subscapularis, infraspinatus and teres minor muscle tendons were evaluated in fat-suppressed proton density-weighted images on the axial plane. A circle was drawn from the articular surface of the humeral head in the first slice where the glenoid articular surface and the humeral head were seen together and the posterior border of the neck portion of the glenoid was clearly visible, as the slices progressed from superior to inferior. The axial ratio was calculated by dividing the diameter of the circle to the anteroposterior distance of the glenoid articular surface (Fig. 2). The shortest distance between the humeral head and the acromion was measured in the slice when the humeral head and the acromion were clearly visible during the progression of slices from medial to lateral on sagittal T1-weighted images (Fig. 3).

Rotator cuff pathologies were assessed separately by two radiologists blinded to the study. Measurements were repeated twice by a single radiologist also blinded to the study. The mean values of these measurements were used.

Data were analyzed using SPSS software v15.0 for Windows (SPSS Inc., Chicago, IL, USA). Continuous variables were presented as mean \pm SD and categorical variables as frequency and percentage. The Kolmogorov-Smirnov test was used to assess the distri-

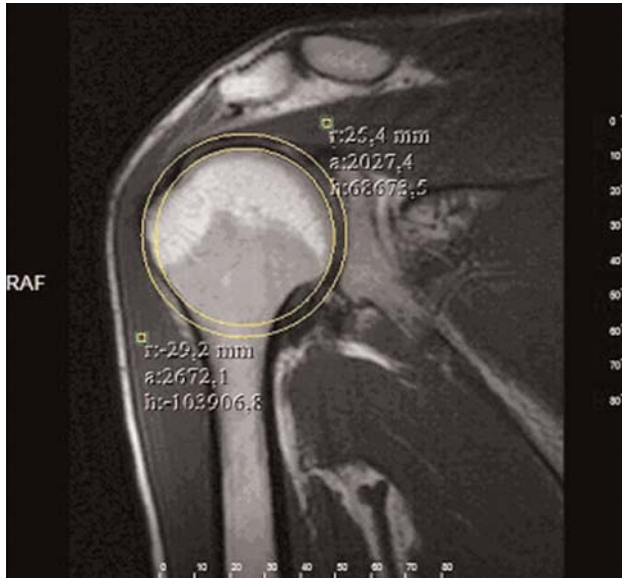


Fig. 1. Measurement of the diameters of the humeral head and the glenoid articular surface on coronal T1-weighted image (yellow circles). [Color figure can be viewed in the online issue, which is available at www.aott.org.tr]

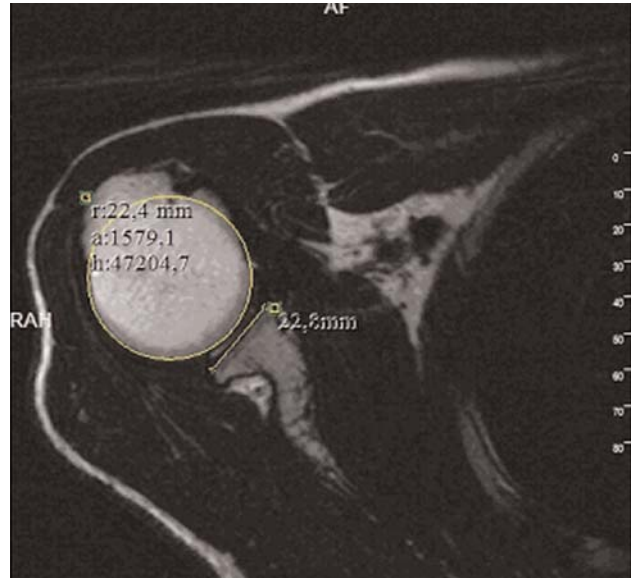


Fig. 2. Measurement of the diameter of the humeral head (yellow circle) and the anteroposterior distance of the glenoid articular surface (yellow line) on axial T2-weighted image. [Color figure can be viewed in the online issue, which is available at www.aott.org.tr]

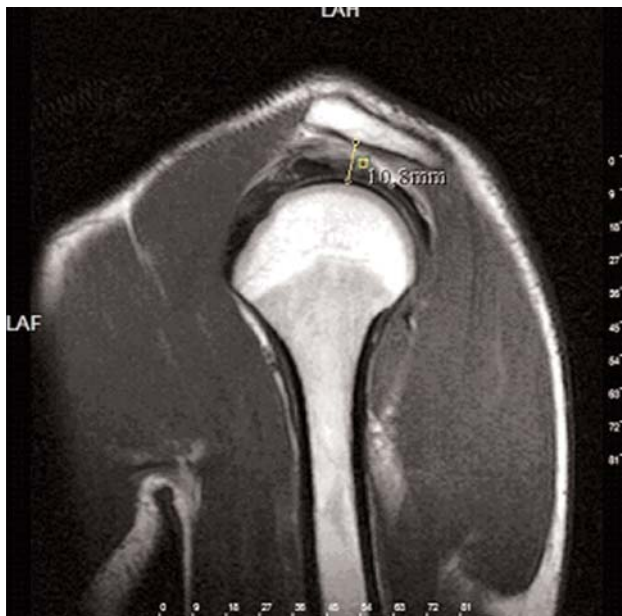

Fig. 3. Measurement of the subacromial distance (yellow line) on sagittal T1-weighted image. [Color figure can be viewed in the online issue, which is available at www.aott.org.tr]

bution of continuous variables. Student’s t-test was used to compare normally distributed continuous variables and the Mann–Whitney U test for variables without normal distribution. The chi-squared test was used to compare categorical variables. A two-tailed p value of <0.05 was considered statistically significant.

Results

Patients with rotator cuff pathology in the study group were significantly older than those in the control group (p<0.001). No significant difference was found between the two groups regarding the examined side and gender (p>0.05) (Table 1).

In patients with rotator cuff pathology, 25 had tendinosis of the supraspinatus, 20 had isolated partial rupture of the supraspinatus, 6 had isolated complete rupture, 7 had tendinosis and partial rupture of the supraspinatus, 2 cases had complete rupture of the supraspinatus and partial rupture of the subscapularis, one had tendinosis of the supraspinatus and partial rupture of the subscapularis, and one had tendinosis and partial rupture of the supraspinatus and tendinosis of the subscapularis. Tendinosis and partial rupture of the supraspinatus constituted the majority of patients in the patient group (72.6%).

Subacromial distance measured on the sagittal plane in Group 1 was significantly less than the values found in Group 2 in all populations (p<0.001) (Fig. 4). In both males and females, subacromial distance measured on the sagittal plane in Group 1 was significantly less than in Group 2 (p<0.001) (Fig. 5).

There was no statistical difference in the diameter of the humeral head, anteroposterior distance values of the glenoid articular surface, their ratios and the differences on the axial planes between the two groups (p>0.05) (Table 2).

Table 1. Baseline characteristics of the study population.

| Characteristics | Group 1 mean±SD | Group 2 mean±SD | p |
|-----------------------|---------------------|---------------------|--------|
| Age in years (range) | 48.7±10.5 (25-73) | 37.3±12.5 (14-61) | <0.001 |
| Number of exams | 62 | 60 | --- |
| Bilateral case | 0 | 1 | --- |
| Sex (M/F) | 21 (34%) / 41 (66%) | 27 (47%) / 32 (53%) | 0.149 |
| Shoulder (right/left) | 43 (69%) / 19 (31%) | 36 (60%) / 24 (40%) | 0.280 |

Group 1: study group; Group 2: control group. F: female, M: male, F: female

Table 2. The diameter of the humeral head, anteroposterior distance values of the glenoid articular surface, their ratios and differences on the axial plane.

| Characteristics | Group 1 mean±SD (n=62) | Group 2 mean±SD (n=60) | p |
|-------------------------|---------------------------|---------------------------|-------|
| Axial glenoid | 22.38±2.93 | 22.53±2.95 | 0.773 |
| Axial humerus | 41.56±3.78 | 42.56±3.71 | 0.144 |
| Axial glenoid / humerus | 0.54±0.06 | 0.53±0.05 | 0.304 |
| Axial glenoid - humerus | -19.19±3.10 | -20.03±2.63 | 0.108 |

Group 1: study group; Group 2: control group. Values are expressed in mm.

Coronal diameter of the humerus was significantly less in Group 1 than in Group 2 ($p < 0.05$) although the diameter of the glenoid articular surface, the glenoid and the humeral head diameter ratios and their differences between the two groups were not statistically significant ($p > 0.05$) (Table 3).

The ratio between the calculated diameter of the humerus on the axial plane and the calculated diameter of the humerus on the coronal plane did not differ significantly between Group 1 (0.95 ± 0.05 mm) and Group 2 (0.94 ± 0.06 mm) ($p > 0.05$).

Sagittal subacromial distance in both genders and the axial humerus to coronal humerus ratio in males were statistically significant. None of the other parameters examined in both genders was significant (Table 4) (Fig. 6).

Discussion

Glenohumeral instability in young individuals and athletes and rotator cuff pathology in the elderly are common causes of shoulder pain. High soft tissue resolution and the ability to receive multiplanar images have made MRI a valuable modality for the evaluation of pathologies of the shoulder joint. The bony structures of the shoulder, bursa and the rotator cuff tendons can be evaluated using MRI with no need for other imaging modalities, including radiographs or interventional procedures.

The best plane on which to evaluate the morphology of the acromion is the sagittal oblique plane. Bigliani et al. described the types of the acromion.^[11] Despite the controversial role of acromial morphology in the pathogenesis of impingement syndrome, the for-

Table 3. The diameters of the humeral head and the glenoid articular surface, their ratios, and differences on the coronal plane.

| Characteristics | Group 1 mean±SD (n=62) | Group 2 mean±SD (n=60) | p |
|---------------------------|---------------------------|---------------------------|-------|
| Coronal glenoid | 46.45±4.73 | 47.69±4.57 | 0.146 |
| Coronal humerus | 43.73±4.09 | 45.52±4.56 | 0.024 |
| Coronal glenoid / humerus | 1.06±0.06 | 1.05±0.06 | 0.223 |
| Coronal glenoid - humerus | 2.73±2.70 | 2.17±2.65 | 0.249 |

Group 1: study group; Group 2: control group. Values are expressed in mm.

Table 4. Evaluation of all parameters according to sex.

| Characteristics | Female | | p | Male | | p |
|---------------------------|------------------------|------------------------|--------|------------------------|------------------------|--------|
| | Group 1 mean±SD (n=41) | Group 2 mean±SD (n=32) | | Group 1 mean±SD (n=21) | Group 2 mean±SD (n=28) | |
| Sagittal subacromial | 8.90±1.44 | 10.79±1.79 | <0.001 | 9.03±1.43 | 11.10±1.41 | <0.001 |
| Axial glenoid | 21.05±2.03 | 20.71±2.11 | 0.481 | 24.97±2.71 | 24.62±2.32 | 0.630 |
| Axial humerus | 39.74±2.53 | 40.34±3.12 | 0.365 | 45.12±3.26 | 45.10±2.53 | 0.977 |
| Coronal glenoid - humerus | 2.72±2.45 | 2.36±2.89 | 0.566 | 2.75±3.20 | 1.95±2.39 | 0.320 |
| Axial glenoid - humerus | -18.69±2.67 | -19.64±2.60 | 0.133 | -20.16±3.69 | -20.48±2.63 | 0.721 |
| Coronal glenoid | 44.66±3.64 | 44.81±3.29 | 0.863 | 49.95±4.72 | 50.98±3.49 | 0.385 |
| Coronal humerus | 41.95±3.01 | 42.45±2.91 | 0.474 | 47.20±3.69 | 49.03±3.42 | 0.080 |
| Axial glenoid / humerus | 0.53±0.05 | 0.51±0.05 | 0.146 | 0.55±0.06 | 0.55±0.05 | 0.592 |
| Coronal glenoid / humerus | 1.07±0.06 | 1.06±0.07 | 0.589 | 1.06±0.07 | 1.04±0.05 | 0.284 |
| Axial / coronal humerus | 0.95±0.05 | 0.95±0.06 | 0.857 | 0.96±0.05 | 0.92±0.05 | 0.011 |

Group 1: study group; Group 2: control group. Values are expressed in mm.

mation of the subacromial spur is thought to be associated with Type 2 and 3 acromial morphologies.^[12] In a study related to acromial morphology, von Schroeder et al. found that the most common acromion type was Type 2 (63%) and the least common was Type 3 (14%).^[13] In our study, 30% of cases (258 exams) consisted of Type 1 acromion. Our results were parallel to the findings described in the literature.

Osteophytes in the lower surface of the acromioclavicular joint can narrow the subacromial space. Therefore, they constitute a potential risk for rotator cuff pathology. In our study, the majority of patients with acromioclavicular joint hypertrophy were in the advanced age group and had associated bone degeneration and subacromial spur formation. Cases with narrowed subacromial distance were excluded from the

study due to these degenerative reasons. In our study, we found a subacromial distance of 10.9 mm in healthy cases and 8.9 mm in diseased cases. Although this difference was statistically significant, it raises the following questions; does the glenohumeral mismatch narrow the distance, or does the superior displacement of the humerus decrease the thickness of the tendon in rotator cuff pathologies?

Several studies evaluating the glenohumeral relationship have been reported in the literature. Saha added the concept of 'the glenohumeral index' by proportioning the maximum diameter of the glenoid to the maximum diameter of the humeral head in different planes.^[14] In later years, Brewer et al. demonstrated that the glenohumeral index was associated with the relationship between the humeral head and the glenoid surface and the tendency of instability of the joint.^[10] Although glenohumeral instability is thought to be among the reasons leading to rotator cuff pathology, no study indicating a relationship between rotator cuff pathology and glenohumeral index has been made. We planned this study to determine whether a relationship is present between the glenoid articular surface diameter/humeral head diameter ratio and rotator cuff pathology.

In previous studies, the glenohumeral index was measured by completing the humeral head to a circle and using the diameter of this circle in the coronal plane. The longest superior-inferior distance of the glenoid articular surface was taken, the humeral head completed to a circle and the diameter taken on the transverse plane. Then, the longest superior-inferior distance of the glenoid articular surface without requiring the same cross-section presence was measured and the values of the glenoid rationed to the humerus.^[14]

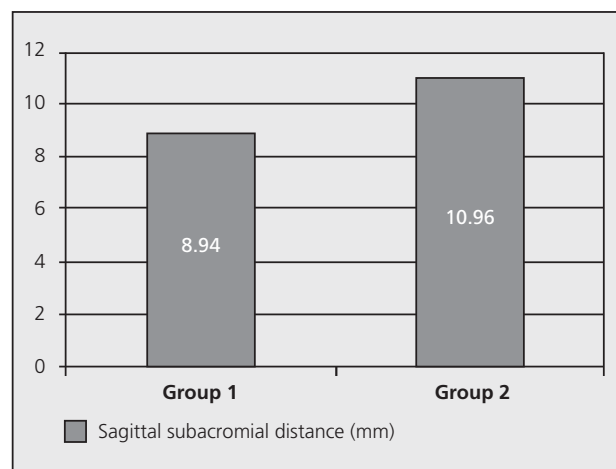


Fig. 4. The values of sagittal subacromial distance in both groups (Group 1: study group; Group 2: control group).

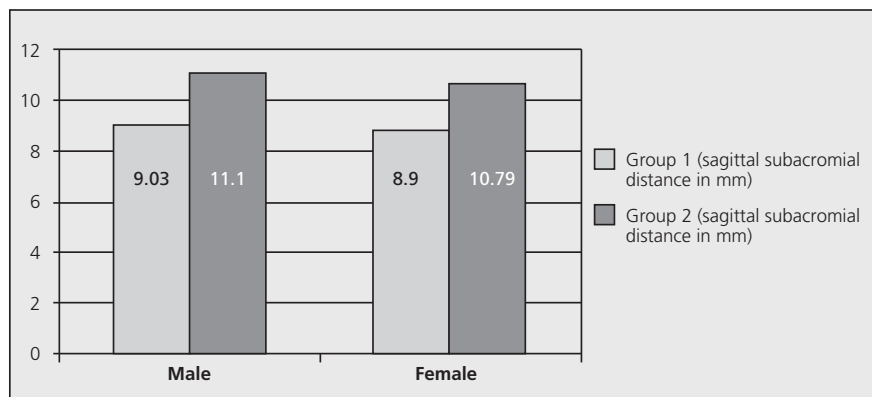


Fig. 5. The values of sagittal subacromial distance according to sex (Group 1: study group; Group 2: control group. Values are presented in mm).

The ratio of the largest diameters is used because of shoulder joint movements. However, no studies have been performed to show how much the largest diameters are likely to meet during movements. Therefore, we did not use the glenohumeral index measurement standards described in the literature and instead focused on the ratio of the diameter of the glenoid articular surface to the diameter of the humeral head in a neutral position of the shoulder. Three main questions were investigated in our study; (1) Is the humeral head smaller than the glenoid articular surface leading to rotator cuff pathology by extreme movement of the humeral head during normal joint movement? (2) Is the humeral head larger than the glenoid articular surface leading to rotator cuff pathology by creating direct pressure on the rotator cuff during normal joint movement? and (3) Is the humeral head and the glenoid articular surface compatible with each other and this compatibility not one of anatomical reasons leading to rotator cuff pathology?

Ianotti et al. reported the radius of the humeral head was 24 ± 2.1 mm on the coronal plane and 22 ± 1.7 mm on the axial plane.^[15] Similarly, in our study, the radius of the humeral head was 22.3 ± 2.1 mm on the coronal plane and 21 ± 1.7 mm on the axial plane. In the same study, the diameter of the humeral head on the axial plane was 2 mm smaller than on the coronal plane and the joint surface was elliptical, not completely spherical with a ratio of 0.92.^[15] In our study, this ratio was 0.94 in healthy cases and 0.95 in patients with rotator cuff pathology. However, no significant statistical difference was found between them ($p=0.133$). These values are consistent with the literature. The difference between the diameters of the glenoid and the humeral head on the coronal plane was 2.1 mm in the control group and 2.7 mm in the study group. The difference was statistically insignificant ($p=0.249$). The humeral diameter/anteroposterior distance of the glenoid was 1.88 mm in the control group and 1.85 mm in the diseased group on the axial plane. The differences between the humeral diameter

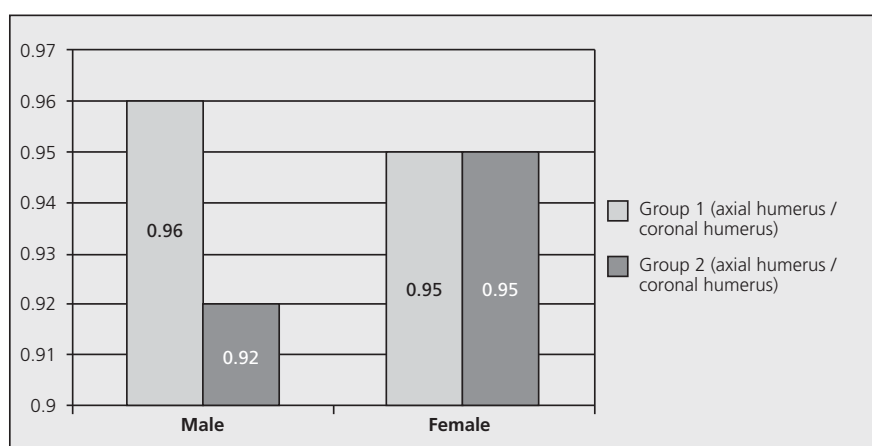


Fig. 6. The ratio of the diameter of the humeral head on the axial plane to the diameter on the coronal plane according to sex (Group 1: study group; Group 2: control group. Values are presented in mm).

and anteroposterior distance of the glenoid in the control and study groups were 20.0 mm and 19.1 mm on the axial plane, respectively. Both the ratio and the difference were statistically insignificant ($p>0.05$).

Coronal diameter of the humerus in patients with rotator cuff pathology was 43.73 ± 4.09 mm and 45.52 ± 4.56 mm in the control group. There was a statistically significant difference between them ($p<0.05$). However, we thought that the coronal diameter of the humeral head alone does not play a role in rotator cuff pathology.

One of the limitations of our study may be that measurements were made by one radiologist. We thought measurements made by a single radiologist would ensure standardization in slices. Repeated measurements at two different times were used to overcome this limitation. Another limitation of the study was the retrospective nature. Although rotator cuff pathology should be confirmed arthroscopically, our patients were diagnosed with MRI only. However, to rule out incorrect diagnoses, images were evaluated independently at different times by two different radiologists.

Although the number of exams was similar in the control and patient groups, there was a significant difference between ages. However, we did not include patients with degenerative changes in the study. Therefore, we believe that the difference in age between the groups did not alter the results of the study.

In conclusion, our study has shown that there is no relationship causing rotator cuff lesions between the humeral head and the glenoid articular surface. On the contrary, the glenohumeral joint is morphometrically a compatible joint. Pathologies that may belong to the rotator cuff itself should be investigated if the pathology cannot be explained with an extrinsic cause in patients with rotator cuff pathology. In this respect, further comprehensive studies are necessary.

Conflicts of Interest: No conflicts declared.

References

1. Prescher A, Klümpen T. The glenoid notch and its relation to the shape of the glenoid cavity of the scapula. *J Anat* 1997;190:457-60.
2. Michener LA, McClure PW, Karduna AR. Anatomical and biomechanical mechanisms of subacromial impingement syndrome. *Clin Biomech (Bristol, Avon)* 2003;18:369-79.
3. Desmeules F, Côté CH, Frémont P. Therapeutic exercise and orthopedic manual therapy for impingement syndrome: a systematic review. *Clin J Sport Med* 2003;13:176-82.
4. Cools AM, Witvrouw EE, De Clercq GA, Danneels LA, Willems TM, Cambier DC, et al. Scapular muscle recruitment pattern: electromyographic response of the trapezius muscle to sudden shoulder movement before and after a fatiguing exercise. *J Orthop Sports Phys Ther* 2002;32:221-9.
5. Fongemie AE, Buss DD, Rolnick SJ. Management of shoulder impingement syndrome and rotator cuff tears. *Am Fam Physician* 1998;57:667-74, 680-2.
6. Janos SC, Boissonault WG. Dysfunction, evaluation and treatment of the shoulder. In: Donatelli RA, Wooden MJ, editors. *Orthopaedic physical therapy*. 3rd ed. Philadelphia: WB Saunders Co; 2001. p. 144-65.
7. McClure PW, Bialker J, Neff N, Williams G, Karduna A. Shoulder function and 3-dimensional kinematics in people with shoulder impingement syndrome before and after a 6-week exercise program. *Phys Ther* 2004;84:832-48.
8. Reddy AS, Mohr KJ, Pink MM, Jobe FW. Electromyographic analysis of the deltoid and rotator cuff muscles in persons with subacromial impingement. *J Shoulder Elbow Surg* 2000;9: 519-23.
9. Ly JQ, Beall DP, Sanders TG. MR imaging of glenohumeral instability. *AJR Am J Roentgenol* 2003;181:203-13.
10. Brewer BJ, Wubben RC, Carrera GF. Excessive retroversion of the glenoid cavity. A cause of non-traumatic posterior instability of the shoulder. *J Bone Joint Surg Am* 1986;68: 724-31.
11. Bigliani LU, Ticker JB, Flatow EL, Soslowsky LJ, Mow VC. The relationship of acromial architecture to rotator cuff disease. *Clin Sports Med* 1991;10:823-38.
12. Kassirjian A, Bencardino JT, Palmer WE. MR imaging of the rotator cuff. *Radiol Clin North Am* 2006;44:503-523, vii-viii.
13. Von Schroeder HP, Kuiper SD, Botte MJ. Osseous anatomy of the scapula. *Clin Orthop Relat Res* 2001;(383):131-9.
14. Saha AK. Dynamic stability of the glenohumeral joint. *Acta Orthop Scand* 1971;42:491-505.
15. Ianotti JP, Gabriel JP, Schneck SL, Evans BG, Misra S. The normal glenohumeral relationships. An anatomical study of one hundred and forty shoulders. *J Bone Joint Surg Am* 1992;74:491-500.