



Comparison of dorsal and volar percutaneous screw fixation methods in acute Type B scaphoid fractures

Yusuf GÜRBÜZ¹, Murat KAYALAR¹, Emin BAL¹, Tulgar TOROS¹, Levent KÜÇÜK², Tahir Sadık SÜĞÜN¹

¹Hand Microsurgery Orthopaedics and Traumatology (EMOT) Hospital, İzmir, Turkey;

²Department of Orthopedics and Traumatology, Faculty of Medicine, Ege University, İzmir, Turkey

Objective: In this study, we aimed to compare the clinical and functional results of patients treated with dorsal or volar percutaneous screw fixation for acute scaphoid fractures.

Methods: We retrospectively evaluated 27 wrists of 26 patients (24 males, 2 females; mean age: 33.1 years) who underwent dorsal or volar percutaneous screw fixation for acute scaphoid fractures between 2000 and 2009. The dorsal approach group contained 13 wrists and the volar approach group 14 wrists. Splint was removed and wrist exercises initiated on the 10th postoperative day. Pinch power, grip power and range of motion were evaluated using the contralateral wrist as controls. Functional evaluation was performed using the patient-rated wrist evaluation score (PRWE) and Mayo wrist scoring system.

Results: According to the Herbert and Fisher's classification system there were 9 B2, 3 B3 and 1 B1 fractures in the dorsal approach group, and 12 B2 and 2 B1 fractures in the volar approach group. Fracture union was achieved in all patients. There was no significant difference between the two groups according to functional and clinical results ($p>0.05$). All patients returned to their jobs in an average of 4.2 weeks and there was no significant difference between the groups ($p=0.437$). Wrist flexion was significantly better in the control wrists in both groups ($p=0.009$). In one patient, the screw was removed due to ongoing pain and asymptomatic screw head displacement in the scaphotrapezoid joint was detected in another.

Conclusion: The surgical approach does not affect the clinical and functional outcomes in percutaneous screw fixation of Type B scaphoid fractures. Percutaneous fixation is a valuable treatment method for Type B scaphoid fractures as it enables early wrist motion and high patient satisfaction.

Key words: Dorsal fixation; percutaneous screw fixation; scaphoid fracture; volar fixation.

Scaphoid fractures are the most common carpal bone fractures.^[1,2] The scaphoid, with its complex anatomical structure and vascular supply, differs from other carpal bones. Various treatment options are available for fractures classified as Type B according to Herbert and Fisher.^[3] In cases of non-displaced fractures, union rates between 88 and 95% have been reported through conser-

vative treatment methods.^[4,5] However, surgical treatment might be required in Herbert Type B fractures with a displacement of more than 1 mm and in patients that refuse long-term immobilization with a plaster cast.^[3]

Early screw fixation methods using open volar and dorsal approaches gave way to percutaneous fixation methods through advancements in screw technology.

Correspondence: Yusuf Gürbüz, MD. El Mikrocerrahi Ortopedi ve Travmatoloji Hastanesi (EMOT), 1418 Sok. No: 14 35230 Kahramanlar, İzmir, Turkey.

Tel: +90 232 - 441 01 21 e-mail: ygurbuz@gmail.com

Submitted: January 12, 2012 **Accepted:** July 5, 2012

©2012 Turkish Association of Orthopaedics and Traumatology

Available online at
www.aott.org.tr
doi:10.3944/AOTT.2012.2816
QR (Quick Response) Code:



Screws can be applied percutaneously through the dorsal or volar side of the wrist. In the dorsal or volar approach, high union and low complication rates have been reported in the literature.^[6-13] Although both methods have individual advantages in terms of application, clinical results are similar.^[10-13]

In this study, we aimed to retrospectively compare the clinical and functional results of percutaneous dorsal and volar fixation methods for the treatment of Herbert Type B acute scaphoid fractures.

Patients and methods

Thirty-eight patients underwent percutaneous fixation for acute scaphoid fractures between 2001 and 2009. The study included 27 wrists of 26 patients (24 males, 2 females; mean age: 33.1 years; range: 18 to 61 years) who were available for the final follow-up. Mean time between injury and surgery was 15.4 (range: 1 to 41) days. The dominant hand was involved in 13 (46%) cases.

Injury was caused by a fall in 23 patients, traffic accident in 2 and assault in one. One patient had a bilateral injury. Anteroposterior and lateral wrist radiographs were used for diagnostic evaluation. Three patients whose radiographic evaluations were deemed inconclusive were diagnosed through computerized tomography.

According to the Herbert and Fisher's classification,^[3] 21 fractures were Type B2, 3 were Type B3 and 3 were Type B1.

All fractures underwent cannulated percutaneous screw fixation. The dorsal approach was used in the 13 fractures (9 B2, 3 B3, 1 B1) in Group 1 and the volar approach in the 14 (12 B2, 2 B1) fractures in Group 2. Headless cannulated variable pitch compression screws (HCVPCS) were used for 6 fractures in Group 1 and 9 in Group 2. Headless cannulated variable pitch fully threaded compression screws (HCVPFTCS) were used in 7 fractures in Group 1 and 5 in Group 2. Demographic information is given in Table 1.

Patients were placed under regional anesthesia onto radiolucent tables in a prone position with the affected

upper extremity in abduction. A pneumatic tourniquet were used but was inflated only in the event of bleeding.

During the dorsal approach, the level of the scapholunate joint was marked on the skin under fluoroscopic control. Adequate wrist flexion was confirmed with the fluoroscopic ring image of the scaphoid. A 0.8-mm Kirschner wire (K-wire) was placed to the scaphoid, in the center of the ring image, with the forearm in pronation then moved from the dorsal to the palmar and taken out of the skin. The wire was pulled back to the distal fracture fragment. If the distal pole flexion increased, the fracture was reduced by pressing toward the dorsal and the K-wire was advanced to the proximal fracture fragment. Fluoroscopy was used to identify whether a humpback deformity developed. After making sure of the wire positioning, the wrist was flexed and the wire moved back toward the dorsal. The bone was reached through a blunt dissection with a 3 mm incision over the K-wire while preserving the extensor tendon and the radial nerve superficial branch. After drilling, osteosynthesis was completed with a screw 2 mm shorter than the measurement. Reduction was checked using fluoroscopy. After irrigation, the skin was closed using nylon sutures. A short arm plaster cast was applied with the wrist in a neutral position (Fig. 1). In our patients, the dorsal approach was preferred in proximal pole fractures (B3=3).

In the volar approach, a 0.8-mm K-wire was advanced from the scaphoid tubercle to the dorsal and the ulnar side with the wrist in extension. Before passing the fracture line with the wire, it was pressed from the distal pole toward the dorsal to reduce the fracture. After reduction was achieved, the wire was moved toward the dorsal. Fluoroscopy was used to determine the presence of humpback deformity and position of the K-wire longitudinal to the scaphoid line. Screw length was measured using a K-wire with a matching length. Using a 3 mm incision over the K-wire, the bone was drilled and osteosynthesis was completed with a screw 2 mm shorter than the measurement. After irrigation, the skin was closed using nylon

Table 1. Demographic features of patients.

	Group 1	Group 2	All patients
Age in years (range)	32.6 (18-54)	33.5 (18-61)	33.1 (18-61)
Dominant side	7	6	13
Operation time (day)	14.6	16.1	15.4
Follow-up time in months	51.7±28.3	37.8±27.9	44.7±28.5
Type of the screws (HCVPCS/ HCVPFTCS)	6/7	9/5	15/12
Type of the fracture according to Herbert & Fisher	9 B2, 3 B3, 1 B1	12 B2, 2 B1	21 B1, 3 B3, 3 B1

HCVPCS: headless cannulated variable pitch compression screws; HCVPFTCS: headless cannulated variable pitch fully threaded compression screws.

sutures. A short arm plaster cast was applied with the wrist in a neutral position (Fig. 2).

Finger exercises were initiated immediately following surgery. The protective wrist plaster cast was removed 10 days postoperatively.

Union was evaluated using radiographs taken in three directions and checking for cross-trabeculation.^[13] A goniometer was used to measure wrist range of motion, a dynamometer (Jamar Hydraulic Hand Dynamometer; Sammons Preston Patterson Medical

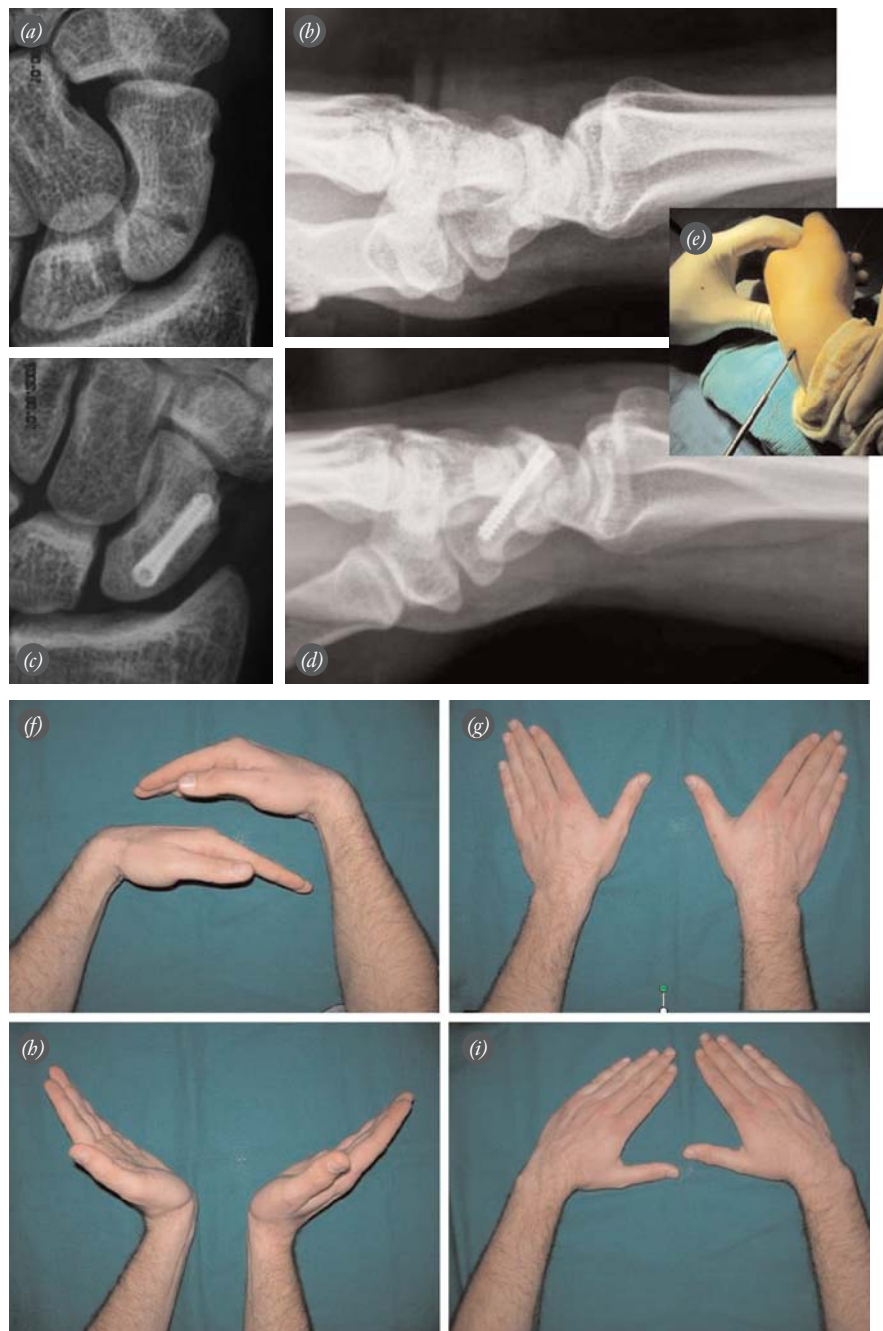


Fig. 1. Images of the scaphoid fracture of a 25-year-old patient. **(a)** Preoperative anteroposterior, **(b)** preoperative lateral, **(c)** postoperative anteroposterior, and **(d)** postoperative lateral X-rays are seen. **(e)** Screw placement in the dorsal approach. **(f-i)** Postoperative 47th month clinical views of the patient. The patient's PRWE score was 1 and Mayo score 90. [Color figure can be viewed in the online issue, which is available at www.aott.org.tr]

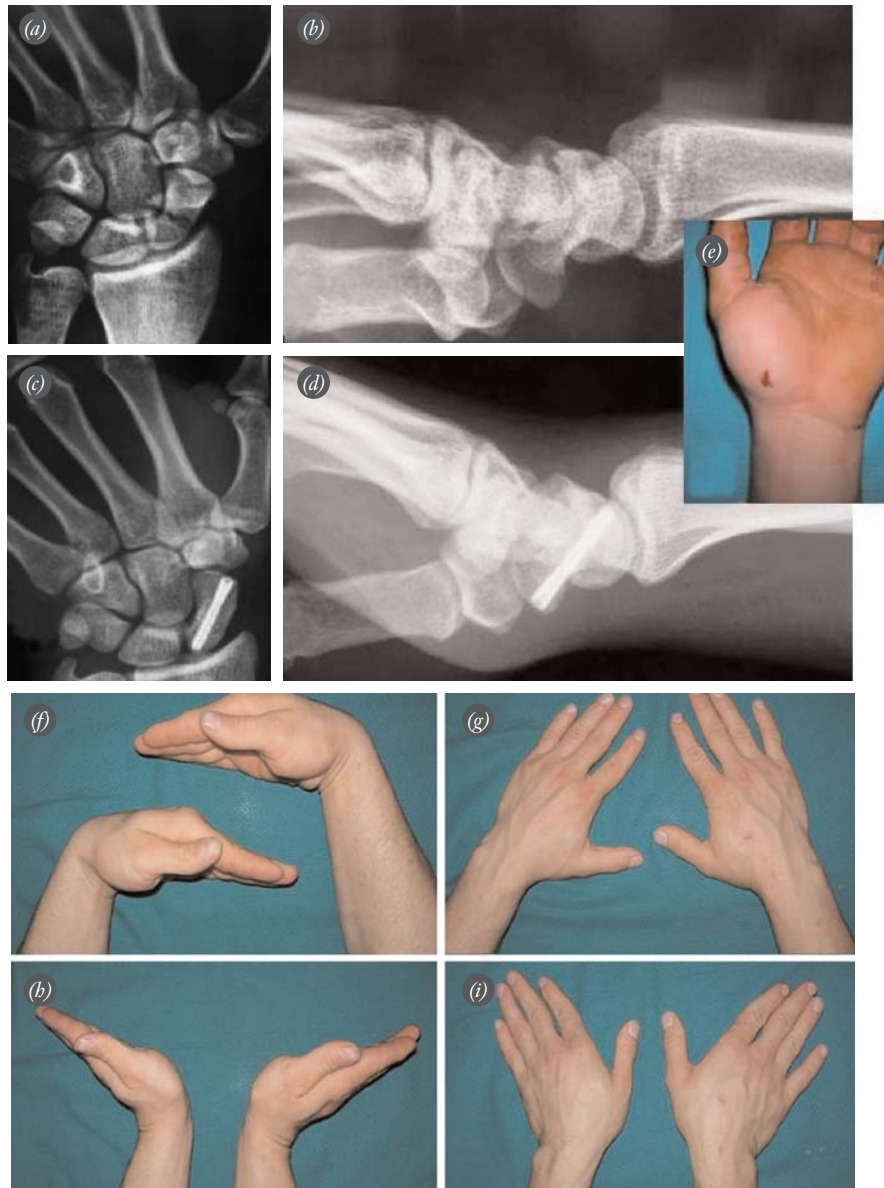


Fig. 2. Images of the scaphoid fracture of a 24-year-old patient. **(a)** Preoperative anteroposterior view, **(b)** preoperative lateral view, **(c)** postoperative anteroposterior view, and **(d)** postoperative lateral view are seen. **(e)** Skin incision performed by volar approach during screw placement. **(f-i)** Postoperative 20th month clinical views of the patient. The patient's PRWE score was 2.5 and Mayo score 85. [Color figure can be viewed in the online issue, which is available at www.aott.org.tr]

Products, Inc., Bolingbrook, IL, USA) for grip strength and a pinch gauge (Baseline pinch gauge; B&L Engineering, Tustin, CA, USA) for pinch strength.^[14,15] Functional evaluation was completed using the Patient-Rated Wrist Evaluation (PRWE) and Mayo wrist scoring system.^[16,17]

SPSS v15.0 (SPSS Inc., Chicago, IL, USA) software was used for statistical analysis. Data acquired in both extremities was analyzed using the t-test and Mann-

Whitney U test. The Pearson correlation test was used to determine correlation between mobility and wrist scores. P values of less than 0.05 were considered statistically significant.

Results

Mean follow-up duration was 44.7 (range: 8 to 120) months. All fractures were healed without complication. Mayo and PRWE tests could not be performed

for one patient in Group 2. Mayo wrist scores were perfect in 20 patients, good in 5 and satisfactory in 1.

In the dorsal approach group, the mean follow-up time was 51.7±28.3 months, mean PRWE score was 1.5±2 and the Mayo score was perfect in 10 patients, good in 2 and satisfactory in 1. Mean mobility was 62° in flexion, 61° in extension, 25° in radial deviation, and 44° in ulnar deviation (Table 2). The patient with bilateral fractures was treated with the dorsal approach. The clinical results of this patient were left out of the statistical analysis.

In the volar approach group, mean follow-up time was 37.8±27.9 months, mean PRWE score was 1.8±1.9 and the Mayo score was excellent in 10 patients and good in 3. Mean mobility was 58° flexion, 61° extension, 33° radial deviation and 50° ulnar deviation (Table 2).

There were no significant statistical differences in the functional and clinical findings between Group 1 and 2. In both groups, a statistically significant difference was detected in the degrees of flexion (p=0.009) between the injured and uninjured sides. However, no correlation was detected between the degree of flexion of the patients and the Mayo wrist scores (p>0.05) (Table 3).

The mean return-to-work time of the patients in the entire series was 4.3 weeks in Group 1 and 4.1 weeks in Group 2. The difference between groups was not significant (p=0.437).

Final follow-up radiographic examinations revealed screw displacement in two patients. One patient in Group 1 had screw displacement in the radioscapoid joint and wrist extension was reduced by 10 degrees. The screw was removed due to pain reported by this patient. In one patient in Group 2, asymptomatic screw head displacement in the scaphotrapezoid joint was detected. No reduction was detected in the mobility of the patient.

There was no extensor tendon or nerve damage in any of the patients during surgery. No cases of superficial infection, complex regional pain syndrome or hypertrophic scarring were found during follow-up.

Discussion

Scaphoid fractures are generally observed in 23 to 43 in a population of 100,000 young, active people with a mean age of 25.^[2] Waist fractures constitute 80% of all scaphoid fractures. The majority of scaphoid fractures are stable fractures that occur as a result of low-energy traumas which cause axial loading on the wrist in extension. Non-segmental stable fractures can be treated with plaster casting. However, plaster cast fixation can cause problems, especially in young patients who want to return to work early.^[18-20] Therefore, surgical fixation has become more common.

Streli first described the use of cannulated screws in the fixation of scaphoid fractures.^[21] Herbert applied the first headless compression screws and their use became common with the modification of this screw by Whipple.^[3,22-26]

Percutaneous screws can be applied through either the dorsal or the volar approach. The dorsal approach provides convenience in the fixation process, especially in proximal region fractures. The three B3 type fractures in our study were treated using the dorsal approach. The volar approach might be preferred as the entry point to the bone can be detected more easily, there is little risk of damaging the radiocarpal joint and the extensor tendons; the fracture is usually stabilized in extension and there is often no need for additional maneuvers. Moreover, the volar approach may also be preferable in fractures located close to the distal pole.

The fixation of scaphoid fractures using the percutaneous volar approach was initiated by Haddad and Goddard.^[7] In the literature, 100% union rates have been reported with this method.^[7,9,10] Yip et al. achieved

Table 2. Clinical and functional outcomes for Group 1 and Group 2 patients.

	Group 1 mean±SD	Group 2 mean±SD	p
Flexion (°)	62.1±10.6	58.2±8.4	0.591
Extension (°)	60.7±12.8	60.7±8.5	0.477
Radial deviation (°)	24.8±8.7	33.2±12.8	0.093
Ulnar deviation (°)	44.2±14.2	50.3±16.6	0.561
Grip strength (kg)	32.6±10.4	37.6±9.2	0.098
Pinch strength (kg)	10.1±1.5	8.7±2.3	0.098
PRWE score	1.5±2.0	1.8±1.9	0.363
Mayo wrist score	89.2±10.5	91.9±7.5	0.683
Return-to-work time	4.30±0.8	4.10±0.6	0.437

PRWE: patient-rated wrist evaluation

Table 3. Clinical and functional outcomes for injured and healthy sides of the patients.

	Injured side mean±SD	Healthy side mean±SD	p
Flexion (°)	60.1±9.6	66.7±8.5	0.009
Extension (°)	60.7±10.6	61.6±9	0.737
Radial deviation (°)	29±11.5	32.5±9.5	0.228
Ulnar deviation (°)	45.3±12.7	50.5±15.4	0.177
Grip strength (kg)	35.3±10	38.9±9.2	0.142
Pinch strength (kg)	9.4±2	10.1±1.8	0.229
PRWE score	1.6±1.9	-	-
Mayo wrist score	90.5±9.1	-	-

PRWE: patient-rated wrist evaluation

fast recovery of normal wrist movement.^[12] Bond et al. reported that percutaneous screw fixation is superior to conservative treatment because it creates faster healing and return-to-work and less morbidity.^[9] In our study, we achieved a 100% success rate in the fractures fixed with headless cannulated screws using the volar approach. The dorsal approach became more commonly used in the early 2000s.^[24] Slade et al. reported 100% successful bony union in 18 patients with acute scaphoid fractures using the dorsal approach and arthroscopy.^[27] Naranje et al.^[13] also reported 100% success rate in 26 patients with acute scaphoid fractures using the dorsal approach without arthroscopy. They reported fast recovery in grip and pinch strengths and wrist mobility returned to close to the healthy side. Mayo scores of 27 of their patients were perfect, 4 good and one unsatisfactory. In our study, 100% successful union was achieved in the 13 patients treated with headless cannulated screw fixation using the dorsal approach. The Mayo score was perfect in 10 patients. Grip and pinch strengths were close to those of the healthy side.

The first study to compare the dorsal and volar approach was published by Jeon et al.^[28] In this prospective study, no statistically significant difference was detected between clinical outcomes (flexion, extension, radial deviation, ulnar deviation, modified Mayo scores). Drác et al.^[29] compared patients treated with limited dorsal approach and those undergoing palmar percutaneous fixation. They reported no statistically significant difference between the two groups in terms of mobility while gripping strength was better in palmar percutaneous fixation patients. In our study, there was no statistically significant difference in clinical outcomes and gripping and pinching strengths between patients treated with the dorsal and volar approach.

Both groups presented a statistically significant difference in terms of flexion between the injured and uninjured extremity ($p=0.009$) although there was no statistical correlation between flexion degree and wrist function scores. Therefore, the reduction in flexion did not influence wrist scores ($p>0.05$).

Risk factors related with the percutaneously applied dorsal and volar approaches on anatomical structures have been discussed in several studies.^[28,30,31] During the dorsal approach, the extensor tendon of the thumb and index finger and posterior interosseous nerve are at risk.^[30] During the volar approach, the superficial palmar arc and the recurrent branch of the median nerve may be injured.^[31] Some authors suggest the use of mini-incision in order to avoid anatomical risks, except for these approaches which can be defined as real percutaneous

approaches.^[32] We recommended blunt dissection from a 3 mm skin incision to the joint capsule after placement of the K-wire (Figs. 1e and 2e). We believe this reduced the risk of injuring the vein, the tendon and the nerve during the drilling and screw placement.

Chondral penetration of the screw used in scaphoid fracture fixation is more often seen in the dorsal approach.^[33] Due to the anatomical structure of the scaphoid bone, penetration into the dorsoradial and scaphotrapezoid joints may not be apparent through direct radiological methods. In their two of six cadaver studies, Tumilty and Squire,^[33] and using computerized tomography, Levitz and Ring^[34] showed that screw displacement in the radioscapoid joint may be overlooked via standard radiography. In our study, there was no differences between groups in terms of screw displacement. In two patients, screw displacement was detected through direct radiographies. During the removal of the screw in one patient due to pain, cartilage damage was detected in the radial joint. Pain has ceased following screw removal. In the second patient, surgical intervention was not necessary as no problems were reported. Radiographs taken in the pronation-oblique positions might be used to detect screw displacement into the dorsoradial joint during operation and at clinical follow-up.^[35]

The shortness of return-to-work time is one of the most important advantages of percutaneous screw fixation. Inoue and Shionoya reported faster return-to-work compared to conservative treatment.^[6] O'Brien and Herbert detected a mean return-to-work time of 3.7 weeks.^[26] Some publications do not recommend conservative treatment in young and active patients.^[36] In line with the literature, return-to-work time in our series on average was 4.2 weeks. In our clinical practice, we recommend percutaneous fixation in the treatment of acute scaphoid fractures to young and active patients due to faster return-to-work.

Limitations to this study included the fact that it was conducted retrospectively with a small group of patients, that the approach was determined according to fracture type as well as the difference between the types of headless cannulated screws used. Different screw types were used due to advancements in screw technology during the time period of the study and the difficulties experienced in supplying screws.

In conclusion, there is no difference between percutaneous approaches in the treatment of Type B scaphoid fractures in terms of fracture healing, clinical outcomes and return-to-work time. Advantages of volar or dorsal percutaneous screw fixation include shorter wrist fixation time and early wrist mobility

compared to plaster cast fixation and open-screw methods. This method is recommended for patients for whom return-to-work time is important and who cannot tolerate plaster casts.

Conflicts of Interest: No conflicts declared.

References

- Hove LM. Epidemiology of scaphoid fractures in Bergen, Norway. *Scand J Plast Reconstr Surg Hand Surg* 1999;33:423-6.
- Kuschner SH, Lane CS, Brien WW, Gellmann H. Scaphoid fractures and scaphoid nonunion. Diagnosis and treatment. *Orthop Rev* 1994;23:861-71.
- Herbert TJ, Fisher WE. Management of the fractured scaphoid using a new bone screw. *J Bone Joint Surg Br* 1984;66:114-23.
- Dias JJ, Brenkel IJ, Finlay DB. Patterns of union in fractures of the waist of the scaphoid. *J Bone Joint Surg Br* 1989;71:307-10.
- Cooney WP, Dobyns JH, Linscheid RL. Fractures of the scaphoid: a rational approach to management. *Clin Orthop Related Res* 1980;(149):90-7.
- Inoue G, Shionoya K. Herbert screw fixation by limited access for acute fractures of the scaphoid. *J Bone Joint Surg Br* 1997;79:418-21.
- Haddad FS, Goddard NJ. Acute percutaneous scaphoid fixation. A pilot study. *J Bone Joint Surg Br* 1998;80:95-9.
- Ledoux P, Chahidi N, Moermans JP, Kinnen L. Percutaneous Herbert screw osteosynthesis of the scaphoid bone. [Article in French] *Acta Orthop Belg* 1995;61:43-7.
- Bond CD, Shin AY, McBride MT, Dao KD. Percutaneous screw fixation or cast immobilization for nondisplaced scaphoid fractures. *J Bone Joint Surg Am* 2001;83-A:483-8.
- Adolfsson L, Lindau T, Arner M. Accutrak screw fixation versus cast immobilisation for undisplaced scaphoid waist fractures. *J Hand Surg Br* 2001;26:192-5.
- Slade JF 3rd, Geissler WB, Gutow AP, Merrell GA. Percutaneous internal fixation of selected scaphoid nonunions with an arthroscopically assisted dorsal approach. *J Bone Joint Surg Am* 2003;85-A Suppl 4:20-32.
- Yip HS, Wu WC, Chang RY, So TY. Percutaneous cannulated screw fixation of acute scaphoid waist fracture. *J Hand Surg Br* 2002;27:42-6.
- Naranje S, Kotwal PP, Shamsery P, Gupta V, Nag HL. Percutaneous fixation of selected scaphoid fractures by dorsal approach. *Int Orthop* 2010;34:997-1003.
- Omer GE Jr. Acute management of peripheral nerve injuries. *Hand Clin* 1986;2:193-206.
- Brunelli G, Monini L, Brunelli F. Problems in nerve lesions. *Microsurgery* 1985;6:187-98.
- MacDermid JC. Development of a scale for patient rating of wrist pain and disability. *J Hand Ther* 1996;9:178-83.
- MacDermid JC, Turgeon T, Richards RS, Beadle M, Roth JH. Patient rating of wrist pain and disability: a reliable and valid measurement tool. *J Orthop Trauma* 1998;12:577-86.
- Gellman H, Caputo RJ, Carter V, Aboulaia A, McKay M. Comparison of short and long thumb-spica casts for non-displaced fractures of the carpal scaphoid. *J Bone Joint Surg Am* 1989;71:354-7.
- Hambidge JE, Desai W, Schranz PJ, Compson JP, Davis TR, Barton NJ. Acute fractures of the scaphoid. Treatment by cast immobilisation with the wrist in flexion or extension? *J Bone Joint Surg Br* 1999;81:91-2.
- Günel İ, Barton NJ, Çalli İ, editors. Current management of scaphoid fractures. Twenty questions answered. London: The Royal Society of Medicine Press; 2002.
- Streli R. Percutaneous screwing of the navicular bone of the hand with a compression drill screw (a new method). [Article in German] *Zentralbl Chir* 1970;95:1060-78.
- Herbert TJ. The fractured scaphoid. St. Louis, MO: Quality Medical Publishing; 1990.
- Whipple TL. Stabilization of the fractured scaphoid under arthroscopic control. *Orthop Clin North Am* 1995;26:749-54.
- Slade JF 3rd, Grauer JN, Mahoney JD. Arthroscopic reduction and percutaneous fixation of scaphoid fractures with a novel dorsal technique. *Orthop Clin North Am* 2001;32:247-61.
- Bagatur AE, Zorer G. Primary fixation of displaced carpal scaphoid fractures with the Herbert-Whipple screw. [Article in Turkish] *Acta Orthop Traumatol Turc* 2002;36:341-5.
- O'Brien L, Herbert T. Internal fixation of acute scaphoid fractures: a new approach to treatment. *Aust N Z J Surg* 1985;55:387-9.
- Slade JF 3rd, Gutow AP, Geissler WB. Percutaneous internal fixation of scaphoid fractures via an arthroscopically assisted dorsal approach. *J Bone Joint Surg Am* 2002;84-A Suppl 2:21-36.
- Jeon IH, Micic ID, Oh CW, Park BC, Kim PT. Percutaneous screw fixation for scaphoid fracture: a comparison between the dorsal and the volar approaches. *J Hand Surg Am* 2009;34:228-36.
- Drác P, Manák P, Cizmár I, Hrbek J, Zapletalová J. A palmar percutaneous volar versus a dorsal limited approach for the treatment of non- and minimally-displaced scaphoid waist fractures: an assessment of functional outcomes and complications. [Article in Czech] *Acta Chir Orthop Traumatol Cech* 2010;77:143-8.
- Adamany DC, Mikola EA, Fraser BJ. Percutaneous fixation of the scaphoid through a dorsal approach: an anatomic study. *J Hand Surg Am* 2008;33:327-31.
- Kamineni S, Lavy CB. Percutaneous fixation of scaphoid fractures. An anatomical study. *J Hand Surg Br* 1999;24:85-8.
- Bond CD, Shin CA. Percutaneous cannulated screw fixation of acute scaphoid fractures. *Tech Hand Up Extrem Surg* 2000;4:81-7.
- Tumilty JA, Squire DS. Unrecognized chondral penetration by a Herbert screw in the scaphoid. *J Hand Surg Am* 1996;21:66-8.
- Levitz S, Ring D. Retrograde (volar) scaphoid screw insertion - a quantitative computed tomographic analysis. *J Hand Surg Am* 2005;30:543-8.
- Kim RY, Lijten EC, Strauch RJ. Pronated oblique view in assessing proximal scaphoid articular cannulated screw penetration. *J Hand Surg Am* 2008;33:1274-7.
- McQueen MM, Gelbke MK, Wakefield A, Will EM, Gaebler C. Percutaneous screw fixation versus conservative treatment for fractures of the waist of the scaphoid: a prospective randomised study. *J Bone Joint Surg Br* 2008;90:66-71.