

## RETINAL MICROVASCULAR DIFFERENCES IN TYPE 2 DIABETES WITHOUT CLINICALLY APPARENT RETINOPATHY: AN OPTICAL COHERENCE TOMOGRAPHY ANGIOGRAPHY STUDY

### RETİNOPATİ BULGUSU OLMAYAN TİP 2 DİYABETLİ HASTALARDA RETİNAL MİKROVASKÜLER FARKLILIKLAR: OPTİK KOHERANS TOMOGRAFİ ANJİOGRAFİ ÇALIŞMASI

Müjdat KARABULUT<sup>1</sup>, Aylin KARALEZLİ<sup>1</sup>, Sinem KARABULUT<sup>1</sup>, Sabahattin SÜL<sup>1</sup>

<sup>1</sup> Muğla Sıtkı Koçman University, Medical School, Department of Ophthalmology, Muğla, TÜRKİYE

**Cite this article as:** Karabulut M, Karalezli A, Karabulut S, Sül S. Retinal Microvascular Differences in Type 2 Diabetes without Clinically Apparent Retinopathy: An Optical Coherence Tomography Angiography Study. Med J SDU 2022; 29(1): 7-13.

#### Öz

##### Amaç

Bu çalışmada, klinik olarak tespit edilebilen diyabetik retinopati bulgusu olmayan tip 2 diyabetli hastalarda optik koherans tomografi anjiyografi ile mikrovasküler değişimlerin saptanması amaçlanmıştır.

##### Gereç ve Yöntem

Çalışma gözlemsel, olgu-kontrol çalışma olarak planlanmıştır. Klinik olarak tespit edilebilen retinopatisi olmayan (Dilate fundus muayenesinde ve fundus fluorescein anjiyografide) 40 tip 2 diyabet hastasının 80 gözü çalışma grubu olarak belirlenmiştir. Yaş ve cinsiyet açısından benzer 40 sağlıklı hastanın 80 sağlam gözü kontrol grubu olarak seçilmiştir. Bütün hastalara tam oftalmolojik muayene sonrası makula merkezli 6x6 mm büyüklüğünde optik koherans tomografi anjiyografi çekimleri yapılmıştır. Derin ve yüzeysel kapiller ağlarda vasküler yoğunluk, foveal avasküler alan, koryokapiller akım alanı parametreleri kontrol grubu ile karşılaştırılmıştır.

#### Bulgular

Yaş ve cinsiyet açısından gruplar arasında fark saptanmamıştır ( $p=0.971$  ve  $p=1.000$ ; sırasıyla). Ortalama diyabet süresi  $10.38\pm 6.31$  yıl (1-25 yıl aralığında) olarak bulunmuştur. Koryokapiller akım alanı çalışma grubunda anlamlı olarak düşük bulunmuştur ( $p<0.001$ ). Derin kapiller ağdaki vasküler yoğunluk, fovea dışındaki tüm kadrantlarda çalışma grubunda düşük bulunmuştur ( $p<0.001$ ). Yüzeysel kapiller ağdaki vasküler yoğunluk, parafoveal kadranda çalışma grubunda anlamlı olarak düşük saptanmıştır ( $p=0.013$ ). İki grup arasında foveal avasküler alan açısından fark saptanmamıştır.

#### Sonuç

Klinik olarak retinopati bulgusu saptanamayan tip 2 diyabetli hastalarda erken dönem vasküler değişimler optik koherans tomografi anjiyografi ile saptanabilir.

**Anahtar Kelimeler:** Derin kapiller ağ, Diyabetik retinopati, Optik koherans tomografi anjiyografi, Parafoveal vasküler yoğunluk, Vasküler yoğunluk.

**Sorumlu yazar ve iletişim adresi /Corresponding author and contact address:** M.K. / mujdatkarabulut@gmail.com

**Müracaat tarihi/Application Date:** 09.04.2021 • **Kabul tarihi/Accepted Date:** 14.06.2021

**ORCID IDs of the authors:** M.K: 0000-0002-7844-5638; A.K: 0000-0003-1316-4656;

S.K: 0000-0002-3139-6402; S.S: 0000-0003-4812-7636

## Abstract

### Objective

We aimed to determine early microvascular changes in type 2 diabetes mellitus patients without clinically apparent retinopathy by optical coherence tomography angiography.

### Material and Methods

80 eyes of patients with diabetes mellitus and without clinically apparent retinopathy, and 80 eyes of age and sex-matched healthy participants were included in this observational case-control study. Vessel density in superficial and deep retinal vessel plexus, foveal avascular zone area, and choriocapillaris flow area in a macular 6.00 × 6.00 mm scan size were evaluated and compared.

### Results

The groups were similar for age and gender ( $p=0.971$  and  $p=1.000$ , respectively). The mean duration of

diabetes was  $10.38\pm 6.31$  years (range, 1-25 years) in the study group. Choriocapillaris flow area was significantly lower in the study group than in the control group ( $p<0.001$ ). Vessel density in the deep retinal plexus was markedly lower in the study group in all quadrants except the fovea ( $p<0.001$ ). Parafoveal vessel density in superficial retinal plexus was markedly reduced in the study group ( $p=0.013$ ). The mean foveal avascular zone area was similar in the two groups.

### Conclusion

Optical coherence tomography angiography can detect early microvascular changes in diabetic patients without clinically apparent retinopathy.

**Keywords:** Deep capillary plexus, Diabetic retinopathy, Optical coherence tomography angiography, Parafoveal vessel density, Vessel density.

## Introduction

Diabetic retinopathy (DR) is a common complication of diabetes mellitus (DM), and possible results might range from mild visual impairment to blindness. As stated by the World Health Organization, 422 million adults live with DM, and this number is expected to increase rapidly (1).

The development of DR might be related to the type and extent of diabetes, blood sugar, arterial blood pressure, and plasma lipids (2, 3). The principal mechanism of how hyperglycemia results in microvascular injury remains unclear (4).

According to neovascularization, DR is categorized as proliferative (PDR) or non-proliferative diabetic retinopathy (NPDR). Intraocular neovascularization, retinal edema, hemorrhage, exudates, and microaneurysms are significant complications of DR. PDR and diabetic macular edema might lead to severe visual impairment. Timely diagnosis, tight regulation of blood lipids, glucose, and pressure are critical to avoid progression.

Fundus fluorescein angiography (FFA), direct fundoscopic examination, and optical coherence tomography (OCT) are commonly used for diagnosis. However, they give findings only after vasculopathy, and macroscopic findings appear.

Optical coherence tomography angiography (OCT-A) is a custom motion contrast imaging technique to gain highly resolved volumetric blood cell movement data and can create angiographic pictures within seconds. OCT-A offers mechanical and functional data and visualizes the microvasculature of choroidal and retinal vascular plexus. It can assign vessel density (VD) of superficial capillary plexus (SCP) and deep capillary plexus (DCP), retinal thickness, foveal avascular zone (FAZ), and choriocapillaris flow area by using different scan sizes.

This study aimed to define the initial retinal microvascular variations detected by OCT-A in type 2 DM patients without clinically apparent retinopathy on FFA, OCT, and fundus examination.

### Material and Methods

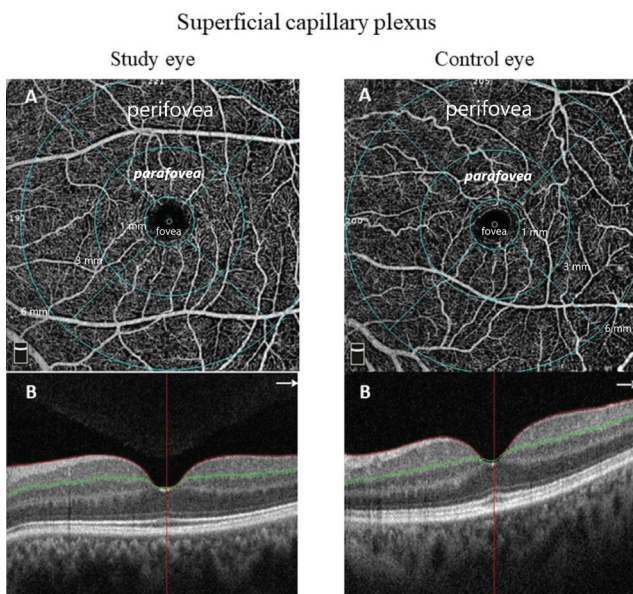
This study was planned as an observational case-control study. 80 eyes of patients who had been diagnosed with type 2 DM and using only oral antidiabetic(s) and 80 eyes of healthy participants were enrolled as study and control groups. The study group included patients referred to our clinic for DR scans and had no DR findings on OCT, FFA images, and dilated fundus examination. Patients with poor DM control (Hemoglobin A1c [HbA1c] levels more than 6.5%), retinal vascular diseases (i.e., hypertensive retinopathy, senile maculopathy,

and uveitis), nystagmus, history of previous ocular surgery, amblyopia, glaucoma, systemic diseases (i.e., arterial hypertension, dyslipidemia, vasculitis, rheumatologic and neurologic diseases), optic nerve disease, high refractive error, axial length greater (AL) than 26 mm in either eye, any stage of clinically apparent retinopathy detected with FFA, OCT or fundus examination and history of insulin injection were excluded. Pictures with movement artifacts and signal strength index fewer than 6/10 were not involved. After a complete ophthalmological checkup, macula-centered images were taken automatically by a single person using RTVue-XR Avanti (Optovue, CA, USA) with a 6.0 × 6.0 mm image size. The VD of both SCP and DCP (Figure 1 and 2), choriocapillaris flow area (Figure 3), and FAZ area (Figure 4) were measured and compared. OCT-A examinations and OCT-A data were analyzed by an author who masked the groups. The VD was automatically calculated by the software embedded in the OCT-A scanner. Retinal microvasculature was analyzed using the automated retinal layer segmentation algorithm available on the

device. The correction was performed manually when an automatic layer segmentation insufficiency was obtained.

We used SPSS software version 21.0.0.0 (IBM Corporation, 1989, 2012.) to analyze the data. The data were represented as the mean ± standard deviation (SD) for continuous variables and frequencies (percentages) for categorical variables. An independent samples t-test was used to compare the groups after verifying the normal distribution of all variables with Shapiro-Wilk tests and homogeneity of variance with Levene's test. A Chi-square test with Yates' correction was applied to compare all groups for gender.  $P < 0.05$  was defined as statically significant.

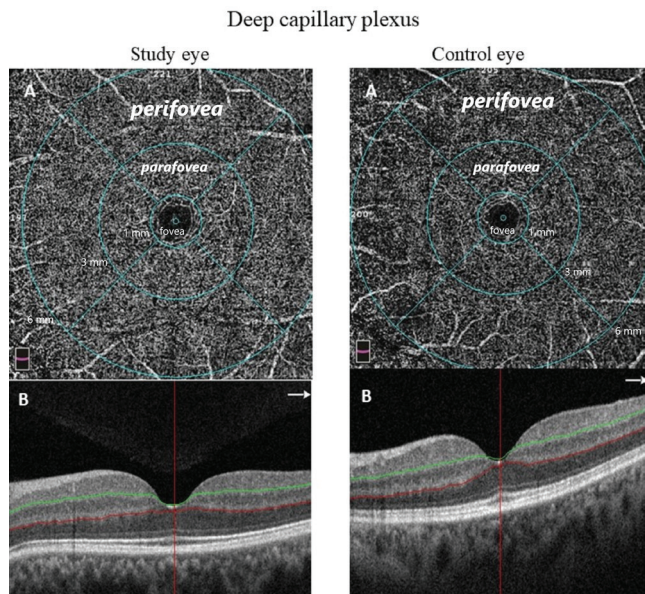
All patients provided written informed consent. We adhered to the Declaration of Helsinki principles. Ethical approval was attained from the Local Clinical Research Ethics Committee (Date and decision number: 07/02/2019:02-III).



**Figure 1:** Demonstration of the SCP. It was imaged between the ILM and the IPL in a 6.00 × 6.00 mm scan size.

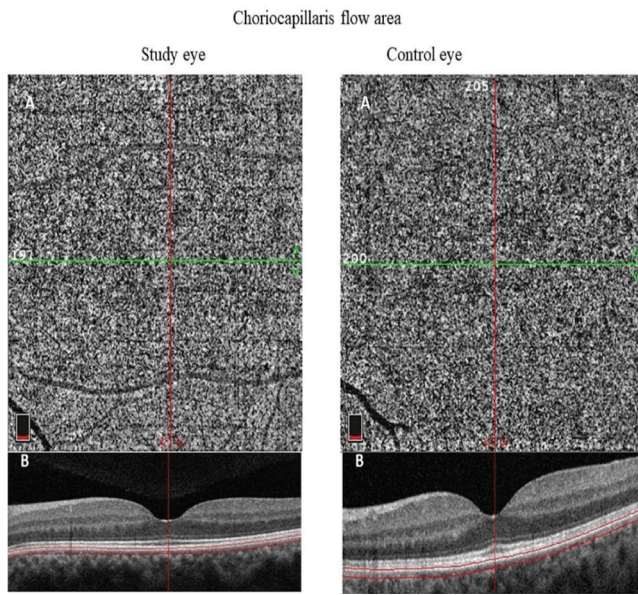
Pictures A and B show the angiographic and cross-sectional view of the selected area. The perifoveal, parafoveal and foveal areas were encircled by 6, 3, and 1 mm diameter rings. In the study group, PRVD (bold italic) was significantly reduced compared to the control group.

ILM: Internal limiting membrane, IPL: Inner plexiform layer, PRVD: Parafoveal vessel density, SCP: Superficial capillary plexus.



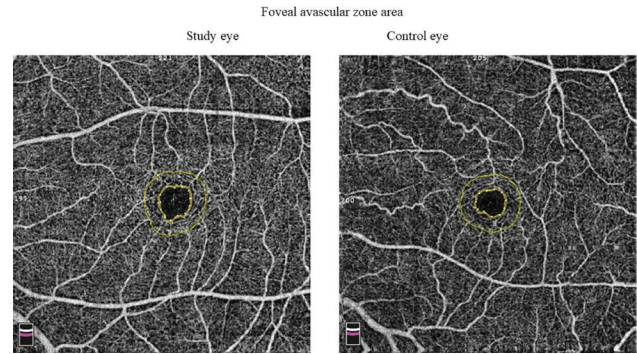
**Figure 2:** Demonstration of the DCP. It was imaged between IPL and OPL in a 6.00 × 6.00 mm scan size.

Pictures A and B show the angiographic and cross-sectional view of the selected area. The perifoveal, parafoveal and foveal areas were encircled by 6, 3, and 1 mm diameter rings. In the study group, VD in the whole, perifoveal, and parafoveal areas (bold italic) was significantly reduced compared to the control group. DCP: Deep capillary plexus, ILM: Internal limiting membrane, OPL: Outer plexiform layer, VD: Vessel density.



**Figure 3:** Demonstration of the choriocapillaris flow area. It was imaged 30 μm deep from the BRM.

Pictures A and B show the angiographic and cross-sectional view of the selected area. In the study group, the choriocapillaris flow area was significantly reduced compared to the control group. BRM: Bruch's membrane.



**Figure 4:** Demonstration of the FAZ area in a study and control eye. The mean FAZ area was similar in both groups. FAZ: Foveal avascular zone.

**Results**

All patients in the study group had well-controlled type 2 DM (HbA1c less than 6.5%) and took at least one oral antidiabetic. None of them had been using any type of insulin when they enrolled in the study. The mean ± SD of the HbA1c and DM duration was 5.71 ± 0.72 % and 10.38 ± 6.31 years (range, 1-25 years) in the study group. The mean ± SD of the age was

55.43 ± 10.73 years (range, 42-64 years) and 52.34 ± 8.04 years (range, 40-63 years) in the study and control groups. The groups were similar for gender and age (p = 1.000. and p = 0.971, respectively) (Table 1).The best-corrected visual acuity (BCVA) was 1.00 decimal in all participants in both groups. For the mean FAZ area, the difference between the groups was not substantial (p=0.804) (Table 1). The mean choriocapillaris flow area was reduced in the

**Table 1**

Comparison of the demographic information, FAZ area, and choriocapillaris flow area of the groups.

	Study group (n=80)	Control group (n=80)	P-value
<b>Gender</b>			
Female	22 (55%)	21 (52.5%)	1.000
Male	18 (45%)	19 (47.5%)	
<b>Age (years)</b>	55.43±10.73 (range, 42-64 years)	52.34±8.04 (range, 40-63 years)	0.971
<b>FAZ area (mm<sup>2</sup>)</b>	0.29±0.12	0.29±0.11	0.804
<b>Choriocapillaris flow area (mm<sup>2</sup>)</b>	2.03±0.12	2.11±0.09	<0.001

FAZ: Foveal avascular zone, n: Number.

**Table 2** Comparison of VD in SCP and DCP on a 6.00 × 6.00 mm macular scan.

	Study group (n=80)	Control group (n=80)	P-value
<b>Density (%)</b>			
<b>Superficial</b>			
Whole image	50.67±3.15	51.77±2.72	0.054
Perifovea	51.31±3.12	52.33±2.83	0.060
Parafovea	52.71±4.63	54.53±2.91	<b>0.013</b>
Fovea	21.15±6.73	20.83±6.53	0.792
<b>Deep</b>			
Whole image	53.01±6.62	57.74±5.18	<b>&lt;0.001</b>
Perifovea	54.09±6.89	59.42±5.47	<b>&lt;0.001</b>
Parafovea	55.71±5.79	60.09±3.53	<b>&lt;0.001</b>
Fovea	37.76±8.09	38.78±7.69	0.477

DCP: Deep capillary plexus, n: Number, SCP: Superficial capillary plexus, VD: Vessel density.

study group ( $p<0.001$ ) (Table 1) compared to the control group. The VD of DCP was decreased in the study group compared to the control group in all regions ( $p<0.001$  for the whole image, parafovea, and perifovea) except the fovea ( $p=0.792$ ). The VD of SCP was reduced only in the parafoveal region ( $p=0.013$ ) in the study group (Table 2).

## Discussion

In this observational case-control study, we found a significant decrease in the whole, perifoveal, and parafoveal vessel density (PRVD) of DCP and a considerable decrease in PRVD of SCP of diabetic patients' eyes. Additionally, the mean choriocapillaris flow area was significantly reduced in the study group. Although VD in other SCP regions was decreased, and the FAZ area was more extensive in the study group, these differences did not reach significance.

The primary mechanism that leads to the progress of DR is controversial. Nevertheless, many interconnecting biochemical pathways can cause microvascular damage. Improved activation of polyol flux and protein kinase diacylglycerol C pathway, insulin-like and vascular endothelial growth factors (VEGF), inflammation, oxidative stress, leukocytosis, and the renin-angiotensin-aldosterone system can accelerate vascular injury (5). These microvascular changes lead to retinal swelling, leakages, vascular closing

off, and ischemia; eventually, DR can be observed macroscopically with fundus examination, OCT, or FFA. However, it may be too late in these stages, and DR's sight-threatening complications might have already begun. The early stages of diabetic retinopathy are usually asymptomatic and often progress unnoticed until vision is affected. Thus, the detection of diabetic microvasculopathy in the initial phase has a vital role in preventing progression to sight-threatening complications.

OCT-A enables a dyeless visualization of the retinal and choroidal microvasculature and creates angiographic pictures within seconds.

Vessel density is calculated as the mass of vascular structure in a measured area (6). A decrease in VD is a signal of retinal changes in the early stage of DR. Reduction in VD has been reported in many studies in diabetic patients even before clinically apparent DR (7,8). Simonett et al. reported a reduction in the PRVD of DCP in DM patients without DR. However, they detected no significant difference in the PRVD of SCP (9). Besides, Carnevali et al. also reported no significant decrease in VD of SCP in DM patients without DR (10).

Conversely, Cao et al. reported that the PRVD of both SCP and DCP declined in patients with DM without DR (11). Some authors thought that decreased

PRVD of both DCP and SCP might be an early sign of the parafoveal capillary nonperfusion initial stage of DR (12, 13). This study found a significant decrease in the whole, perifoveal, and parafoveal VD of the DCP and a considerable decrease in PRVD of the SCP in patients with type 2 DM. Some preclinical retinal changes such as FAZ remodeling and capillary nonperfusion detected by OCT-A, have been described in diabetic patients without clinically apparent DR (11,14). Furthermore, some authors have suggested that the enlargement of FAZ could be an excellent criterion to detect the early stage of DR (15). Enlargement of FAZ in diabetic patients without DR has been reported in many studies but remains controversial (16-18). Goudot et al. reported no substantial enlargement of the FAZ area. Conversely, Lee et al. reported a significantly larger FAZ area in diabetic patients without clinically apparent DR (19, 20). [16]Like Lee et al., De Carlo et al. wrote about the widening of the FAZ area of patients without clinically apparent DR (14). However, Simonett et al. detected no change in patients with early or mild NPDR (9). In this study, we did not detect a substantial difference in the mean FAZ area between the groups.

Choriocapillaris is the primary source of metabolic change for the outer layers of the retina's avascular fovea and outer layers. In diabetic patients, changes in blood flow and hemodynamics in choroid have been reported (21). Microaneurysms, vascular dilatation, obstruction, increased tortuosity, vascular dropout, and new choroidal vessels are choroidal vascular changes in diabetic eyes (22).

The changes in the choriocapillaris flow area of diabetic patients without clinically apparent DR remain controversial. Li et al. reported a reduced choriocapillaris flow area in diabetic patients without clinically apparent DR. They commented that reduced choriocapillaris flow area might be valuable criteria for initial microvascular impairments in DR (23). Likewise, Cao et al. reported significantly decreased choriocapillaris blood flow in patients with type 2 DM (11). Nevertheless, Carnevali et al. did not detect a significant difference in choriocapillaris blood flow in patients with type 1 DM (10). In the current study, we found a reduced choriocapillaris flow area in the study group compared to the control group.

This study showed similar results with other reports as a significant decrease in PRVD of DCP and SCP, and choriocapillaris flow area in diabetic patients without clinically apparent retinopathy compared to the healthy controls. Additionally, we found a significant decrease in the whole and perifoveal VD

in DCP. These findings might be a novel sign of the early stage of DR in diabetic patients without clinically apparent retinopathy.

This study has some limitations. Although the groups were similar regarding age, gender, and BCVA, the number of eyes studied was relatively small. We did not consider the effects of some confounding factors such as refractive error and AL though some OCT-A studies showed that myopic refractive errors and longer AL were related to narrowed arterioles, venules, and decreased flow area (24, 25). Therefore, we excluded the eyes with AL greater than 26 mm and high refractive error. However, we did not match the groups for refractive error and AL.

## Conclusion

In conclusion, OCT-A can identify early changes in retinal vascular plexuses and choriocapillaris flow area in patients with type 2 DM. Like our results, reduction in choriocapillaris flow area and VD, especially PRVD in both SCP and DCP, can be detected by OCT-A. Furthermore, a decrease in the whole and perifoveal VD in DCP might be a novel sign of the early stage of DR in diabetic patients without clinically apparent retinopathy.

## Conflict of Interest Statement

The authors have no conflicts of interest to declare.

## Ethical Approval

We adhered to the Declaration of Helsinki principles. Ethical approval was attained from the Local Clinical Research Ethics Committee (Date and decision number: 07/02/2019:02-III).

## Consent to Participate and Publish

Written informed consent to participate and publish was obtained from all individual participants included in the study.

## Funding

This research did not receive any specific grant from funding agencies in the public, commercial, or not-for-profit sectors.

## References

1. Guariguata L, Whiting DR, Hambleton I, et al. Global estimates of diabetes prevalence for 2013 and projections for 2035. *Diabetes Res Clin Pract.* 2014;103:137-49.
2. Knowles JW, Reaven G. Usual blood pressure and new-onset diabetes risk: Evidence from 4.1 million adults and a meta-analysis. *J Am Coll Cardiol.* 2016;67:1656-7.
3. Krauss RM. Lipids and lipoproteins in patients with type 2 dia-

- betes. *Diabetes Care*. 2004;27:1496-504.
4. Stehouwer CDA. Microvascular dysfunction and hyperglycemia: A vicious cycle with widespread consequences. *Diabetes*. 2018;67:1729-41.
  5. Tarr JM, Kaul K, Chopra M, et al. Pathophysiology of diabetic retinopathy. *ISRN Ophthalmol*. 2013;2013:343560.
  6. You Q, Freeman WR, Weinreb RN, et al. Reproducibility of vessel density measurement with optical coherence tomography angiography in eyes with and without retinopathy. *Retina*. 2017;37:1475-82.
  7. Czako C, Ecsedy M, Récsán Z, et al. Bilateral quantification of vascular density in diabetic patients using optical coherence tomography angiography. *Acta Ophthalmol*. 2017;95:259.
  8. Dimitrova G, Chihara E, Takahashi H, et al. Quantitative retinal optical coherence tomography angiography in patients with diabetes without diabetic retinopathy. *Invest Ophthalmol Vis Sci*. 2017;58:190-6.
  9. Simonett JM, Scarinci F, Picconi F, et al. Early microvascular retinal changes in optical coherence tomography angiography in patients with type 1 diabetes mellitus. *Acta Ophthalmol*. 2017;95:e751-e5.
  10. Carnevali A, Sacconi R, Corbelli E, et al. Optical coherence tomography angiography analysis of retinal vascular plexuses and choriocapillaris in patients with type 1 diabetes without diabetic retinopathy. *Acta Diabetol*. 2017;54:695-702.11.
  11. Cao D, Yang D, Huang Z, et al. Optical coherence tomography angiography discerns preclinical diabetic retinopathy in the eyes of patients with type 2 diabetes without clinical diabetic retinopathy. *Acta Diabetol*. 2018;55:469-77.
  12. Cicinelli MV, Carnevali A, Rabiolo A, et al. Clinical spectrum of macular-foveal capillaries evaluated with optical coherence tomography angiography. *Retina*. 2017;37:436-43.
  13. Ting DSW, Tan GSW, Agrawal R, et al. Optical coherence tomographic angiography in type 2 diabetes and diabetic retinopathy. *JAMA Ophthalmol*. 2017;135:306-12.
  14. Carlo TE CA, Bonini Filho Ma, Adhi M, et al. Detection of microvascular changes in the eyes of patients with diabetes but not clinical diabetic retinopathy using optical coherence tomography angiography. *Retina*. 2015;35:2364-70.
  15. Freiberg FJ, Pfau M, Wons J, et al. Optical coherence tomography angiography of the foveal avascular zone in diabetic retinopathy. *Graefes Arch Clin Exp Ophthalmol*. 2016;254:1051-8.
  16. Hwang TS, Gao SS, Liu L, et al. Automated quantification of capillary nonperfusion using optical coherence tomography angiography in diabetic retinopathy. *JAMA Ophthalmol*. 2016;134:367-73.
  17. Di G, Weihong Y, Xiao Z, et al. A morphological study of the foveal avascular zone in patients with diabetes mellitus using optical coherence tomography angiography. *Graefes Arch Clin Exp Ophthalmol*. 2016;254:873-9.
  18. Takase N, Nozaki M, Kato A, et al. Enlargement of the foveal avascular zone in diabetic eyes evaluated by en face optical coherence tomography angiography. *Retina*. 2015;35:2377-2383.
  19. Goudot MM, Sikorav A, Semoun O, et al. Parafoveal OCT angiography features in diabetic patients without clinical diabetic retinopathy: A qualitative and quantitative analysis. *J Ophthalmol*. 2017;2017:8676091.
  20. Lee DH, Yi HC, Bae SH, et al. Risk factors for retinal microvascular impairment in type 2 diabetic patients without diabetic retinopathy. *PLoS One*. 2018;13:e0202103.
  21. Pemp B, Schmetterer L. Ocular blood flow in diabetes and age-related macular degeneration. *Can J Ophthalmol*. 2008;43:295-301.
  22. Luttj GA. Diabetic choroidopathy. *Vision Res*. 2017;139:161-7.
  23. Li Z, Alzogool M, Xiao J, et al. Optical coherence tomography angiography findings of neurovascular changes in type 2 diabetes mellitus patients without clinical diabetic retinopathy. *Acta Diabetol*. 2018;55:1075-82.
  24. Lim LS, Cheung CY, Lin X, et al. Influence of refractive error and axial length on retinal vessel geometric characteristics. *Invest Ophthalmol Vis Sci*. 2011;52(2):669-678.
  25. Sampson DM, Gong P, An D, et al. Axial length variation impacts on superficial retinal vessel density and foveal avascular zone area measurements using optical coherence tomography angiography. *Invest Ophthalmol Vis Sci*. 2017;58(7):3065-3072.