



Tenosynovial giant cell tumor in an unusual localization

Esin ATIK¹, Tümay ÖZGÜR¹, Aydıner KALACI², Burçin TUNA³

¹Department of Pathology, Faculty of Medicine, Mustafa Kemal University, Hatay, Turkey;

²Department of Orthopedics and Traumatology, Faculty of Medicine, Mustafa Kemal University, Hatay, Turkey;

³Department of Pathology, Faculty of Medicine, Dokuz Eylül University, İzmir, Turkey

Tenosynovial giant cell tumors are benign tumors that are often localized on the palmar sites of the hand. The involvement of large joints such as the knee and ankle are rare. We present an 18-year-old male patient referred to the orthopedics clinic with a mass on his right ankle. No differential diagnosis could be made radiologically. The marginally excised lesion was histopathologically diagnosed as a tenosynovial giant cell tumor. There was no local recurrence during a follow-up of 12 months.

Key words: Ankle; knee; tenosynovial giant cell tumor.

Tenosynovial giant cell tumor (TGCT) was first described by Chassaignac in 1852 as 'cancer of the tendon sheath' and its definition was widened by Jaffe et al. in 1941 to include pigmented villonodular synovitis, bursitis and tenosynovitis.^[1,2] It may be seen at any age but is most common between the ages of 30 and 50 years, and the gender ratio is higher towards women.^[2] It is a tumor of the tendon sheaths and arises from the synovium, and it is classified under benign tumors and tumor-like lesions of the synovial tissues.^[2,3] Tenosynovial giant cell tumor has a localized and a diffuse form. The localized form, also called nodular tenosynovitis, is a nodular or polypoid mass that usually affects the digits. The diffuse form, also known as florid or proliferative synovitis, is less well-defined and generally develops outside the joint, growing in a multinodular pattern that is more irregular than that of localized TGCT. Localized forms occur predominantly on the hand. Less common sites include the larger joints; ankle,

knee, wrist and elbow. This tumor is characterized by a discrete proliferation of rounded synovial-like cells accompanied by a variable number of multinucleated giant cells, inflammatory cells, siderophages, and xanthoma cells. Marginal excision with a small cuff of normal tissue is the common therapy.^[2]

We present an 18-year-old male patient referred to the orthopedics clinic with a mass on his right ankle. No differential diagnosis could be made radiologically. The marginally excised lesion was histopathologically diagnosed as a tenosynovial giant cell tumor.

Case report

An 18-year-old male presented to our outpatient clinic with swelling on the right ankle. The patient had an ankle distortion 3 months prior to application and had a persistent swelling and hyperemia at this site thereafter. In physical examination, there was an immobile mass at the dorsolateral surface of the right foot, not related to

Correspondence: Tümay Özgür, MD. MKÜ Tıp Fakültesi, Patoloji Anabilim Dalı, Serinyol, Hatay, Turkey.

Tel: +90 505 - 229 32 61 e-mail: ozgurtumay@yahoo.com

Submitted: November 10, 2011 **Accepted:** April 5, 2012

©2013 Turkish Association of Orthopaedics and Traumatology

Available online at
www.aott.org.tr
doi:10.3944/AOTT.2013.2773
QR (Quick Response) Code:



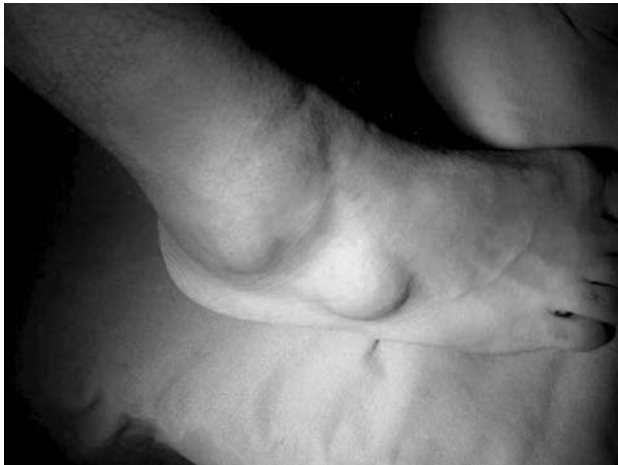

Fig. 1. The soft tissue mass on the dorsolateral surface of the right foot.

the skin but infiltrating the deep soft tissues. Laboratory tests were normal. Magnetic resonance (MR) images revealed hypointense soft tissue masses of 3×3 and 2×2 cm, adjacent to the calcaneus. The mass was well-lined, neither destructing the bone or soft tissues under the fascia (Figs. 1 and 2). Peripheral neural tumors, lipoma and pleomorphic sarcoma were considered in the differential diagnosis. An open biopsy was planned but intraoperative exploration revealed that the lesion had well-defined borders and marginal excision was decided. The tumor was resected and sent to the Pathology Department for examination. Macroscopic examination revealed two lobulated masses with shallow grooves. The larger mass was 3.5×3×2.5 cm and the smaller was 2.5×2.2×2 cm in diameter. Lesions were solid, gray-pink color flecked

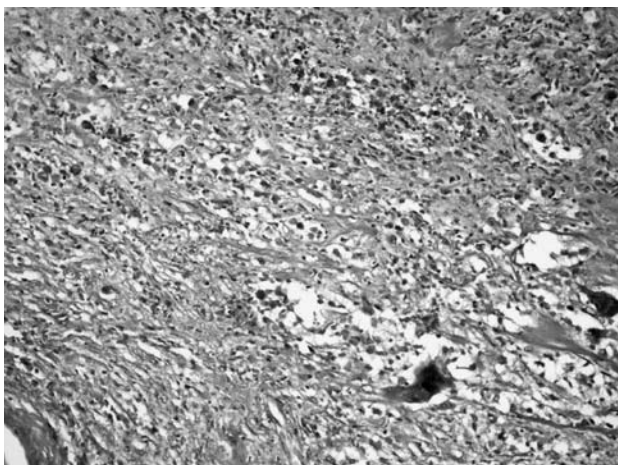


Fig. 3. Tumor that is composed of multinucleated giant cells, xanthoma cells, mononuclear cells and stromal cells with nucleoli (H&E x200).

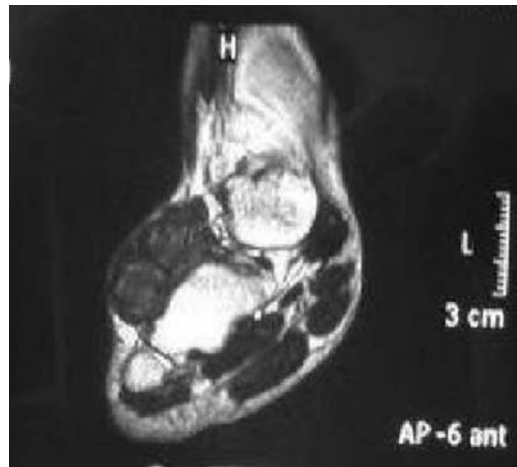


Fig. 2. Soft tissue masses of 3×3 cm and 2×2 cm adjacent to the calcaneus are seen on MR image.

with brown. In microscopic examination, the nodules were partially encapsulated by collagenous capsule and composed of multinucleated giant cells, xanthoma cells, mononuclear cells and stromal cells (Fig. 3). To make the differential diagnosis S100, vimentin, HMB45, actin and high-molecular-weight cytokeratin immunohistochemical stains were used. There was no sign of malignancy and the tumor was diagnosed as tenosynovial giant cell tumor. The patient's postoperative course continued uneventfully. There was no recurrent mass and the patient had no further adjuvant therapy in the 12 month follow-up following surgical excision.

Discussion

Tenosynovial giant cell tumors are benign tumors with uncertain pathogenesis.^[4] They occur most commonly on the palmar sites of fingers.^[4-7] Occurrence on the large joints such as the ankle and knee are rare. Tenosynovial giant cell tumor may occur in either localized or diffuse forms^[4] and patients usually complain of local pain, warmth and swelling.^[8] Surprisingly, our patient had no complaints in addition to the persistent mass in his ankle. Our case is characterized by its rare site and localized form.

The literature cites almost 10 cases of TGCT of both localized and diffuse forms in the ankle.^[4,6,8-10] Two cases of tenosynovial giant cell tumors as accidental findings following episodes of distortion of the ankle were reported.^[4] Matthes et al. presented a case with TGCT in the area of the right ankle joint.^[6]

Clinical diagnosis of this tumor is difficult as various soft tissue lesions can mimic TGCT. MR imaging and computerized tomography are preferred to define the characteristics of the mass although definite diagnosis can only be made pathologic examination.^[11]

Ozdemir et al.^[9] analyzed 196 tumors of the foot and the ankle and reported giant cell tumor to be one of the most frequent benign soft tissue tumors. Of the 140 surgical cases, 9.3% experienced local recurrence in their series. Chou et al. reported that TGCT was the most common tumor in their study of 153 cases localized on the foot and ankle.^[12] For this reason, a correct classification of tumor and appropriate diagnosis is essential for patients' outcome.

Radiologically, TGCTs present usually with soft tissue mass with pressure erosion of the underlying bone. On MR images, TGCTs typically show a low to intermediate signal on T1- and T2-weighted spin-echo sequences due to the presence of hemosiderin.^[13] Our case was a soft tissue mass not eroding the calcaneus but located adjacent to the surrounding tissues under the fascia.

Tenosynovial giant cell tumors are often misdiagnosed as they are rather rare soft tissue tumors.^[2] Histopathologically, foreign body granulomas, necrobiotic granulomas, tendinous xanthomas, fibromas and clear-cell sarcomas are considered in the differential diagnosis. Granulomatous lesions have more inflammatory cells. Giant cells are rare or nonexistent in necrobiotic granulomas. Tendinous xanthomas are often multiple and consist of cholesterol clefts. While fibromas of the tendon sheath can mimic end-stage TGCT, they have more hyalinized stroma and cells are more fibroblastic. Clear-cell sarcomas are more pleomorphic and cellular. The treatment modalities for these lesions range from excisional biopsy to radiation therapy.^[14] Total excision is the therapeutic procedure.^[11]

Tenosynovial giant cell tumors have a high recurrence rate of up to 50% but recurrence is rare in the foot. In the 17 cases of TGCT treated by excision studied by Gibbons et al., there was no local recurrence after a mean follow-up time of 85 months and no further surgery was required.^[8]

The recurrence rate depends mainly on the completeness of the first excision in the localized forms. However, highly cellular tumors with increased mitotic activity and diffuse forms have high recurrence rates.^[2,15,16] For treatment of diffuse and recurrent cases, adjuvant therapy is recommended with extensive synovectomy and low-dose irradiation.^[16,17]

Follow-up is important, although malign transformation has not been documented, even after recurrence. Our patient had no recurrent mass within 12 months.

In conclusion, while rare, TGCTs compose 1.7% of all soft tissue tumors of the knee and ankle region and should be considered in the differential diagnosis

of soft tissue masses. Histopathologic confirmation and follow-up of these tumors are important.^[4]

Conflicts of Interest: No conflicts declared.

References

1. Somerhausen NS, Fletcher CD. Diffuse-type giant cell tumor: clinicopathologic and immunohistochemical analysis of 50 cases with extraarticular disease. *Am J Surg Pathol* 2000;24:479-92.
2. Weiss SW, Goldblum JR. *Enzinger and Weiss's soft tissue tumors*. 4th ed. St Louis, MO: Mosby; 2001. p. 1038-47.
3. Caputo V, Fiorella S, Orlanda E. Postsurgical paracitricul cutaneous satellitosis of giant cell tumour of the tendon sheath, localized type. *Case Rep Dermatol* 2011;3:118-23.
4. Illian C, Kortmann HR, Künstler HO, Poll LW, Schofer M. Tenosynovial giant cell tumors as accidental findings after episodes of distortion of the ankle: two case reports. *J Med Case Rep* 2009;3:9331.
5. Yildiz S, Cetinkol E. Case report: Tenosynovial giant cell tumor arising from the knee joint. [Article in Turkish] *Tani Girisim Radyol* 2003;9:81-3.
6. Matthes G, Richter D, Ostermann PA, Friemann J, Ekkernkamp A. Benign tenosynovial giant cell tumor in the region of the upper ankle joint. A rare differential diagnosis of a soft tissue tumor of the foot. [Article in German] *Unfallchirurg* 2000;103:479-81.
7. Mahmood A, Caccamo DV, Morgan JK. Tenosynovial giant-cell tumor of the cervical spine. Case report. *J Neurosurg* 1992;77:952-5.
8. Gibbons CL, Khawaja HA, Cole AS, Cooke PH, Athanasou NA. Giant-cell tumour of the tendon sheath in the foot and ankle. *J Bone Joint Surg Br* 2002;84:1000-3.
9. Ozdemir HM, Yildiz Y, Yilmaz C, Saglik Y. Tumours of the foot and ankle: analysis of 196 cases. *J Foot Ankle Surg* 1997;36:403-8.
10. Vasconez HC, Nisanci M, Lee EY. Giant cell tumour of the flexor tendon sheath of the foot. *J Plast Reconstr Aesthet Surg* 2008;61:815-8.
11. Cotten A, Flipo RM, Chastanet P, Desvigne-Noulet MC, Duguesnoy B, Delcambre B. Pigmented villonodular synovitis of the hip: review of radiographic features in 58 patients. *Skeletal Radiol* 1995;24:1-6.
12. Chou LB, Ho YY, Malawer MM. Tumors of the foot and ankle: experience with 153 cases. *Foot Ankle Int* 2009;30:836-41.
13. Labs K, Perka C, Guski H. Diagnosis and therapy of nodular tenosynovitis of the tendon sheath - case presentation. [Article in German] *Z Rheumatol* 2002;61:300-5.
14. Wan JMC, Magarelli N, Peh WC, Guglielmi G, Shek TW. Imaging of giant cell tumour of the tendon sheath. *Radiol Med* 2010;115:141-51.
15. Al-Qattan MM. Giant cell tumors of tendon sheath: classification and recurrence rate. *J Hand Surg Br* 2001;26:72-5.
16. Martin RC 2nd, Osborne DL, Edwards MJ, Wrightson W, McMasters KM. Giant cell tumor of tendon sheath, tenosynovial giant cell tumor, and pigmented villonodular synovitis: defining the presentation, surgical therapy and recurrence. *Oncol Rep* 2000;7:413-9.
17. Segler CP. Irradiation as adjunctive treatment of diffuse pigmented villonodular synovitis of the foot and ankle prior to tumor surgical excision. *Med Hypotheses* 2003;61:229-30.