



Management of tennis elbow with topical glyceryl trinitrate

Raif ÖZDEN, Vedat URUÇ, Yunus DOĞRAMACI, Aydın KALACI, Erhan YENGİL

Department of Orthopedics and Traumatology, Mustafa Kemal University, Faculty of Medicine, Hatay, Turkey

Objective: The aim of this study was to evaluate the treatment results of the application of nitric oxide (NO) in the form of topical glyceryl trinitrate (GTN) for the treatment of lateral epicondylitis (LE).

Methods: The study included 40 patients with LE randomized into 2 equal groups. Selection criteria included the presence of pain, tenderness, and positive pain stimulating maneuvers. Glyceryl trinitrate patches were applied to the area of maximal tenderness once a day in the treatment group and placebo patches in the control group. Outcomes in terms of pain relief was assessed using the visual analog scale (VAS) and were evaluated according to the criteria of Verhaar et al. Excellent or good results were considered successful. Differences in VAS scores between the two groups were calculated using the Mann-Whitney U-test and the chi-square test was used to investigate distributions of categorical variables (sex, affected side) and good and excellent results among groups.

Results: There were no significant differences in any of the baseline clinical parameters between groups. At the 3rd week follow-up, there were statistically significant differences in the pain measured using VAS between groups (mean VAS score of the control and treatment groups were 6.45 and 3.15, respectively) ($p=0.001$). Patients in the GTN group and control group had lower VAS pain scores and reduced elbow pain at 3 weeks (3.15 vs 8.05 in the GTN and 6.45 vs 8.80 in the control group). In the control group, no patient had excellent or good results while 18 (90%) patients in treatment group reported successful treatment. There was statistically significant difference in the VAS measured at 6 months between groups (mean VAS score of the control and treatment groups were 4.85 and 0.70, respectively) ($p=0.001$).

Conclusion: The administration of NO directly over an area of tendinopathy through a GTN patch reduces pain and other symptoms in chronic LE.

Key words: Lateral epicondylitis; nitric oxide; topical glyceryl trinitrate.

Lateral epicondylitis (LE), also referred to as 'tennis elbow', is a common illness of the elbow and is reported in 1 to 3% of the general population.^[1] Prevalence increases between the ages of 30 and 60 years of age.^[2]

Manual job tasks have been associated with LE,

which is the most frequent cause of lateral elbow pain.^[3,4] However, a variety of situations can produce symptoms similar to LE.^[5,6] A carefully taken history and thorough physical examination is often satisfactory to make a diagnosis. Diagnostic imaging is usually requested when

Correspondence: Raif Özden, MD. Mustafa Kemal Üniversitesi Tıp Fakültesi, Ortopedi ve Travmatoloji Anabilim Dalı, Serinyol, Antakya, Hatay, Turkey.

Tel: +90 506 – 536 64 96 e-mail: raifozen@gmail.com

Submitted: November 23, 2012 **Accepted:** February 18, 2014

©2014 Turkish Association of Orthopaedics and Traumatology

Available online at
www.aott.org.tr

doi: 10.3944/AOTT.2014.3123

QR (Quick Response) Code



the clinical presentation is atypical or to confirm diagnosis in cases not responding to treatment. Information can be obtained during an ultrasound examination and should be considered before MRI.

Although diagnosis of this condition is simple and easy, treatment remains difficult. The dominant arm is generally affected. Nitric oxide (NO) appears to play a role in tendon healing following injury. In a rat Achilles tendon healing model, inhibition of NO synthases resulted in a decreased cross-sectional area and caused failure of the healing tendon.^[7] The addition of NO in another model improved tendon healing, suggesting the supplement of exogenous NO to an area of tendon damage may support tendon recovery.^[8] In chronic tendinopathies, treatment with the application of NO in the form of topical glyceryl trinitrate (GTN) at a rate of 1.25 mg per 24 hours has clinical evidence of decreased pain, increased tendon strength, improved functional measures and improved symptom resolution in Achilles tendinopathy^[9,10] and LE.^[11,12]

The aim of this study was to investigate the effect of GTN on pain relief and functional improvement for the treatment of LE.

Patients and methods

This study was approved by the local ethics committee and informed consent was obtained from all participants. Between 2009 and 2011, 55 cases were diagnosed with LE. Of these, 15 patients were excluded due to inconclusive diagnosis of LE or other various reasons, such as neurologic deficits, coexisting arthritis or arthralgia, and medial epicondylitis. The remaining 40 patients (28 males and 12 females; mean age: 43.2 years, range: 19 to 74 years) with LE were randomized into two equal groups and instructed to perform a standard tendon rehabilitation program. Selection criteria were based on the presence of tenderness, pain, and positive pain stimulating maneuvers due to their inclusion in other studies.^[13,14] Inclusion criteria were as follows; 1) continuous symptoms present for more than three months, 2) resisted wrist extension, 3) tenderness and pain over the lateral epicondyle, 4) positive tennis elbow pain test (Mill's sign) with pain in the lateral epicondyle when the elbow was actively moved from flexion to full extension with the forearm in the pronated position and the wrist in flexion,^[15] and 5) positive chair lift test with pain in the region of lateral epicondyle when a chair was lifted with one hand in a position with the forearm pronated and the wrist is in flexion.^[16] A testing system simulating the chair lift test has been observed to be reproducible and reliable.^[17] Patients with history of surgery for LE,

effusion of the elbow, radiculopathy from the cervical spine, entrapment of the ulnar nerve, periarticular fracture, infection, abnormal erythrocyte sedimentation rate or previous injections were excluded (Fig. 1).

The treatment group received GTN transdermal patches that delivered 1.25 mg GTN every 24 hours. The control group received placebo patches. GTN patches (Nitroderm® 5 mg; Novartis) were cut into four equal parts and applied to the area of maximal tenderness once a day. Placebo patches were applied in the same manner to the control group. Investigators and patients were blinded to which patch was given to the patient. Patches were worn until the symptoms subsided or the study ended (6 months). Patients were instructed to avoid precipitating and exacerbating activities.

Clinical history and physical examination were performed and patients were assessed using the visual analog scale (VAS). The VAS is a self-assessed measurement of pain scored on a scale from 0 to 10. Pre- and post-treatment findings were compared.

Grip strength was evaluated subjectively with the arm adducted, the elbow flexed to 90° and the forearm in the neutral rotation. The treatment outcomes according to the criteria of Verhaar et al.^[18] was defined as; 'excellent' (no pain, patient contented with the treatment result, no subjective loss of grip strength and no pain exacerbated by resisted dorsiflexion of the wrist), 'good' (symptoms considerably decreased, patient satisfied with the treatment outcome, occasional mild pain on the lateral epicondyle after heavy activities, no or slight subjective loss of grip power, and no pain aggravated by resisted dorsiflexion of the wrist), 'fair' (discomfort on the lateral epicondyle after strenuous activities but at a more tolerable than before treatment, patient satisfied or mod-

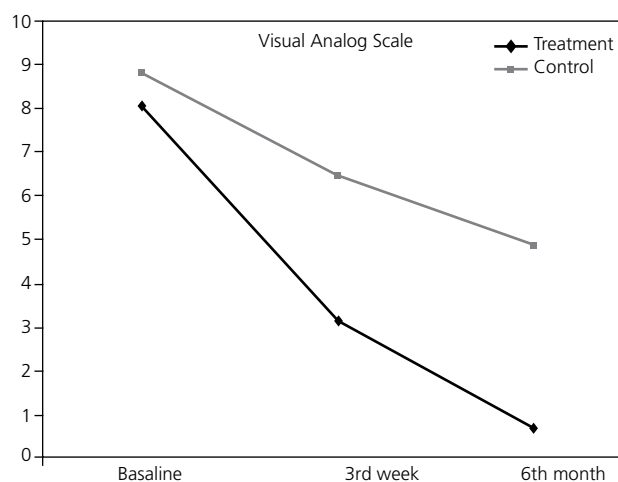


Fig. 1. Baseline, 3rd week and 6th month VAS scores.

erately satisfied with the outcome of treatment, slight or moderate subjective loss of grip strength, and slight or moderate pain provoked by resisted dorsiflexion of the wrist), or 'poor' (no decrease of pain of the lateral epicondyle, patient disappointed with the result of treatment, serious subjective loss of grip strength and severe pain exacerbated by resisted dorsiflexion of the wrist). Treatment was considered successful when the patient had an excellent or a good score.

The sample size was based on a power calculation that showed that 20 patients per group were necessary to achieve 80% power with $\alpha=0.05$. Data were analyzed using SPSS (SPSS Inc., Chicago, IL, USA) statistics software package. Differences in VAS scores between the two groups were calculated using the Mann-Whitney U-test. The chi-square test was used to investigate distributions of categorical variables (sex, affected side) and compare excellent and good results among groups. P values of <0.05 were considered statistically significant.

Results

The right hand was dominant in 32 (80%) patients. Lat-

eral epicondylitis was present in the dominant upper extremity in 36 (90%) patients. No significant differences with respect to sex, mean age, dominant extremity or duration of symptoms were observed at baseline between the two groups (Table 1). There were statistically significant differences in VAS scores between the treatment and control groups at the 3rd week follow-up (mean VAS scores were 6.45 and 3.15, respectively; $p=0.001$). Patients in both groups had significantly lower VAS scores and reduced elbow pain at 3 weeks (3.15 vs 8.05 in the GTN and 6.45 vs 8.80 in the control group). Outcomes for each group are shown in Fig. 2 and Table 2. No successful treatment (excellent, good) was reported in the control group. Successful treatment was reported by 18 (90%) patients in the treatment group (Table 3).

At the 6th month follow-up, VAS pain scores were 0.70 ± 1.30 in the treatment group and 4.85 ± 0.93 in the control group as compared to 8.05 ± 1.53 and 8.80 ± 1.28 , respectively, before treatment. There was a statistically significant difference in the 6th month VAS scores between the groups ($p=0.001$). Successful treatment was reported by 19 (95%) patients in the treatment group

Table 1. Baseline characteristics of subjects in two groups.

| Demographic details | Control group | Treatment group | p |
|---------------------------------------|-------------------------|-------------------------|--------------------|
| Sex (male/female) | 15/5 | 13/7 | 0.490* |
| Affected side (left/right) | 5/15 | 3/17 | 0.429* |
| Mean age \pm SD (range) (year) | 43.5 \pm 11.0 (25-74) | 42.9 \pm 10.2 (19-63) | 0.776 [†] |
| Duration of symptoms \pm SD (month) | 5.3 \pm 1.0 | 65.0 \pm 2.1 | 0.493 [†] |

*: Chi-square test. †: Mann-Whitney U-test.

Table 2. Pain in the affected side on VAS [mean \pm SD (range)].

| Groups | Baseline | 3 weeks | 6 months |
|-----------------|------------------------|-----------------------|-----------------------|
| Control group | 8.80 \pm 1.28 (5-10) | 6.45 \pm 0.75 (5-8) | 4.85 \pm 0.93 (3-6) |
| Treatment group | 8.05 \pm 1.53 (5-10) | 3.15 \pm 1.53 (1-8) | 0.70 \pm 1.30 (0-5) |
| | $p=0.107^*$ | $p=0.001^*$ | $p=0.001^*$ |

*: Mann-Whitney U-test.

Table 3. Pain relief outcomes at 3 weeks and 6 months according to Verhaar et al.'s^[18] criteria.

| | Excellent | | Good | | Fair | | Poor | |
|-----------------|-----------|----|------|----|------|----|------|----|
| | n | % | n | % | n | % | n | % |
| Control group | | | | | | | | |
| 3 weeks | 0 | | 0 | | 2 | 10 | 18 | 90 |
| 6 month | 0 | | 3 | 15 | 10 | 50 | 7 | 35 |
| Treatment group | | | | | | | | |
| 3 weeks | 2 | 10 | 16 | 80 | 1 | 5 | 1 | 5 |
| 6 month | 13 | 65 | 6 | 30 | 0 | | 1 | 5 |

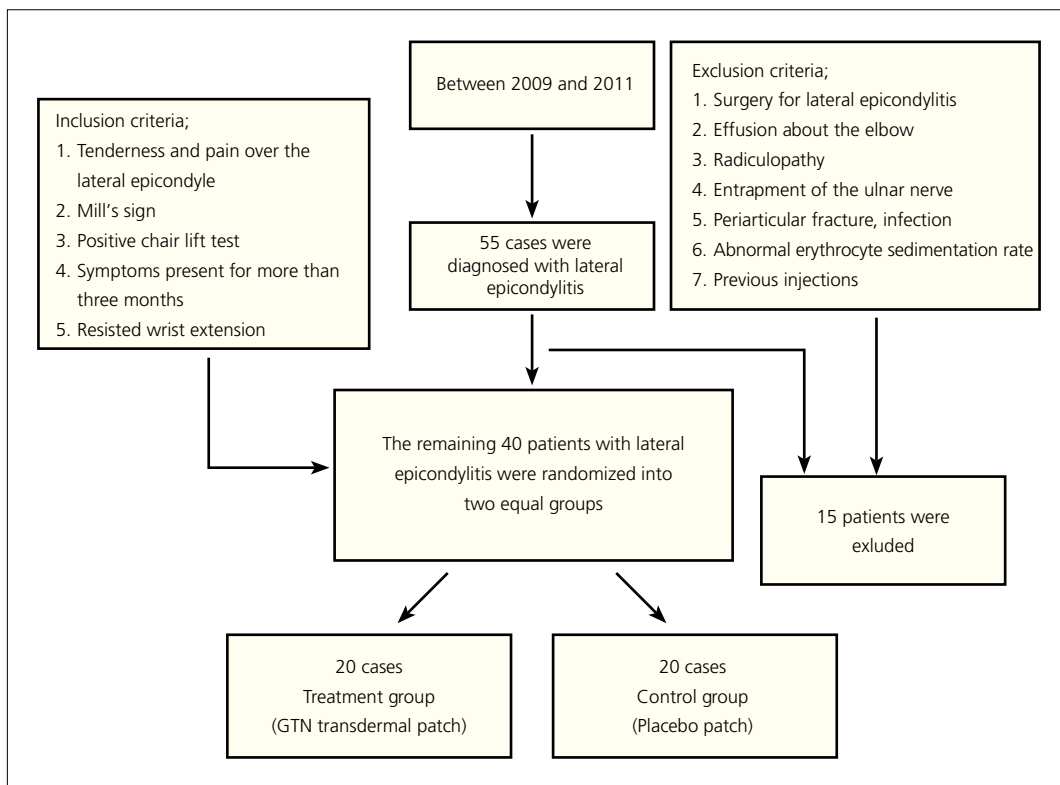


Fig. 2. Flow chart of showing number of patients and patient selection criteria.

and 3 (15%) in the control group.

Two patients in the control group and one patient in the treatment group were affected by headache. Patients were headache free one week after the study completed and no patient needed to terminate the treatment due to headache.

Discussion

Diagnosis of LE is made clinically through physical examination and history. However, a thorough understanding of the differential diagnosis is essential to avoid unnecessary testing and therapy. Magnetic resonance imaging is frequently unnecessary and will often show increased signal intensity near the common extensor origin and adjacent soft tissues. It may be useful if concomitant intra-articular pathology is suspected.^[19] Lateral epicondylitis is generally believed to be caused by cyclic mechanical loading of the elbow while using a powerful hand grip leading to an overuse injury of the extensor tendons' insertion. The pathogenesis is believed to be cumulative microtrauma exceeding the tissue's capacity for repair.^[20,21]

Glyceryl trinitrate patches are considered a good treatment option for LE, due to their reported effec-

tiveness in well-controlled studies, with minimal or no morbidity. In a randomized controlled trial of 86 patients comparing GTN transdermal and placebo patches,^[22] the GTN patch reduced elbow pain with activity at 2 weeks, reduced epicondylar sensitivity at 6 and 12 weeks, and improved wrist extensor mean peak force at 24 weeks. At 6 months, 81 percent of the treated patients were asymptomatic during activities of daily living. In a randomized double-blind, placebo-controlled clinical trial, Paoloni et al.^[9] investigated the use of topical NO in the treatment of Achilles tendinitis and reported that the NO group performed significantly better on hop testing and could generate more peak force at Week 24. In all, 78% of patients receiving GTN patches were asymptomatic for activities in their daily life at 6 months compared with 49% of patients with tendon rehabilitation alone. In another randomized, double-blinded, placebo-controlled clinical trial, Paoloni et al.^[23] showed that the NO group had significantly reduced shoulder pain with exercise at night and improved range of motion in abduction, forward flexion and external rotation, and improved power in abduction and external rotation. The changes in supraspinatus power were the most dramatic, and were significant at 6 weeks. Of the patients receiving GTN patches, 46% were asymptomatic for

daily activities at 6 months compared with 24% of patients with tendon rehabilitation alone.

In the present study, our two groups exhibited improvement. This supports previous studies showing that NO delivery via a patch enhances clinical recovery of tendinopathy in humans through a reduction of pain and increases range of motion and strength. An additional randomized controlled trial reported that a watchful-waiting approach was comparable with physical therapy and superior to corticosteroid injection in alleviating patients' main complaint at 1 year.^[24] The treatment of tennis elbow with GTN reduces pain more rapidly. In the present study, there was statistically significant difference in VAS scores between groups at 6 months. Together, these studies supply convincing evidence that the administration of NO directly over an area of tendinopathy in the form of a GTN patch enhances healing and provides some pain relief in the treatment of tendinopathy.

Studies on animal models have shown that intratendinous corticosteroid application adversely affected the biomechanical properties of tendons.^[25,26] This may be the most beneficial effect of NO use compared to steroid injections. Krogh et al.^[27] reported that neither injection of platelet-rich plasma nor glucocorticoid was superior to saline with regard to pain reduction in LE at the primary end point at 3 months. However, they reported that the administration of glucocorticoid had a short-term pain-reducing effect at 1 month in contrast to the other therapies. Injection of glucocorticoid in the LE reduces both color Doppler ultrasound activity and tendon thickness compared with platelet-rich plasma and saline. Bisset et al. demonstrated that a multimodal physiotherapy program was superior to wait-and-see in the short-term period.^[28]

The present study had some limitations, including the lack of muscle strength evaluation, MRI and ultrasonographic findings. Biomechanical measures (pain-free grip strength, rate of force development) have the potential to be used as outcome measures to monitor progress in LE. In comparison, imaging measures (MRI and ultrasound) are useful in visualizing the pathophysiology of LE. However, as the severity of the pathophysiology is not related to pain and function, imaging measures may not provide the best clinical assessment.

In conclusion, GTN patches appear to offer benefits in the treatment of LE. Application of topical NO improved functional outcomes and treatment results in terms of pain relief in patients with LE.

Conflicts of Interest: No conflicts declared.

References

1. De Smedt T, de Jong A, Van Leemput W, Lieven D, Van Glabbeek F. Lateral epicondylitis in tennis: update on aetiology, biomechanics and treatment. *Br J Sports Med* 2007;41:816-9. [CrossRef](#)
2. Rayan F, Rao V Sr, Purushothamdas S, Mukundan C, Shafqat SO. Common extensor origin release in recalcitrant lateral epicondylitis - role justified? *J Orthop Surg Res* 2010;5:31. [CrossRef](#)
3. Haahr JP, Andersen JH. Physical and psychosocial risk factors for lateral epicondylitis: a population based case-referent study. *Occup Environ Med* 2003;60:322-9. [CrossRef](#)
4. Faro F, Wolf JM. Lateral epicondylitis: review and current concepts. *J Hand Surg Am* 2007;32:1271-9. [CrossRef](#)
5. Walz DM, Newman JS, Konin GP, Ross G. Epicondylitis: pathogenesis, imaging, and treatment. *Radiographics* 2010;30:167-84. [CrossRef](#)
6. Van Hofwegen C, Baker CL 3rd, Baker CL Jr. Epicondylitis in the athlete's elbow. *Clin Sports Med* 2010;29:577-97.
7. Murrell GA, Szabo C, Hannafin JA, Jang D, Dolan MM, Deng XH, et al. Modulation of tendon healing by nitric oxide. *Inflamm Res* 1997;46:19-27. [CrossRef](#)
8. Yuan J, Murrell GA, Wei AQ, Appleyard RC, Del Soldato P, Wang MX. Addition of nitric oxide via nitroflurbiprofen enhances the material properties of early healing of young rat Achilles tendons. *Inflamm Res* 2003;52:230-7.
9. Paoloni JA, Appleyard RC, Nelson J, Murrell GA. Topical glyceryl trinitrate treatment of chronic noninsertional achilles tendinopathy. A randomized, double-blind, placebo-controlled trial. *J Bone Joint Surg Am* 2004;86-A:916-22.
10. Paoloni JA, Murrell GA. Three-year followup study of topical glyceryl trinitrate treatment of chronic noninsertional Achilles tendinopathy. *Foot Ankle Int* 2007;28:1064-8.
11. McCallum SD, Paoloni JA, Murrell GA. Five-year prospective comparison study of topical glyceryl trinitrate treatment of chronic lateral epicondylitis at the elbow. *Br J Sports Med* 2011;45:416-20. [CrossRef](#)
12. Paoloni JA, Murrell GA, Burch RM, Ang RY. Randomised, double-blind, placebo-controlled clinical trial of a new topical glyceryl trinitrate patch for chronic lateral epicondylitis. *Br J Sports Med* 2009;43:299-302. [CrossRef](#)
13. Sanford J, Moreland J, Swanson LR, Stratford PW, Gowland C. Reliability of the Fugl-Meyer assessment for testing motor performance in patients following stroke. *Phys Ther* 1993;73:447-54.
14. Svernlöv B, Adolfsson L. Non-operative treatment regime including eccentric training for lateral humeral epicondylalgia. *Scand J Med Sci Sports* 2001;11:328-34. [CrossRef](#)
15. Friedlander HL, Reid RL, Cape RF. Tennis elbow. *Clin Orthop Relat Res* 1967;51:109-16.
16. Gardner RC. Tennis elbow: diagnosis, pathology and

- treatment. Nine severe cases treated by a new reconstructive operation. *Clin Orthop Relat Res* 1970;72:248-53.
17. Paoloni JA, Appleyard RC, Murrell GA. The Orthopaedic Research Institute-Tennis Elbow Testing System: A modified chair pick-up test-interrater and intrarater reliability testing and validity for monitoring lateral epicondylitis. *J Shoulder Elbow Surg* 2004;13:72-7. [CrossRef](#)
 18. Verhaar J, Walenkamp G, Kester A, van Mameren H, van der Linden T. Lateral extensor release for tennis elbow. A prospective long-term follow-up study. *J Bone Joint Surg Am* 1993;75:1034-43.
 19. Tosti R, Jennings J, Sowards JM. Lateral epicondylitis of the elbow. *Am J Med* 2013;126:357.e1-6.
 20. Coonrad RW, Hooper WR. Tennis elbow: its course, natural history, conservative and surgical management. *J Bone Joint Surg Am* 1973;55:1177-82.
 21. Nirschl RP, Pettrone FA. Tennis elbow. The surgical treatment of lateral epicondylitis. *J Bone Joint Surg Am* 1979;61:832-9.
 22. Paoloni JA, Appleyard RC, Nelson J, Murrell GA. Topical nitric oxide application in the treatment of chronic extensor tendinosis at the elbow: a randomized, double-blinded, placebo-controlled clinical trial. *Am J Sports Med* 2003;31:915-20.
 23. Paoloni JA, Appleyard RC, Nelson J, Murrell GA. Topical glyceryl trinitrate application in the treatment of chronic supraspinatus tendinopathy: a randomized, double-blinded, placebo-controlled clinical trial. *Am J Sports Med* 2005;33:806-13. [CrossRef](#)
 24. Smidt N, van der Windt DA, Assendelft WJ, Devillé WL, Korthals-de Bos IB, Bouter LM. Corticosteroid injections, physiotherapy, or a wait-and-see policy for lateral epicondylitis: a randomised controlled trial. *Lancet* 2002;359:657-62. [CrossRef](#)
 25. Kapetanos G. The effect of the local corticosteroids on the healing and biomechanical properties of the partially injured tendon. *Clin Orthop Relat Res* 1982;163:170-9.
 26. Gottlieb NL, Riskin WG. Complications of local corticosteroid injections. *JAMA* 1980;243:1547-8. [CrossRef](#)
 27. Krogh TP, Fredberg U, Stengaard-Pedersen K, Christensen R, Jensen P, Ellingsen T. Treatment of lateral epicondylitis with platelet-rich plasma, glucocorticoid, or saline: a randomized, double-blind, placebo-controlled trial. *Am J Sports Med* 2013;41:625-35. [CrossRef](#)
 28. Bisset L, Beller E, Jull G, Brooks P, Darnell R, Vicenzino B. Mobilisation with movement and exercise, corticosteroid injection, or wait and see for tennis elbow: randomised trial. *BMJ* 2006;333:939. [CrossRef](#)