



Component alignment in total wrist arthroplasty: success rate of surgeons in their first cases

Montserrat OCAMPOS^{1,2}, Fernando CORELLA^{1,2}, Blanca del CAMPO¹, Maribel CARNICER¹

¹Hand Surgery Unit, Department of Orthopedics and Traumatology, Infanta Leonor University Hospital, Madrid, Spain;

²Department of Hand Surgery, Beata María Ana Hospital, Madrid, Spain

Objective: The aim of this study was to assess the probability of achieving a satisfactory alignment in the performance of a first wrist arthroplasty.

Methods: The total wrist arthroplasties (ReMotion®) of 14 wrists of 7 corpses performed by 14 inexperienced surgeons were reviewed radiologically. Radial component alignment in the posteroanterior view (RCA-PA), radial component alignment in the lateral view (RCA-Lat), carpal component alignment in the posteroanterior view (CCA-PA) and carpal component alignment in lateral view (CCA-Lat) were measured.

Results: Mean RCA-PA angle was 9.6°, mean RCA-Lat angle 4.6°, mean CCA-PA angle 4.4° and mean CCA-Lat angle 10.1°. None of the arthroplasties had a satisfactory alignment.

Conclusion: It is difficult for an inexperienced surgeon to achieve a correct component alignment in his/her first total wrist arthroplasty, especially in the carpal component. Therefore, we recommend that the position of the prosthesis is confirmed before securing it to the bone with the help of X-ray images.

Key words: Alignment; first wrist arthroplasty; inexperienced surgeon.

Despite being one of the first joints to be treated with prosthesis replacement, the evolution of the wrist arthroplasty has been slower than in other joints.^[1] The first designs using metal and polythene prostheses were related to a high rate of complications.^[2] The new generation prosthesis includes certain aspects that improve the clinical results: distal component fixation, intercarpal arthrodesis, increase of the distal screw fixation, minimum bone resection, fixation by osseous integration and ellipsoidal and semi-constrained joints.^[3] The ReMotion® prosthesis (Small Bone Innovations Inc., Morrisville, PA, USA) includes these special features.^[4]

However, design improvements are useless if the surgical technique is not appropriate and satisfactory prosthetic alignment is not achieved.^[5-7] The achievement of correct alignment can be technically difficult, especially for inexperienced surgeons.

The aim of this research was to assess the probability of achieving a satisfactory alignment in the performance of a first wrist arthroplasty.

Materials and methods

Seven corpses with previous bilateral total wrist arthroplasty (ReMotion®) performed by inexperienced sur-

Correspondence: Montserrat Ocampos, MD. Department of Hand Surgery, Infanta Leonor University Hospital C/ Gran Vía del Este, 80 28031 Madrid, Spain.

Tel: (+34-63) 539 7746 e-mail: montse.ocampos@gmail.com

Submitted: August 22, 2012 **Accepted:** February 07, 2014

©2014 Turkish Association of Orthopaedics and Traumatology

Available online at
www.aott.org.tr
doi: 10.3944/AOTT.2014.3017
QR (Quick Response) Code



geons during the '1st Advanced Course in Orthopedic Surgery: Wrist Arthroscopy and Arthroplasty' (Spain, June 2011) were reviewed. The 14 wrist arthroplasties were performed for the first time by the 14 surgeons who attended the course. Radiological examination consisted of 4 measurements to determine the prosthesis rod alignment with regard to the reference bone elements (Fig. 1). The radial component alignment in posteroanterior view (RCA-PA) was measured as the angle between the axial line of the radial diaphysis and the axial line of the radial component rod in the wrist posteroanterior view. The radial component alignment in lateral view (RCA-Lat) was measured as the angle between the axial line of the radial diaphysis and the axial line of the radial component rod in the wrist lateral view. The carpal component alignment in posteroanterior view (CCA-PA) was measured as the angle between the axial line of the third metacarpal diaphysis and the axial line of the carpal component rod on the hand posteroanterior view. Finally, the carpal component alignment in lateral view (CCA-Lat) was the angle between the axial line of the third metacarpal diaphysis and the axial line of the carpal component rod on the hand lateral view.

The graphic design program AutoCAD® (Autodesk

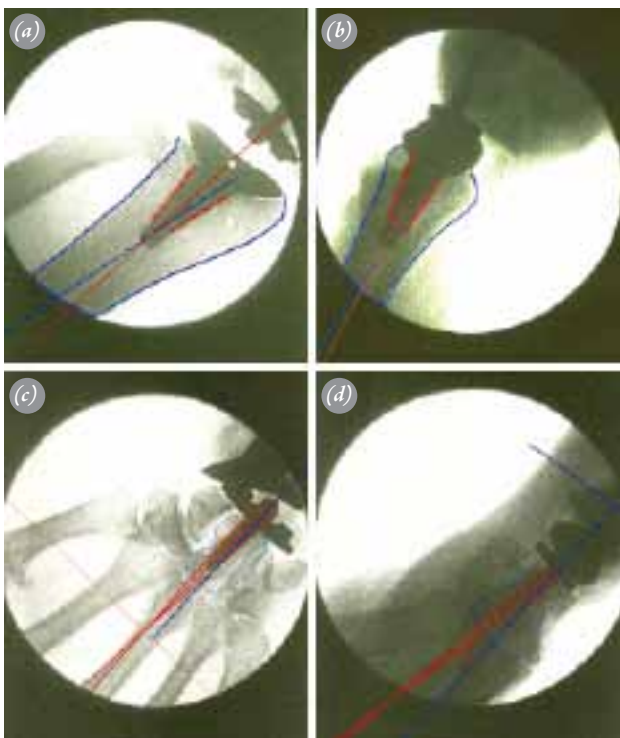


Fig. 1. (a) Radial component alignment in posteroanterior view (RCA-PA). (b) Radial component alignment in lateral view (RCA-Lat). (c) Carpal component alignment in posteroanterior view (CCA-PA). (d) Carpal component alignment in lateral view (CCA-Lat). [Color figure can be viewed in the online issue, which is available at www.aott.org.tr]

Table 1. Angles of the seven wrist arthroplasties.

	RCA-PA	RCA-Lat	CCA-PA	CCA-Lat
1	6	4	3	10
2	6	5	4	6
3	12	7	12	21
4	11	7	3	6
5	14	2	2	16
6	8	2	3	10
7	10	5	4	2
	9.6	4.6	4.4	10.1

Inc., Mill Valley, CA, USA) was used for all measurements.

Results

All measurement results are given in Table 1.

Mean RCA-PA angle was 9.6° (range: 6° - 14°) and mean RCA-Lat angle was 4.6° (range: 2° - 7°).

Mean CCA-PA angle was 4.4° (range: 2° - 12°) and mean CCA-Lat was 10.1° (mean: 2° - 21°).

None of the arthroplasties assessed achieved correct alignment. In some, the malalignment was of great importance (Fig. 2). The worst alignments were observed in the lateral view of the carpal component.

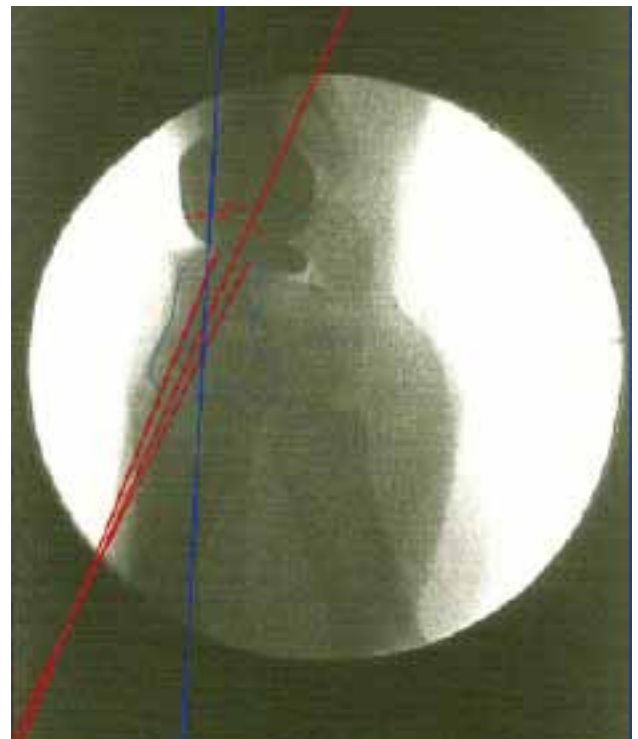


Fig. 2. 21° incorrect alignment of the carpal component with regard to the third metacarpal. [Color figure can be viewed in the online issue, which is available at www.aott.org.tr]

Discussion

In this study, no wrist arthroplasties achieved proper alignment, demonstrating the difficulty in achieving a correct component alignment during the performance of an inexperienced surgeon's first total wrist arthroplasty.

Unlike knee arthroplasty, in which several investigations on cadaveric human specimen have been developed to check alignment,^[8,9] studies have not been performed on total wrist arthroplasty.

Several authors have reported on the link between malalignment of components in a wrist arthroplasty and implant failure. In a paper reviewing 88 wrist arthroplasties, Lorei et al. reported 9 revisions, two of which were due to an incorrect positioning of components.^[6] Meuli found malalignment of the carpal component in 8 cases of 40 arthroplasties, 6 with loosening signs that required surgery revision.^[7] Finally, Cooney et al. reported malalignment to be one of the causes of implant failure in total wrist arthroplasty.^[5]

No consensus has been formed on the acceptable limit of angular deviation or the most important plane of malposition of the component. Takwale et al.^[10] studied various factors such as age, gender, staging of the disease and the radioulnar angulation of the component and did not find any significant effect on revision rates. However, the authors determined that for each degree a component was placed in extension in the lateral plane, there was a 17% increase in the risk that revision would be required. Figgie et al. reported that the positioning of the implant in the radioulnar plane in trispherical total wrist arthroplasty was of relatively minor statistical importance in predicting component shift compared with restoration of the carpal height and placement of center of rotation (COR) volar to the radius medullary canal axis.^[11] Meuli and Volz implicated positioning of the implant center of rotation in the radial ulnar plane as a major contributory factor in the failure.^[12,13] However, differences may be related to differences in implant design and surgical techniques.

New generation prostheses have shown promising results in short-term prospective studies and low rates of complication.^[4,8] However, correct component alignment is essential. This correct alignment is difficult to achieve, especially by inexperienced surgeons, as can be seen from our study results.

In conclusion, it is difficult for an inexperienced surgeon to achieve correct component alignment in his/her first total wrist arthroplasty, especially in the carpal component. Therefore, we highly recommend that the position of the prosthesis is checked with the help of X-ray images before securing it to the bone.

Conflicts of Interest: No conflicts declared.

References

1. Adams BD. Total wrist arthroplasty. *Orthopedics* 2004;27:278-84.
2. Adams BD. Complications of wrist arthroplasty. *Hand Clin* 2010;26:213-20. [CrossRef](#)
3. Anderson MC, Adams BD. Total wrist arthroplasty. *Hand Clin* 2005;21:621-30. [CrossRef](#)
4. Gupta A. Total wrist arthroplasty. *Am J Orthop (Belle Mead NJ)* 2008;37(8 Suppl 1):12-6.
5. Cooney WP 3rd, Beckenbaugh RD, Linscheid RL. Total wrist arthroplasty. Problems with implant failures. *Clin Orthop Relat Res* 1984;187:121-8.
6. Lorei MP, Figgie MP, Ranawat CS, Inglis AE. Failed total wrist arthroplasty. Analysis of failures and results of operative management. *Clin Orthop Relat Res* 1997;342:84-93. [CrossRef](#)
7. Meuli HC. Total wrist arthroplasty. Experience with a noncemented wrist prosthesis. *Clin Orthop Relat Res* 1997;342:77-83. [CrossRef](#)
8. Garvin KL, Barrera A, Mahoney CR, Hartman CW, Haider H. Total knee arthroplasty with a computer-navigated saw: a pilot study. *Clin Orthop Relat Res* 2013;471:155-61. [CrossRef](#)
9. Nam D, Jerabek SA, Cross MB, Mayman DJ. Cadaveric analysis of an accelerometer-based portable navigation device for distal femoral cutting block alignment in total knee arthroplasty. *Comput Aided Surg* 2012;17:205-10.
10. Takwale VJ, Nuttall D, Trail IA, Stanley JK. Biaxial total wrist replacement in patients with rheumatoid arthritis. Clinical review, survivorship and radiological analysis. *J Bone Joint Surg Br* 2002;84:692-9. [CrossRef](#)
11. Figgie HE 3rd, Inglis AE, Straub LR, Ranawat CS. A critical analysis of alignment factors influencing functional results following trispherical total wrist arthroplasty. *J Arthroplasty* 1986;1:149-56. [CrossRef](#)
12. Meuli HC. Meuli total wrist arthroplasty. *Clin Orthop Relat Res* 1984;187:107-11.
13. Volz RG. Total wrist arthroplasty. A clinical review. *Clin Orthop Relat Res* 1984;187:112-20.