



Treatment of superior labrum anterior posterior lesions: a literature review

Gazi HURI, Yoon Suk HYUN, Nickolas G. GARBIS, Edward G. McFARLAND

Department of Orthopedic Surgery, The Johns Hopkins University, Baltimore, Maryland, United States

Objective: Treatment of superior labrum anterior posterior (SLAP) lesions continues to be controversial, but with the development of suture anchors, it has become acceptable to repair these lesions arthroscopically. The aim of this study was to review recent trends in the evaluation and treatment of SLAP lesions, with particular emphasis on comparing the results of biceps tenodesis and SLAP repair.

Methods: All English language publications from the PubMed, Cochrane, and SCOPUS databases between 1928 and 2012 on biceps tendon, SLAP lesions, and biceps surgery were reviewed. Literature was reviewed in table form because of the lack of Level 1 studies.

Results: Surgical repair can have complications and may not return overhead athletes to their previous level of activity. Biceps tenodesis has become the preferred primary procedure in non-athletic individuals because of the high failure rate of SLAP repair. In patients with continuing symptoms after SLAP lesion repair, biceps tenodesis offers a more predictable operation than a second repair attempt.

Conclusion: Biceps tenodesis may present a viable treatment option for SLAP repair or for failed SLAP repair in some patients.

Key words: Biceps; pain; shoulder; SLAP; treatment.

Superior glenoid labral tears involving the long head of the biceps were initially described in 1985 by Andrews et al.,^[1] who noted an association between the tearing of the labrum and throwing athletes. In 1990, Snyder et al.^[2] published a description of these injuries as superior labrum anterior posterior (SLAP) lesions and proposed a classification system that divided them into 4 subtypes on the basis of the amount of damage to or destabilization of the biceps anchor. The Snyder classification system (Fig. 1) is commonly used by clinicians for the evaluation and treatment of these lesions. Subsequently, Maffet et al.^[3] described 3 additional types of SLAP tears in 1995. The classification has since been expanded to 10 distinct types of SLAP tears in the literature (Table 1).^[4]

The prevalence, associated abnormal findings, and clinical features of the different types of SLAP lesions vary with the patient population.^[5] Type 1 lesions are typically associated with rotator cuff disease and are generally not known to create any clinical symptoms. Type 3 and 4 lesions have been found to be associated with traumatic instability.^[5] The clinical features of Type 2 lesions differ according to the patient's age. Type 2 lesions in patients over 40 years of age have clinical features similar to those of Type 1 lesions, probably in part because of concomitant lesions in the shoulder. Type 2 lesions in patients less than 40 years old have clinical features that are closer to those of Type 3 and 4 lesions in that they can produce pain and clicking.

Correspondence: Edward McFARLAND, MD, c/o Elaine P. HENZE, BJ, ELS, Medical Editor and Director, Editorial Services, Department of Orthopedic Surgery, The Johns Hopkins University/Johns Hopkins Bayview Medical Center, 4940 Eastern Ave., #A665 Baltimore, MD 21224-2780, USA.

Tel: (+1-410) 550 5400 e-mail: ehenze1@jhmi.edu

Submitted: January 25, 2013 **Accepted:** October 01, 2013

©2014 Turkish Association of Orthopaedics and Traumatology

Available online at

www.aott.org.tr

doi: 10.3944/AOTT.2014.3169

QR (Quick Response) Code



As shoulder arthroscopy led to a better understanding of these lesions, surgical repair became more popular. Early techniques such as the use of metal or absorbable tacks have evolved to suture anchors and advanced arthroscopic instrumentation, establishing surgical repair as the accepted treatment for SLAP lesions. However, it has become apparent that the clinical results of SLAP repair can be compromised by complications and that the ability to return to sport may not be as high as previously believed. As a result, there has been increasing interest in the role of biceps tenodesis for the treatment of symptoms believed to be secondary to SLAP lesions.

The aim of this study was to review recent trends in the evaluation and treatment of SLAP lesions with particular emphasis on comparing the results of biceps tenodesis and SLAP repair. All English language publications from the PubMed, Cochrane, and SCOPUS databases between 1928^[6] and 2012^[7-13] on biceps tendon, SLAP lesions, and biceps surgery were reviewed. All SLAP lesion studies presented the results of Type 2 lesion repair and 2^[14,15] also included Type 3 and Type 4 lesion repair. We excluded 3^[16-18] of the 11 biceps tenodesis articles as they described the results of tenodesis secondary to degeneration or tendinitis. Finally, a meta-analysis or systematic review was not performed and the

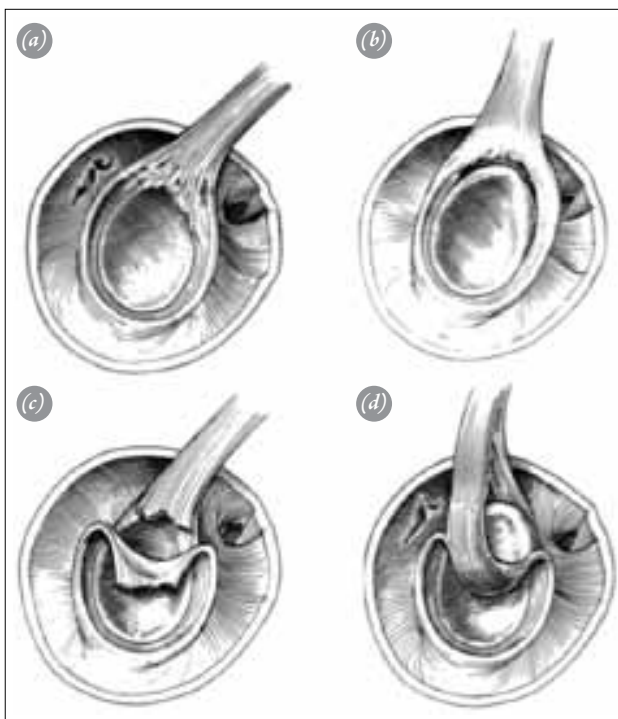


Fig. 1. Artist's illustration of the Snyder classification of SLAP tears. **(a)** Type 1 SLAP lesion. **(b)** Type 2 SLAP lesion. **(c)** Type 3 SLAP lesion. **(d)** Type 4 SLAP lesion. (Reprinted with permission from: Snyder SJ, Karzel RP, Del Pizzo W, Ferkel RD, Friedman MJ. SLAP lesions of the shoulder. *Arthroscopy* 1990;6:274-9).

Table 1. Definition of the types of SLAP lesions.^[4]

Type	Definition
Type 1	Fraying or tear of SL with intact BT
Type 2	SL tear and BT stripping
Type 3	Bucket-handle tear of SL and intact BT
Type 4	Bucket-handle tear of SL and extension of tear to BT
Type 5	Bankart lesion, SL tear, and BT stripping
Type 6	Anterior/posterior flap tear and BT stripping
Type 7	SL tear, BT stripping, and middle glenohumeral ligament tear
Type 8	SL tear and posteroinferior labral tear
Type 9	SL tear with extensive anterior and posterior extension
Type 10	SL tear with extension to the rotator interval or to the structures that cross the rotator interval

BT: biceps tendon; SL: superior labrum.

28 studies were reviewed in table form due to the lack of Level 1 studies.

Physical examination of superior labrum anterior posterior lesions

The use of history and physical examination in the diagnosis of SLAP lesions continues to be difficult. For several reasons, history alone does not typically provide sufficient evidence for diagnosis.^[1,5,19,20] Studies have shown that SLAP lesions can be caused by a variety of mechanisms, including acute trauma (e.g., falls on an outstretched arm) and insidious processes (e.g., overhead activity such as throwing). The pain pattern produced by a SLAP lesion is likewise non-specific, although pain in the posterior and superior glenoid is common in patients with SLAP tears. Unfortunately, posterior shoulder pain can also be indicative of shoulder stiffness. Additionally, isolated SLAP lesions are uncommon, and many patients have other coexisting abnormalities. As a result, it is common for patients with SLAP lesions who have rotator cuff abnormality to have pain in the anterior and lateral shoulder or anteriorly in the area of the biceps tendon.

Several sources have reported difficulty in the physical examination of the shoulder for SLAP lesions.^[9,21,22] There are several reasons for this difficulty. First, the labrum only rarely produces clicking or catching in the shoulder, similar to meniscus in the knee. Although one study found a 5% incidence of a click on examination of patients with SLAP lesions, this rate was no different in the control group without SLAP lesions.^[23] Second, coexisting abnormalities can complicate the physical examination. Because it is difficult to find a cohort of patients with isolated SLAP lesions and no other abnormalities,

most studies of the examination for SLAP lesions cannot ascribe a positive test only to a SLAP lesion. Third, no one physical finding has been found to be specific to SLAP lesions. Many physical examination tests for SLAP lesions have been described,^[21,23,24] including the active compression test,^[25] anterior slide test,^[26] biceps load test,^[27] crank test,^[28] biceps load test 2,^[29] and the dynamic shear test.^[30] However, most analyses have confirmed that their clinical usefulness is limited by their low specificity and moderate sensitivity.^[9,31] As a result, no one single test or combination of tests will reliably make the diagnosis.

However, a more recent test has shown promise for the diagnosis of a SLAP lesion: the dynamic shear test.^[32] This test is performed with the patient in the standing position and the examiner alongside the extremity to be tested (Fig. 2). The patient's elbow is passively flexed to 90° with the shoulder abducted in the scapular plane to more than 120° by the examiner. The patient's shoulder is externally rotated to tightness, and the arm is guided into maximum horizontal abduction. The examiner then imparts an anteriorly directed shear load to the joint via lowering the arm from approximately 120° to 60° of abduction. A positive test is indicated by the reproduction of pain and/or painful click or catch between the motion of 120° and 60° of abduction. Kibler et al.^[32] suggested a likelihood ratio of 30 for SLAP, making it highly diagnostic for SLAP lesions. However, Cook et al.^[7] found that the dynamic shear test was not clinically useful in diagnosing SLAP lesions.

Most experts agree that diagnostic arthroscopy is

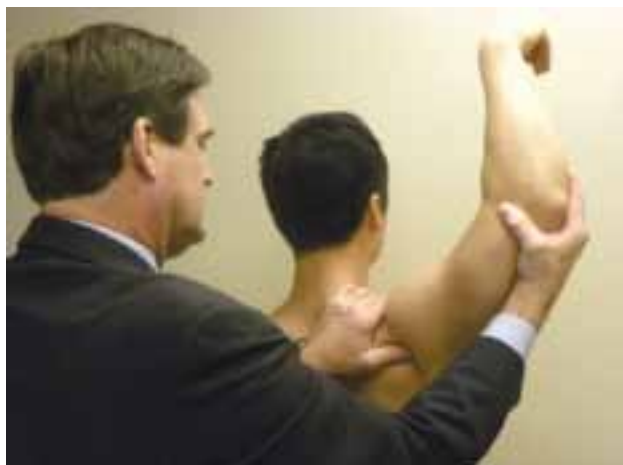

Fig. 2. The dynamic shear test is performed with the patient standing and the arm placed through an arc of 80° to 120° while the examiner places an anteriorly directed force on the shoulder. A positive test is pain in the shoulder, especially in a posterior and superior direction. [Color figure can be viewed in the online issue, which is available at www.aott.org.tr]

the most accurate way to reach a diagnosis of SLAP lesion.^[33-37] There have been several studies indicating that disagreement among observers on the exact grade of the SLAP lesion is possible, even with arthroscopy.^[25,26,38,39] However, a recent study by Jia et al.^[40] found that experienced shoulder surgeons have high agreement on the classification of the SLAP lesion. Despite this finding, 2 studies found that despite the agreement on the type of SLAP lesion, there is little uniformity on how they should be treated.^[10,41]

Surgical results

The primary indication for surgical treatment of SLAP lesions is the failure of non-operative treatment and persistent symptoms that prevent sports activities or activities of daily living. Traditional surgical treatment of SLAP lesions consists of repairing the biceps anchor back to the superior glenoid rim with suture anchors.^[42,43] Initial reports suggested that the success rate was high in terms of pain relief and return to sport (Table 2).^[8,12,14,15,42,44-58] Morgan et al.^[54] published the 1-year outcomes of repair in 102 Type 2 lesions. They reported good to excellent results according to the University of California Los Angeles Shoulder Score in 97% of patients, and 84% (37 of 44) of overhead athletes returned to pre-injury activities. Samani et al.^[56] reported a success rate of 88% using an absorbable tack to repair Type 2 SLAP lesions, even in athletes with high demands and expectations. Kim et al.^[53] reported a satisfaction rate of 94% after SLAP lesion repair but noticed significantly less favorable results after isolated repairs in patients who participated in overhead sports than in those who did not. In another study, only 16 of 31 patients treated with a trans-rotator cuff approach returned to their pre-injury level of sports, a 74% of satisfaction rate.^[55] Similarly, Brockmeier et al.^[45] reported a mean American Shoulder and Elbow Surgeons score of 92.6 in an athletic population in which only 74% returned to pre-injury level. Kartus et al.^[51] encouraged the use of one double-looped Corkscrew anchor for Type 2 SLAP repairs. The authors reported significant improvements ($p < 0.05$) in activities of daily living compared with the preoperative assessments. Ide et al.^[42] reported the longest previous follow-up (mean: 41 months; range: 24 to 58 months) of arthroscopic suture anchor repair of Type 2 SLAP lesions. A good or excellent outcome was reported in 90% of their 41 patients, and 75% of the patients returned to pre-injury activities. Schröder et al.^[12] compared the long-term results after SLAP repair in patients more than and less than 40 years of age (mean follow-up: 5.3 years; range: 4 to 8 years). Regardless of the age of their

Table 2. Studies in the literature on SLAP repairs.

Study	Study Type	Number of Patients	Mean Age (years)	Follow-up Time (months)	Treatment	ASES Score (points)	UCLA Shoulder Score (points)	Satisfaction (%)	L'Insalata Score (points)
Yoneda et al. ^[57] (1991)	R	10	17.8	37.4	Repair (staple)	N/A	N/A	80	N/A
Morgan et al. ^[54] (1998)	R	102	N/A	12	Repair	N/A	N/A	97	N/A
Samani et al. ^[56] (2001)	R	25	36	35	Repair	92	32	88	N/A
Kim et al. ^[53] (2002)	R	34	26	33	Repair	N/A	Overhead: 32.6; non-overhead: 34.3	94	N/A
O'Brien et al. ^[55] (2002)	R	31	39	44.4	Repair	87.2	N/A	74	87
Kartus et al. ^[51] (2004)*	P	15	36	25	Repair	N/A	N/A	N/A	N/A
Ide et al. ^[42] (2005)	R	40	24	41	Repair	N/A	N/A	90	N/A
Rhee et al. ^[15] (2005)	R	41	24	33	Repair	N/A	32.3	86	N/A
Cohen et al. ^[46] (2006)	R	39	34	44	Repair	86.8	N/A	71	86.7
Paxinos et al. ^[14] (2006)	P	24	36	25.2	Repair	N/A	N/A	91	N/A
Coleman et al. ^[47] (2007)	R	50	31.6	29.1	A: repair B: repair + acromioplasty	A: 85.8 B: 86.5	N/A N/A	A: 65 B: 81	A: 87.1 B: 85.1
Enad et al. ^[48] (2007)	R	36 (A: 18 isolated; B: 18 associated injury)	31.6	A: 29.1 B: 29.8	Repair	A: 84.1 B: 91.8	A: 30.2 B: 30.8	94 (both)	N/A
Franceschi et al. ^[50] (2008)	P	63	>50	62.4	31 (repair) 32 (tenot)	N/A N/A	27.9 (repair) 32.1 (tenot)	3.4 (repair) 4.6 (tenot)	N/A
Yung et al. ^[58] (2008)	P	16	24.2	27.6	Repair	N/A	31.3±3.7	87.5	N/A
Brockmeier et al. ^[45] (2009)	P	47	36	32.4	Repair	97	N/A	90	93
Katz et al. ^[52] (2009)	R	40	43	N/A	Repair	N/A	N/A	29	N/A
Alpert et al. ^[44] (2010)	R	52	55 (>40) 33 (<40)	28	Repair	86 (>40) 93 (<40)	N/A N/A	84 (>40) 95 (<40)	N/A N/A
Friel et al. ^[49] (2010)	P	48	33.1	40.8	Repair	83.3	30.9	79	N/A
Denard et al. ^[8] (2012)	R	55	37.9	77	Repair	86.2	31.2	87	N/A
Schröder et al. ^[12] (2012)	P	107	43.8	63.6	Repair	N/A	N/A	88	N/A

N/A: not available; ASES: American Shoulder and Elbow Surgeons, P: prospective, R: retrospective, tenot: tenotomy, UCLA: University of California Los Angeles. *Constant score=83.

107 patients, they reported a satisfaction rate of excellent/good in 90 (88%) patients, with higher Rowe scores at 5 years. In contrast, Denard et al.^[8] found poor results (mean follow-up: 77 months; range: 37 to 104 months) after arthroscopic repair of Type 2 SLAP lesions in patients more than 40 years of age.

In general, more than 83% of patients were satisfied with the surgery, and 73% of patients could return to

their previous level of activity.^[11] These statistics led to the enthusiastic repair of these lesions with a myriad of techniques and anchors developed for this purpose.

However, over time, SLAP repairs were noticed to not be as successful as originally reported and were associated with postoperative stiffness, continued pain, and failure of the labrum to heal to the superior glenoid.^[59,60] Neri et al.^[60] evaluated 23 elite overhead athletes for

Table 3. Studies in the literature on biceps tenodesis.

Study	Number of Patients	Mean Age in Years (range)	Follow-up Time (months)	Rating Scale	Satisfaction (%)	Poor Outcome (%)	Excellent/Good Outcome (%)	Popeye Sign (%)
Boileau et al. ^[66] (2002)	43	N/A	N/A	Constant	90 (strength of other side)	4.6 (re-operated)	N/A	N/A
Osbahr et al. ^[71] (2002)	80	54 (23-76)	20 (3-50)	Pain	N/A	10	60	20
Checchia et al. ^[67] (2005)	15	71 (41-80)	32.4	UCLA	93.4	6.6	93	6
Franceschi et al. ^[69] (2007)	22	60.3 (41-79)	47.2	UCLA	100	0	100	No
Drakos et al. ^[68] (2008)	40	38.5 (15-67)	28	ASES, UCLA, L'Insalata	80	5	92	5
Boileau et al. ^[59] (2009)	15	52 (19-57)	34	Constant	93	N/A	93	N/A
Koh et al. ^[70] (2010)	43	65 (55-77)	27	ASES, Constant	84	5	84	9
Schöffl et al. ^[65] (2011)	6	36 (28-50)	24	Constant	96.8	0	N/A	No

N/A: not available; ASES: American Shoulder and Elbow Surgeons Score, UCLA: University of California Los Angeles Shoulder Score.

more than 1 year after arthroscopic repair of their Type 2 SLAP lesions. The authors emphasized that almost half of the patients were able to return to their pre-injury level of competition. Similarly, Boileau et al.^[59] compared the outcome of Type 2 SLAP repair (10 patients) with that of biceps tenodesis (15 patients) in a Level 3 cohort study. Although the Constant score in both groups increased after surgery (65 to 83 in the SLAP repair group compared with 59 to 89 in the biceps tenodesis group), the percentage of satisfied patients in the tenodesis group was much higher (87%) than that in the repair group (40%). In addition, the percentage of patients returning to their previous level of sports was higher in the tenodesis group (87%) than in the SLAP repair group (20%).

Postoperative stiffness after SLAP repair has been found to have a variety of causes. In repair of the anterior and superior labrum, tightening of the middle glenohumeral ligament can occur, particularly in cases in which a sublabral hole was also repaired. This tightening has been shown to decrease external rotation, especially with the arm at the side.^[61,62] Another cause of stiffness is the prolonged immobilization needed to allow healing of the labrum. Rehabilitation protocols for patients after SLAP repair often include immobilization of the shoulder for 3 to 4 weeks or longer to protect the repair, and this length of immobilization can result in global loss of motion and stiffness.

Continued pain after SLAP repair is difficult to assess because of the variety of potential causes. The usual cause of postoperative pain is shoulder stiffness, although lack of healing of the labrum is also possible. Several studies have suggested that the healing rate of a SLAP repair is only 70% to 80%.^[5,42,61] It is also possible that a particular surgery did not adequately address the other coexistent abnormalities, such as partial- or full-thickness rotator cuff tears. In addition, as acromioclavicular joint pain can be mistaken for SLAP lesion pain,^[63] patients for whom repair of a SLAP lesion has failed should be carefully assessed for other abnormalities. Unfortunately, physical examination or magnetic resonance imaging may not localize the cause of the pain after a failed SLAP repair. Diagnostic injection of local anesthetic into the joint, subacromial space or acromioclavicular joint may help isolate the source of the pain, but this modality has not been adequately studied to provide sound clinical guidelines as its effectiveness. These variables can lead to a situation in which the only remaining option is to re-operate to determine the cause of the continued pain.

Because of the high failure rate of SLAP repairs,

there is an increasing appreciation that biceps tenodesis or tenotomy may be an acceptable treatment for SLAP lesions. In addition, this technique has now become the preferred treatment for failed SLAP repairs.^[64]

In general, the results following biceps tenodesis for various abnormalities of the biceps tendon have been favorable, with good pain relief in 11.7% to 87% of patients and satisfaction rates of 93% to 96.8% (Table 3).^[16-18,59,65-71]

The indications for biceps tenodesis as the index procedure for a symptomatic SLAP lesion depend on the patients' age, activity level, arm dominance, and type of sport. It is commonly recommended that SLAP lesions in athletic individuals who are involved in overhead sports such as tennis, baseball, team handball, or volleyball be repaired. In older individuals who are laborers or who have concomitant rotator cuff tears, tenodesis or tenotomy is the treatment of choice. The age at which one would consider tenodesis or tenotomy over repair in athletic individuals is controversial. Although there is no consensus on what age should be the cut-off for repair versus tenodesis, 4 studies have suggested that SLAP repair should not be considered in individuals over the age of 40.^[8,13,50,72]

Summary

The evaluation and treatment of SLAP lesions of the shoulder continues to be controversial. Physical examination is generally inexact and cannot reliably confirm the diagnosis of a SLAP lesion, although the dynamic shear test has shown some promise in making the diagnosis. Surgical repair of a SLAP lesion with a grade higher than Type 1 has been shown to be less successful than initially reported, and dissatisfaction with the results has led to an increased use of biceps tenotomy or tenodesis as the initial treatment, especially in the older individual with rotator cuff disease. The role of biceps tenodesis or tenotomy in the overhead athlete is controversial, and the use of SLAP repair in this population remains uncertain.

Conflicts of Interest: No conflicts declared.

References

1. Andrews JR, Carson WG Jr, McLeod WD. Glenoid labrum tears related to the long head of the biceps. *Am J Sports Med* 1985;13:337-41. [CrossRef](#)
2. Snyder SJ, Karzel RP, Del Pizzo W, Ferkel RD, Friedman MJ. SLAP lesions of the shoulder. *Arthroscopy* 1990;6:274-9. [CrossRef](#)
3. Maffet MW, Gartsman GM, Moseley B. Superior la-

- brum-biceps tendon complex lesions of the shoulder. *Am J Sports Med* 1995;23:93-8. [CrossRef](#)
4. Modarresi S, Motamedi D, Jude CM. Superior labral anteroposterior lesions of the shoulder: part 2, mechanisms and classification. *AJR Am J Roentgenol* 2011;197:604-11. [CrossRef](#)
 5. Kim TK, Queale WS, Cosgarea AJ, McFarland EG. Clinical features of the different types of SLAP lesions: an analysis of one hundred and thirty-nine cases. *J Bone Joint Surg Am* 2003;85-A:66-71.
 6. Meyer AW. Spontaneous dislocation and destruction of the tendon of the long head of the biceps brachii: fifty-nine instances. *Arch Surg* 1928;17:493-506. [CrossRef](#)
 7. Cook C, Beaty S, Kissenberth MJ, Siffri P, Pill SG, Hawkins RJ. Diagnostic accuracy of five orthopedic clinical tests for diagnosis of superior labrum anterior posterior (SLAP) lesions. *J Shoulder Elbow Surg* 2012;21:13-22. [CrossRef](#)
 8. Denard PJ, Lädermann A, Burkhart SS. Long-term outcome after arthroscopic repair of type II SLAP lesions: results according to age and workers' compensation status. *Arthroscopy* 2012;28:451-7. [CrossRef](#)
 9. Hegedus EJ, Goode AP, Cook CE, Michener L, Myer CA, Myer DM, et al. Which physical examination tests provide clinicians with the most value when examining the shoulder? Update of a systematic review with meta-analysis of individual tests. *Br J Sports Med* 2012;46:964-78. [CrossRef](#)
 10. Khazzam M, George MS, Churchill RS, Kuhn JE. Disorders of the long head of biceps tendon. *J Shoulder Elbow Surg* 2012;21:136-45. [CrossRef](#)
 11. Sayde WM, Cohen SB, Ciccotti MG, Dodson CC. Return to play after Type II superior labral anterior-posterior lesion repairs in athletes: a systematic review. *Clin Orthop Relat Res* 2012;470:1595-600. [CrossRef](#)
 12. Schröder CP, Skare O, Gjengedal E, Uppheim G, Reikerås O, Brox JI. Long-term results after SLAP repair: a 5-year follow-up study of 107 patients with comparison of patients aged over and under 40 years. *Arthroscopy* 2012;28:1601-7. [CrossRef](#)
 13. Weber SC, Martin DF, Seiler JG 3rd, Harrast JJ. Superior labrum anterior and posterior lesions of the shoulder: incidence rates, complications, and outcomes as reported by American Board of Orthopedic Surgery. Part II candidates. *Am J Sports Med* 2012;40:1538-43. [CrossRef](#)
 14. Paxinos A, Walton J, Rütten S, Müller M, Murrell GAC. Arthroscopic stabilization of superior labral (SLAP) tears with biodegradable tack: outcomes to 2 years. *Arthroscopy* 2006;22:627-34. [CrossRef](#)
 15. Rhee YG, Lee DH, Lim CT. Unstable isolated SLAP lesion: clinical presentation and outcome of arthroscopic fixation. *Arthroscopy* 2005;21:1099. [CrossRef](#)
 16. Becker DA, Cofield RH. Tenodesis of the long head of the biceps brachii for chronic bicipital tendinitis. Long-term results. *J Bone Joint Surg Am* 1989;71:376-81.
 17. Berlemann U, Bayley I. Tenodesis of the long head of biceps brachii in the painful shoulder: improving results in the long term. *J Shoulder Elbow Surg* 1995;4:429-35.
 18. Mazzocca AD, Cote MP, Arciero CL, Romeo AA, Arciero RA. Clinical outcomes after subpectoral biceps tenodesis with an interference screw. *Am J Sports Med* 2008;36:1922-9. [CrossRef](#)
 19. Snyder SJ, Banas MP, Karzel RP. An analysis of 140 injuries to the superior glenoid labrum. *J Shoulder Elbow Surg* 1995;4:243-8. [CrossRef](#)
 20. Resch H, Golser K, Thoeni H, Sperner G. Arthroscopic repair of superior glenoid labral detachment (the SLAP lesion). *J Shoulder Elbow Surg* 1993;2:147-55. [CrossRef](#)
 21. McFarland EG. Examination of the biceps tendon and superior labrum anterior and posterior (SLAP) lesions. In: Kim TK, Park HB, El Rassi G, et al, editors. *Examination of the shoulder: the complete guide*. New York: Thieme; 2006. p. 213-43.
 22. McFarland EG, Kim TK, Savino RM. Clinical assessment of three common tests for superior labral anterior-posterior lesions. *Am J Sports Med* 2002;30:810-5.
 23. Guanche CA, Jones DC. Clinical testing for tears of the glenoid labrum. *Arthroscopy* 2003;19:517-23. [CrossRef](#)
 24. Tennent TD, Beach WR, Meyers JF. A review of the special tests associated with shoulder examination. Part II: laxity, instability, and superior labral anterior and posterior (SLAP) lesions. *Am J Sports Med* 2003;31:301-7.
 25. O'Brien SJ, Pagnani MJ, Fealy S, McGlynn SR, Wilson JB. The active compression test: a new and effective test for diagnosing labral tears and acromioclavicular joint abnormality. *Am J Sports Med* 1998;26:610-3.
 26. Kibler WB. Specificity and sensitivity of the anterior slide test in throwing athletes with superior glenoid labral tears. *Arthroscopy* 1995;11:296-300. [CrossRef](#)
 27. Kim SH, Ha KI, Han KY. Biceps load test: a clinical test for superior labrum anterior and posterior lesions in shoulders with recurrent anterior dislocations. *Am J Sports Med* 1999;27:300-3.
 28. Liu SH, Henry MH, Nuccion SL. A prospective evaluation of a new physical examination in predicting glenoid labral tears. *Am J Sports Med* 1996;24:721-5. [CrossRef](#)
 29. Kim SH, Ha KI, Ahn JH, Kim SH, Choi HJ. Biceps load test II: A clinical test for SLAP lesions of the shoulder. *Arthroscopy* 2001;17:160-4. [CrossRef](#)
 30. Cheung EV, O'Driscoll SW. The dynamic labral shear test for superior labral anterior posterior tears of the shoulder. Podium presentation at the 76th Annual Meeting of the American Academy of Orthopaedic Surgeons, San Diego (CA), February 14-17, 2007.
 31. Oh JH, Kim JY, Kim WS, Gong HS, Lee JH. The evaluation of various physical examinations for the diagnosis of type II superior labrum anterior and posterior lesion. *Am*

- J Sports Med 2008;36:353-9. [CrossRef](#)
32. Ben Kibler W, Sciascia AD, Hester P, Dome D, Jacobs C. Clinical utility of traditional and new tests in the diagnosis of biceps tendon injuries and superior labrum anterior and posterior lesions in the shoulder. *Am J Sports Med* 2009;37:1840-7. [CrossRef](#)
 33. Burkhart SS, Morgan C. SLAP lesions in the overhead athlete. *Orthop Clin North Am* 2001;32:431-41. [CrossRef](#)
 34. Burkhart SS, Morgan CD, Kibler WB. The disabled throwing shoulder: spectrum of pathology. Part II: evaluation and treatment of SLAP lesions in throwers. *Arthroscopy* 2003;19:531-9. [CrossRef](#)
 35. Holtby R, Razmjou H. Accuracy of the Speed's and Yergason's tests in detecting biceps pathology and SLAP lesions: comparison with arthroscopic findings. *Arthroscopy* 2004;20:231-6. [CrossRef](#)
 36. Nakagawa S, Yoneda M, Hayashida K, Obata M, Fukushima S, Miyazaki Y. Forced shoulder abduction and elbow flexion test: a new simple clinical test to detect superior labral injury in the throwing shoulder. *Arthroscopy* 2005;21:1290-5. [CrossRef](#)
 37. Nam EK, Snyder SJ. The diagnosis and treatment of superior labrum, anterior and posterior (SLAP) lesions. *Am J Sports Med* 2003;31:798-810.
 38. Myers TH, Zemanovic JR, Andrews JR. The resisted supination external rotation test: a new test for the diagnosis of superior labral anterior posterior lesions. *Am J Sports Med* 2005;33:1315-20. [CrossRef](#)
 39. Parentis MA, Glousman RE, Mohr KS, Yocum LA. An evaluation of the provocative tests for superior labral anterior posterior lesions. *Am J Sports Med* 2006;34:265-8.
 40. Jia X, Yokota A, McCarty EC, Nicholson GP, Weber SC, McMahan PJ, et al. Reproducibility and reliability of the Snyder classification of superior labral anterior posterior lesions among shoulder surgeons. *Am J Sports Med* 2011;39:986-91. [CrossRef](#)
 41. Gobeze R, Zurakowski D, Lavery K, Millett PJ, Cole BJ, Warner JJP. Analysis of interobserver and intraobserver variability in the diagnosis and treatment of SLAP tears using the Snyder classification. *Am J Sports Med* 2008;36:1373-9. [CrossRef](#)
 42. Ide J, Maeda S, Takagi K. Sports activity after arthroscopic superior labral repair using suture anchors in overhead-throwing athletes. *Am J Sports Med* 2005;33:507-14.
 43. Kartus J, Perko M. Arthroscopic repair of a type II SLAP lesion using a single corkscrew anchor. *Arthroscopy* 2002;18:E10. [CrossRef](#)
 44. Alpert JM, Wuerz TH, O'Donnell TFX, Carroll KM, Brucker NN, Gill TJ. The effect of age on the outcomes of arthroscopic repair of type II superior labral anterior and posterior lesions. *Am J Sports Med* 2010;38:2299-303.
 45. Brockmeier SF, Voos JE, Williams RJ 3rd, Altchek DW, Cordasco FA, Allen AA. Outcomes after arthroscopic repair of type-II SLAP lesions. *J Bone Joint Surg Am* 2009;91:1595-603. [CrossRef](#)
 46. Cohen DB, Coleman S, Drakos MC, Allen AA, O'Brien SJ, Altchek DW, et al. Outcomes of isolated type II SLAP lesions treated with arthroscopic fixation using a bioabsorbable tack. *Arthroscopy* 2006;22:136-42. [CrossRef](#)
 47. Coleman SH, Cohen DB, Drakos MC, Allen AA, Williams RJ, O'Brien SJ, et al. Arthroscopic repair of type II superior labral anterior posterior lesions with and without acromioplasty: a clinical analysis of 50 patients. *Am J Sports Med* 2007;35:749-53. [CrossRef](#)
 48. Enad JG, Kurtz CA. Isolated and combined Type II SLAP repairs in a military population. *Knee Surg Sports Traumatol Arthrosc* 2007;15:1382-9. [CrossRef](#)
 49. Friel NA, Karas V, Slabaugh MA, Cole BJ. Outcomes of type II superior labrum, anterior to posterior (SLAP) repair: prospective evaluation at a minimum two-year follow-up. *J Shoulder Elbow Surg* 2010;19:859-67. [CrossRef](#)
 50. Franceschi F, Longo UG, Ruzzini L, Rizzello G, Maffulli N, Denaro V. No advantages in repairing a type II superior labrum anterior and posterior (SLAP) lesion when associated with rotator cuff repair in patients over age 50: a randomized controlled trial. *Am J Sports Med* 2008;36:247-53. [CrossRef](#)
 51. Kartus J, Kartus C, Brownlow H, Burrow G, Perko M. Repair of type-2 SLAP lesions using Corkscrew anchors. A preliminary report of the clinical results. *Knee Surg Sports Traumatol Arthrosc* 2004;12:229-34. [CrossRef](#)
 52. Katz LM, Hsu S, Miller SL, Richmond JC, Khetia E, Kohli N, et al. Poor outcomes after SLAP repair: descriptive analysis and prognosis. *Arthroscopy* 2009;25:849-55.
 53. Kim SH, Ha KI, Kim SH, Choi HJ. Results of arthroscopic treatment of superior labral lesions. *J Bone Joint Surg Am* 2002;84:981-5.
 54. Morgan CD, Burkhart SS, Palmeri M, Gillespie M. Type II SLAP lesions: three subtypes and their relationships to superior instability and rotator cuff tears. *Arthroscopy* 1998;14:553-65. [CrossRef](#)
 55. O'Brien SJ, Allen AA, Coleman SH, Drakos MC. The trans-rotator cuff approach to SLAP lesions: technical aspects for repair and a clinical follow-up of 31 patients at a minimum of 2 years. *Arthroscopy* 2002;18:372-7. [CrossRef](#)
 56. Samani JE, Marston SB, Buss DD. Arthroscopic stabilization of type II SLAP lesions using an absorbable tack. *Arthroscopy* 2001;17:19-24. [CrossRef](#)
 57. Yoneda M, Hirooka A, Saito S, Yamamoto T, Ochi T, Shinno K. Arthroscopic stapling for detached superior glenoid labrum. *J Bone Joint Surg Br* 1991;73:746-50.
 58. Yung PSH, Fong DTP, Kong MF, Lo CK, Fung KY, Ho EPY, et al. Arthroscopic repair of isolated type II superior labrum anterior-posterior lesion. *Knee Surg Sports Traumatol Arthrosc* 2008;16:1151-7. [CrossRef](#)
 59. Boileau P, Parratte S, Chuinard C, Roussanne Y, Shia D,

- Bicknell R. Arthroscopic treatment of isolated type II SLAP lesions: biceps tenodesis as an alternative to reinsertion. *Am J Sports Med* 2009;37:929-36. [CrossRef](#)
60. Neri BR, ElAttrache NS, Owsley KC, Mohr K, Yocum LA. Outcome of type II superior labral anterior posterior repairs in elite overhead athletes: Effect of concomitant partial-thickness rotator cuff tears. *Am J Sports Med* 2011;39:114-20. [CrossRef](#)
61. Branch TP, Lawton RL, Iobst CA, Hutton WC. The role of glenohumeral capsular ligaments in internal and external rotation of the humerus. *Am J Sports Med* 1995;23:632-7. [CrossRef](#)
62. Kuhn JE, Huston LJ, Soslowsky LJ, Shyr Y, Blasler RB. External rotation of the glenohumeral joint: ligament restraints and muscle effects in the neutral and abducted positions. *J Shoulder Elbow Surg* 2005;14(1 Suppl S):39S-48S. [CrossRef](#)
63. Berg EE, Ciullo JV. A clinical test for superior glenoid labral or 'SLAP' lesions. *Clin J Sport Med* 1998;8:121-3.
64. Weber SC. Surgical management of the failed SLAP repair. *Sports Med Arthrosc* 2010;18:162-6. [CrossRef](#)
65. Schöffl V, Popp D, Dickschass J, Küpper T. Superior labral anterior-posterior lesions in rock climbers-primary double tenodesis? *Clin J Sport Med* 2011;21:261-3. [CrossRef](#)
66. Boileau P, Krishnan SG, Coste JS, Walch G. Arthroscopic biceps tenodesis: a new technique using bioabsorbable interference screw fixation. *Arthroscopy* 2002;18:1002-12.
67. Checchia SL, Doneux PS, Miyazaki AN, Silva LA, Fregoneze M, Ossada A, et al. Biceps tenodesis associated with arthroscopic repair of rotator cuff tears. *J Shoulder Elbow Surg* 2005;14:138-44. [CrossRef](#)
68. Drakos MC, Verma NN, Gulotta LV, Potucek F, Taylor S, Fealy S, et al. Arthroscopic transfer of the long head of the biceps tendon: functional outcome and clinical results. *Arthroscopy* 2008;24:217-23. [CrossRef](#)
69. Franceschi F, Longo UG, Ruzzini L, Papalia R, Rizzello G, Denaro V. To detach the long head of the biceps tendon after tenodesis or not: outcome analysis at the 4-year follow-up of two different techniques. *Int Orthop* 2007;31:537-45. [CrossRef](#)
70. Koh KH, Ahn JH, Kim SM, Yoo JC. Treatment of biceps tendon lesions in the setting of rotator cuff tears: prospective cohort study of tenotomy versus tenodesis. *Am J Sports Med* 2010;38:1584-90. [CrossRef](#)
71. Osbahr DC, Diamond AB, Speer KP. The cosmetic appearance of the biceps muscle after long-head tenotomy versus tenodesis. *Arthroscopy* 2002;18:483-7. [CrossRef](#)
72. Burns JP, Bahk M, Snyder SJ. Superior labral tears: repair versus biceps tenodesis. *J Shoulder Elbow Surg* 2011;20(2 Suppl):S2-8. [CrossRef](#)