



Reduction and arthrodesis with sublaminar spiral silk in atlantoaxial joint instability

Kadir KOTIL¹, Mustafa Gökhan BILGILI², Selim KAYACI³

¹Department of Physiotherapy and Rehabilitation, School of Health Sciences, Istanbul Arel University, Istanbul, Turkey;

²Department of Orthopedics and Traumatology, Bakırköy Dr. Sadi Konuk Training and Research Hospital, Istanbul, Turkey;

³Department of Neurosurgery, Faculty of Medicine, Recep Tayyip Erdoğan University, Rize, Turkey

Objective: The aim of this study was to evaluate the clinical and radiologic results of the use of thick spiral silk knotting instead of sublaminar wiring for C1-C2 arthrodesis in patients with atlantoaxial instability.

Methods: We retrospectively evaluated 16 patients (10 females, 6 males; mean age: 43.4 years; mean follow-up: 34 months) with atlantoaxial instability who underwent C1-C2 fusion by reduction and sublaminar spiral silk knotting. All patients underwent open reduction, bounding both laminae with thick spiral silk instead of wiring and arthrodesis with autografting. Reduction rates, screw position and fusion rates were evaluated using computed tomography.

Results: Preoperative mean atlantodental interval (ADI) was 8 (range: 6 to 11) mm and postoperative ADI was 2.1 (range: 0.5 to 2.5) mm. There was no dural or spinal cord injury. Complete reduction was observed in all cases. Fusion was unsuccessful in 1 case (6.25%). Postoperative mean flexion ADI was 10 mm and mean extension ADI was 1 mm. Graft separation between C1-C2 was observed in slice tomographic examination in one patient. Malposition was observed in 2 screws (4%).

Conclusion: The sublaminar silk knotting technique appears to provide safe anatomical reduction. As this method is cheap and simple and does not require extra implantation, loosen, create neurologic compromise or cause radiologic crowding, it can be considered an alternative surgical technique to sublaminar wiring.

Key words: Atlantoaxial stabilization; cervical spine; interlaminar fusion.

Atlantoaxial joint (AAJ) instability may occur due to degenerative joint disease, rheumatologic diseases, infectious reasons, os odontoideum, tumors or trauma.

[1] Regardless of etiology, reduction can be provided by several different techniques in case of disrupted integrity of the atlas and axis. Posterior open reduction is the preferred method except in cases that are irreducible or that require circumferential decompression. If posterior

decompression and reduction is not successful, anterior transoral surgery should be performed.[1] The C1-C2 transarticular screwing stabilization technique is used in AAJ instability cases which cannot be treated by anterior odontoid screw.[2,3] The C1-C2 dislocation must be reduced and anatomic alignment should be provided before application of the transarticular screw (Magerl) technique to avoid neurovascular complications.[4-6]

Correspondence: Kadir Kotil, MD, Prof. İstanbul Arel Üniv. Sağlık Bilimleri Yüksekokulu, Fizyoterapi ve Rehabilitasyon Bölümü, Tepekent 34537 Büyükçekmece, İstanbul, Turkey.

Tel: +90 212 – 867 25 00 e-mail: kadirkotil@arel.edu.tr

Submitted: January 06, 2013 **Accepted:** February 28, 2014

©2014 Turkish Association of Orthopaedics and Traumatology

Available online at

www.aott.org.tr

doi: 10.3944/AOTT.2014.3156

QR (Quick Response) Code



There are many different techniques for reduction and fusion, without standardization. Surgeons who believe the advantages of sublaminar wiring and autografting prefer to use the Sonntag technique to increase fusion.^[6-8] Fusion with sublaminar wiring technique was defined for the first time by Gallie in 1939.^[9] Sublaminar wiring provides reduction and settlement of the fusion material. However, many publications have reported loosening of wires in time with this technique, eventually leading to neurological damages.^[5,10-13] Different modifications of this technique were defined by Brooks, Sonntag, Magerl and Harms.^[3] Wires can wear the lamina over time, particularly when performed in children.^[14] Although soft and titanium wires appear to solve this problem, their application is more difficult and expensive. In order to prevent neurological damage, some surgeons prefer unrestricted graft application or tightening of the graft material between the C1-C2 lamina after decortication.^[4] However, the main disadvantage of this technique is pseudarthrosis.^[2]

The aim of this study was to report the results of a sublaminar spiral silk technique to eliminate the wire-related complications.

Patients and methods

We retrospectively evaluated 16 patients (10 females, 6 males; mean age: 43.4 years, range: 10 to 61 years) treated with C1-C2 fixation for AAJ instability between 2006 and 2012 by a single surgeon (KK). Neurological conditions, radiological examination, operation notes and follow-up period were noted. Mean follow-up time was 34 (range: 27 to 45) months. Third plan, thin slice tomographic analysis was performed preoperatively to determine the dominant vertebral artery and cases with a highly corrugated vertebral artery. A string was formed by winding three no. 2 silks to each other. Silk was pre-

ferred due to its endurance to tension and better knotting power when compared to other suture materials. The neurological status of the patients was evaluated using the Nurick scale. A Philadelphia collar was used for 6 weeks postoperatively. Patients were assessed clinically and radiologically in the 1st week and at the 3rd, 6th, 12th, 24th and 60th months.

All patients were evaluated by preoperative and postoperative plain radiographs, open mouth dens views, dynamic X-ray views, computed tomography (CT) and magnetic resonance image (MRI). Atlantodental interval (ADI) of 5 mm or higher was accepted as instability. Preoperative ADI values were measured by a blinded radiologist and compared with the postoperative values. Retro-odontoid tumor-like pannus formation was observed in 2 cases. There was no contrast enhancement in these two cases. Because of poor bone quality, augmentation was achieved with pedicle screws reaching to the middle of the cervical region. Patients were evaluated using CT in the early postoperative period and at the 6th month follow-up. Reduction values of the odontoid migrations in basilar invagination were assessed postoperatively. Values were in the physiological limits in all patients. Iliac crest autograft was used in all patients and fusion occurred in all but one (93.8%). Inappropriate positioning was seen in 2 (4%) screws but revision was not required.

Operations were performed using the dorsal approach with the patient in the military posture in a prone position. The C1-C2 complex was exposed. The head was placed into a Mayfield helmet with spinous processes positioned longitudinally on the same midline. In cases with a deeply seated C2, thoracic kyphosis was corrected and brought to the neutral position because of angulation problems in screw director and insufficient anterior tubercle fixation. A skin incision was

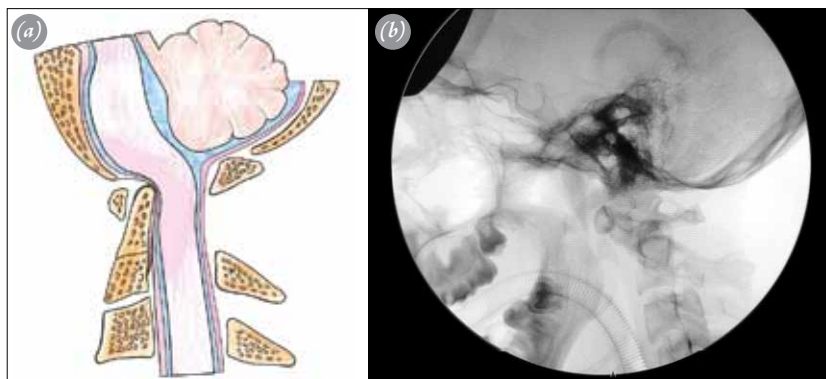

Fig. 1. (a) Compression of the spinal cord with scissoring effect at the dislocation site. (b) Radiography of AAD showing widened interspinous interval of C1-C2. [Color figure can be viewed in the online issue, which is available at www.aott.org.tr]

made between the inion and C3 and muscles were dissected subperiosteally. Dissection was continued to the transverse foramen of the atlas and inferior part of the C3 without disrupting the C2-C3 facet joint capsule. Monopolar cautery was preferred since high temperature might damage bones and soft tissues. The C2 was dissected to feel the isthmus and arcus depth and the direction of the screw was properly assessed. Dislocation between C1 and C2 was reduced by extension of the lower cervical spine and the flexion of the inion. Surgical challenges associated with the dislocation were the deep location of C1's lamina, the compression of spinal cord by C1's lamina and the highly-localized C2. The spinal cord was compressed due to the shearing effect of dislocation (Fig. 1). The C2 lamina was pressed and the joint reduced. The surrounding soft tissue around the C1 and C2 lamina was dissected using a 360-degree-angled dissector. The silk string was placed in the sublaminar region (Fig. 2a) and knotted over both laminae to provide anatomic reduction by passing through the C1 and C2 laminae (Figs. 2b and c). The posterior facet of both laminae was decorticated before knotting. Reduction was checked using fluoroscopy (Fig. 3a). The transarticular screw was positioned and controlled using fluoroscopy; an iliac crest autograft was placed on the prepared site and the second knot was tied on the graft (Fig. 3b). Autograft bone chips were used in order to increase fusion.

Results

The most frequent symptom in our series was neck pain, which occurred in 15 cases (93.8%). Spastic quadriplegia occurred in 4 (25%) cases. These four cases were ambulatory using walking aids. Clinical findings and postoperative assessment results are summarized in Table 1. Neck pain at different levels and restriction in neck movements were observed in all patients. In rheumatoid arthritis patients, there was generalized cervical muscle spasm. None of our cases had neurological deterioration during their follow-ups. There was os odontoideum in 6 cases (37.5%), Type 2 dens fracture in 5 (31.3%), rheumatoid arthritis in 4 (25%) and previous Type 2 dens fracture in one (6.3%).

Complications were grouped in two; early and late. There was one early non-dominant vertebral artery minor injury in which bleeding was easily tamponed and stopped using hemostatic agents. Late complications included delayed fusion (in the 15th month) in two cases with rheumatoid arthritis and insufficiency of the C1-C2 bone bridge in these two cases, and pseudarthrosis in one rheumatoid arthritis patient. None of these patients were smokers.

Reduction was complete in all cases. Mean preoperative and postoperative ADI values were 8 (range: 6 to 11) mm and 2.1 (range: 0.5 to 2.5) mm, respectively. No dural or spinal cord injury complications were observed. Mean flexion ADI value was 10 mm and mean extension

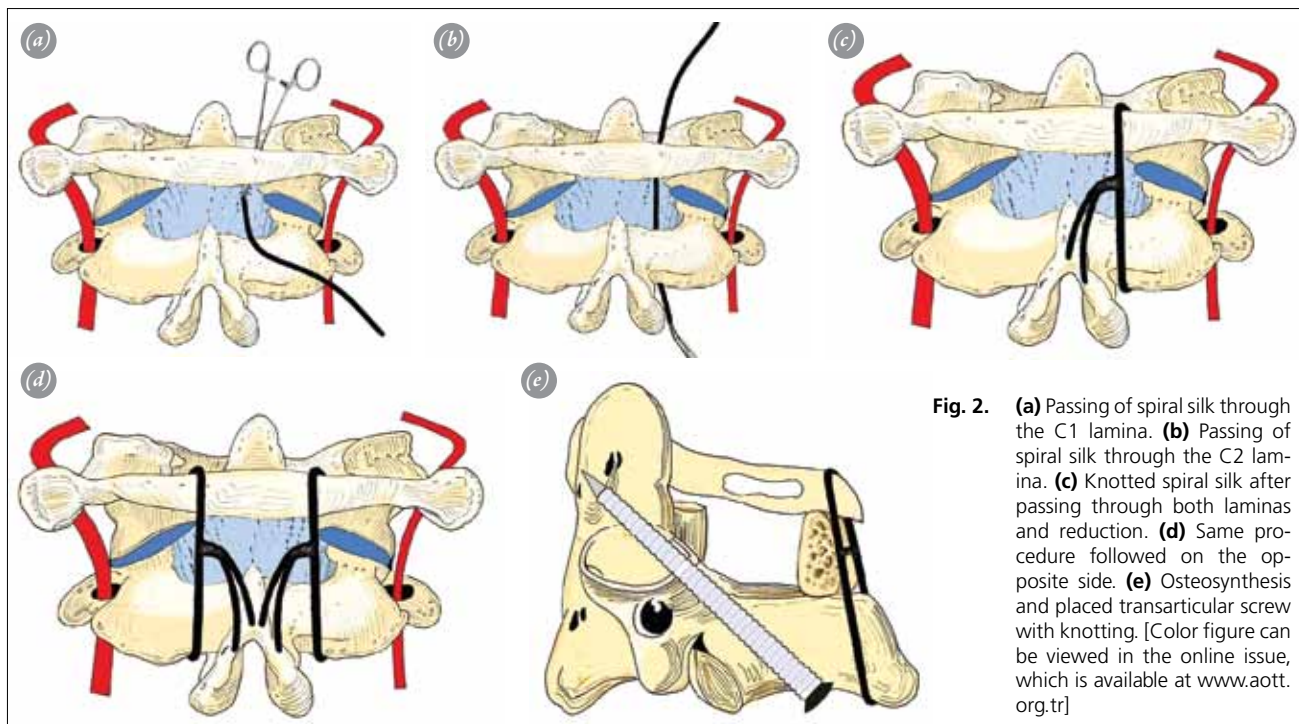


Fig. 2. (a) Passing of spiral silk through the C1 lamina. (b) Passing of spiral silk through the C2 lamina. (c) Knotted spiral silk after passing through both laminae and reduction. (d) Same procedure followed on the opposite side. (e) Osteosynthesis and placed transarticular screw with knotting. [Color figure can be viewed in the online issue, which is available at www.aott.org.tr]

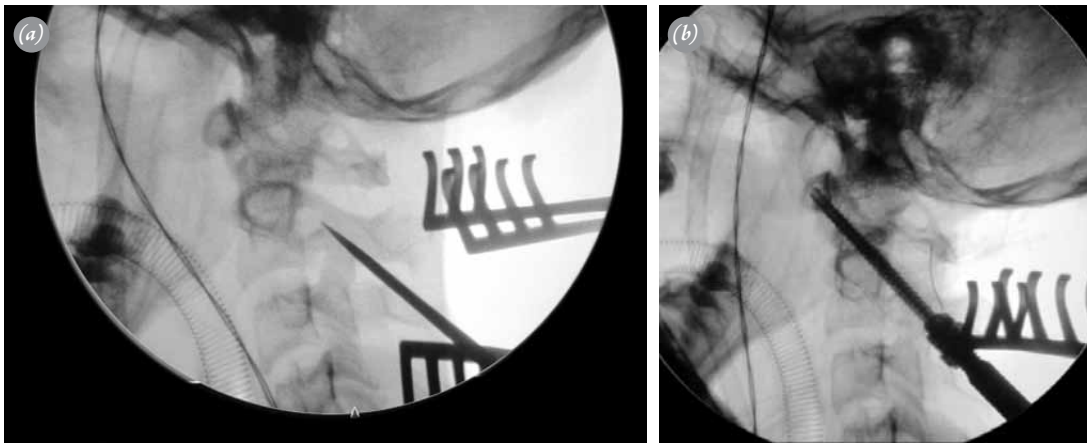


Fig. 3. (a) Perioperative fluoroscopy image; after knotting of laminas, the dislocation is reduced and screwing is securely made. (b) Fluoroscopy image after reduction and osteosynthesis.

ADI value was 1 mm. Malposition was observed in two screws (4%).

Posterior transodontoid screwing technique for C1-C2 fixation was used instead of transarticular screwing in two trauma cases.^[2] Postoperative Nurick scale and neck pain visual analog scale (VAS) values of the patients are defined in Table 1. Neck pain continued in 2 patients. One patient had the same VAS value postoperatively and one patient had a one point higher VAS value.

In the long-term follow-up, there was no restriction movement of the neck. No complaints were noted in the

level of disturbance of the patients in terms of neck comfort.

Discussion

Dislocation of the AAJ can occur in the axial, coronal or sagittal planes. In some cases, osteosynthesis can be provided by anterior odontoid screwing. However, it is also possible to treat with C1-C2 arthrodesis. Post reduction fusion should be provided in all cases of anatomic dislocation. If perioperative reduction is possible, the fixation of the C1-C2 complex after open reduction is provided by a suitable technique.^[3]

Table 1. Demographic distribution of the patients and assessment results.

No	Age	Gender	Diagnosis	VAS	Pre-op ADD	Post-op ADD	Pre-op Nurick score	Post-op Nurick score	Fusion at 12th month	VAS score of the neck
1	10	F	RA	7	6	1	2	1	Complete	2
2	56	F	OsO	7	7	1	2	1	Complete	2
3	45	M	OsO	6	7	1	1	1	Complete	1
4	34	F	RA	9	6	2	3	1	Complete at 15th month	3
5	61	M	RA	5	8	1	3	1	Pseudarthrosis	5
6	60	F	DF	8	9	1	2	1	Complete	2
7	30	M	DF	8	11	1	1	2	Complete	1
8	38	F	DF	7	12	2	1	2	Complete	2
9	55	F	DF	9	9	1	1	1	Complete	1
10	48	F	RA	7	7	1	1	1	Complete	2
11	43	M	OsO	5	8	1	1	1	Complete	1
12	58	F	PF	6	9	1	1	1	Complete	3
13	51	M	OsO	5	11	2	1	1	Complete	3
14	50	F	OsO	6	12	2	1	1	Complete	7
15	23	F	DF	7	7	1	1	1	Complete	1
16	33	M	RA	7	8	1	2	1	Complete at 15th month	3

ADD: Atlantodental distance; DF: Dens fracture; OsO: Os odontoides; PF: Previous fracture; RA: Rheumatoid arthritis; VAS: Visual analog scale.

C1-C2 fixation techniques include posterior insulated C1 side mass and C2 pars screwing, pedicular screwing, transarticular screwing,^[7] laminar screwing or hook usage techniques.^[8] There are specific advantages and disadvantages of each C1-C2 fixation techniques defined in the literature.^[3,5,15-18] However, regardless of which is used, reduction maneuver and fusion with autograft is essential. In C1-C2 luxation, fixation with screws only is not sufficient. The Sonntag sublaminar wire reconstruction technique, with binding of the iliac crest autograft to the surgical area, is the most preferred and frequently used with fusion rates of 82.6 to 100%.^[19] Bendable wires or soft titanium wires can be used for bone-wire construction. However, titanium wires may cause neural or dural injury due to loosening and are expensive.^[10,14,20,21] Another disadvantage of titanium cables or wires is that they may cause radiologic crowding and misinterpretation of fusion degree during follow-up. Conversely, there is no such disadvantage to the use of silk.

Controversy exists on the stability and fusion following fixation of the autograft with sublaminar wires. Matsumoto et al. reported successful fusion in all patients, with loosening of wires in 18 of 52 cases, causing spinal cord problems.^[19] Ito et al. reported wire loosening but successful fusion in all patients.^[22,23] Unfortunately, the wiring technique is difficult and time-consuming and may cause severe complications, especially in cases of canal stenosis.^[24] For these reasons, some authors recommend only bone lamella placement technique after decortication.^[19] Freely placed grafts without knotting to the lamina has resorption and displacement risks. If the interlaminar distance is wide, the free graft may compress the spinal cord. Nonunion might also occur if allograft bone chips are scattered and placed around the surgical field.

The main goals of our technique are reduction and arthrodesis. Reduction primarily corrects instability, which causes scissoring and compression of the spinal cord. After reduction, secure fixation is obtained. Arthrodesis creates an interlaminar connection or bridge with the tricortical iliac crest. There are several advantages of using sublaminar spiral silk. Primarily, knotting by twine shaped silk decreases the interspinous distance. Two-side application of this process makes it more secure. After reduction, transarticular screwing can be securely applied in an anatomical position. Additionally, by placing the iliac crest graft on the silk knots, the graft is tightly exposed to laminar contact, before a second graft knot is tied. This technique has many advantages for secure screwing and to create standard fusion between the C1 and C2.

Their high price and lack of consistent availability in the surgical room are the main disadvantages of titanium sublaminar wires. However, silk can be found easily in the surgical room and is a very cheap material. In addition, it does not create radiological visual pollution.

Fusion in particular is highly important in rheumatoid arthritis cases due to the high incidence rate of pseudarthrosis. Additionally, it is essential to provide contact between the bone decortication face and autograft cancellous chips in order to increase fusion strength in its revisions. A strong contact between the graft and the laminar decortication field should be provided. Although pseudarthrosis was present in one of our cases, implant insufficiency did not develop even in the 4th year. Transarticular screws provide 3-dimensional fixing and prevent implant failure.

In conclusion, sublaminar spiral silk for C1-C2 arthrodesis is an alternative technique to sublaminar wiring. The method provides secure anatomic reduction, is cheap and easily applied and does not require extra implant or cause loosening or neurological damage. In addition, it is free of radiological visual pollution. Yet, for more precise results, further comparative studies with higher proof values are required.

Conflicts of Interest: No conflicts declared.

References

1. Kotil K, Kalayci M, Bilge T. Management of cervicomedullary compression in patients with congenital and acquired osseous-ligamentous pathologies. *J Clin Neurosci* 2007;14:540-9.
2. Kotil K, Köksal NS, Kayacı S. Posterior transodontoid fixation: A new fixation (Kotil) technique. *J Craniovertebr Junction Spine* 2011;2:41-5.
3. Dickman CA, Sonntag VK. Posterior C1-C2 transarticular screw fixation for atlantoaxial arthrodesis. *Neurosurgery* 1998;43:275-81.
4. Gluf WM, Brockmeyer DL. Atlantoaxial transarticular screw fixation: a review of surgical indications, fusion rate, complications, and lessons learned in 67 pediatric patients. *J Neurosurg Spine* 2005;2:164-9.
5. Gluf WM, Schmidt MH, Apfelbaum RI. Atlantoaxial transarticular screw fixation: a review of surgical indications, fusion rate, complications, and lessons learned in 191 adult patients. *J Neurosurg Spine* 2005;2:155-63.
6. Paramore CG, Dickman CA, Sonntag VK. The anatomical suitability of the C1-2 complex for transarticular screw fixation. *J Neurosurg* 1996;85:221-4.
7. Madawi AA, Casey AT, Solanki GA, Tuite G, Veres R, Crockard HA. Radiological and anatomical evaluation of the atlantoaxial transarticular screw fixation technique. *J*

- Neurosurg 1997;86:961-8.
8. Melcher RP, Puttlitz CM, Kleinstueck FS, Lotz JC, Harms J, Bradford DS. Biomechanical testing of posterior atlantoaxial fixation techniques. *Spine* 2002;27:2435-40.
 9. Gallie WE. Fracture and dislocations of the cervical spine. *Am J Surg* 1939;46:495-9.
 10. Fraser AB, Sen C, Casden AM, Catalano PJ, Post KD. Cervical transdural intramedullary migration of a sublaminar wire. A complication of cervical fixation. *Spine* 1994;19:456-9.
 11. Geremia GK, Kim KS, Cerullo L, Calenoff L. Complications of sublaminar wiring. *Surg Neurol* 1985;23:629-35.
 12. Lundy DW, Murray HH. Neurological deterioration after posterior wiring of the cervical spine. *J Bone Joint Surg Br* 1997;79:948-51.
 13. Schrader WC, Bethem D, Scerbin V. The chronic local effects of sublaminar wires. An animal model. *Spine* 1988;13:499-502.
 14. Kakarla UK, Valdivia JV, Sonntag VK, Bambakidis NC. Intracranial hemorrhage and spinal cord injury from a fractured C1-C2 sublaminar cable: case report. *Neurosurgery* 2010;66:E1203-4.
 15. Grob D, Crisco JJ 3rd, Panjabi MM, Wang P, Dvorak J. Biomechanical evaluation of four different posterior atlantoaxial fixation techniques. *Spine* 1992;17:480-90.
 16. Harms J, Melcher RP. Posterior C1-C2 fusion with polyaxial screw and rod fixation. *Spine* 2001;26:2467-71.
 17. Henriques T, Cunningham BW, Olerud C, Shimamoto N, Lee GA, Larsson S, et al. Biomechanical comparison of five different atlantoaxial posterior fixation techniques. *Spine* 2000;25:2877-83.
 18. Lapsiwala SB, Anderson PA, Oza A, Resnick DK. Biomechanical comparison of four C1 to C2 rigid fixative techniques: anterior transarticular, posterior transarticular, C1 to C2 pedicle, and C1 to C2 intralaminar screws. *Neurosurgery* 2006;58:516-21.
 19. Matsumoto M, Chiba K, Nakamura M, Ogawa Y, Toyama Y, Ogawa J. Impact of interlaminar graft materials on the fusion status in atlantoaxial transarticular screw fixation. *J Neurosurg Spine* 2005;2:23-6.
 20. Garcia R Jr, Gorin S. Failure of posterior titanium atlantoaxial cable fixation. *Spine J* 2003;3:166-70.
 21. Bahadur R, Goyal T, Dhatt SS, Tripathy SK. Transarticular screw fixation for atlantoaxial instability - modified Magerl's technique in 38 patients. *J Orthop Surg Res* 2010;5:87.
 22. Ito T, Hayashi M, Takei H. Loosening of supplemental cable in transarticular screw fixation and bone grafting. *J Orthop Surg* 1998;6:71-4.
 23. Ito H, Neo M, Fujibayashi S, Miyata M, Yoshitomi H, Nakamura T. Atlantoaxial transarticular screw fixation with posterior wiring using polyethylene cable: facet fusion despite posterior graft resorption in rheumatoid patients. *Spine* 2008;33:1655-61.
 24. Stillerman CB, Wilson JA. Atlanto-axial stabilization with posterior transarticular screw fixation: technical description and report of 22 cases. *Neurosurgery* 1993;32:948-55.