



Effect of adjuvant therapies on recurrence in aneurysmal bone cysts

Burçin KEÇECİ, Levent KÜÇÜK, Alovzat ISAYEV, Dündar SABAH

Ege University, Faculty of Medicine, Department of Orthopedics and Traumatology, Izmir, Turkey

Objective: The aim of this study was to define the effective factors such as surgical method, age and cavity filling materials on local recurrence in the treatment of aneurysmal bone cysts.

Methods: The study included 85 patients (mean age: 17.9 years) that received surgical treatment for primary aneurysmal bone cyst. Nine were treated with cyst excision and 76 with intralesional curettage. The intralesional curettage group was divided into 3 subgroups according to adjuvant therapies applied; the first group received no additional adjuvant therapy, the second group received additional high-speed burr and the third group received additional high-speed burr and alcohol/phenol adjuvant treatments. Bone graft or bone cement was used to fill in the cavity. Mean follow-up period was 107.5 months. Groups were analyzed statistically in terms of local recurrence. Onset of cyst in ages under 10 and 20 years were considered a negative prognostic factor and analyzed statistically.

Results: Local recurrence occurred in 10 (11.8%) patients. Mean duration between the initial operation and recurrence was 10 months. There was no significant difference in terms of local recurrence among the surgical treatment groups, adjuvant therapy groups, age groups and bone graft and bone cement groups.

Conclusion: Careful curettage of the entire cyst wall remains the most important step in the intralesional treatment of aneurysmal bone cyst.

Key words: Biopsy; bone cyst; bone neoplasms; curettage.

Aneurysmal bone cyst (ABC) is a well-defined, lytic, benign lesion with trabeculations and is most commonly located in the metaphysis of the long bones. Causing cortical expansion, ABCs are characterized by channels and spaces inside the bone. Although less common than other tumors, ABCs account for 1 to 6% of all primary bone tumors diagnosed by biopsy.^[1-4] The mechanism for the development of ABC remains unclear. A number of theories have been proposed; reactive vascular malformation,^[5,6] trauma^[7-9] and genetic susceptibility.^[5,10-12] In addition to

primary aneurysmal bone cysts, ABCs can be secondary to an underlying tumor such as non-ossifying fibroma, chondroblastoma, solitary bone cyst, giant cell bone tumor (GCT), osteoblastoma, and fibrous dysplasia.^[13]

Prior to the onset of ABC treatment, a biopsy is recommended for the confirmation of histological diagnosis. Intralesional curettage is the treatment of choice. However, due to the high rate of local recurrence, adjuvant therapies such as high-speed burr (HSB) followed by alcohol/phenol solutions, liquid nitrogen, argon

Correspondence: Burçin Keçeci, MD. Ege Üniversitesi Tıp Fakültesi, Ortopedi ve Travmatoloji Anabilim Dalı, Bornova, 35100 İzmir, Turkey.

Tel: +90 232 - 390 27 00 e-mail: kececiburcin@hotmail.com

Submitted: December 26, 2013 **Accepted:** May 04, 2014

©2014 Turkish Association of Orthopaedics and Traumatology

Available online at
www.aott.org.tr

doi: 10.3944/AOTT.2014.14.0020

QR (Quick Response) Code



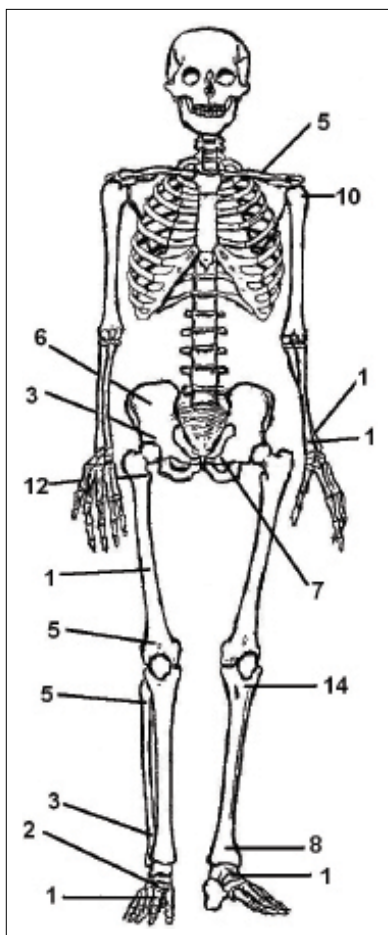


Fig. 1. Locations of ABCs in patients. The involvement rate of tubular bones was 70.5%.

beam coagulation or bone cement (polymethylmethacrylate) should be used in combination, as in GCT.¹⁴⁻²³ After the complete curettage of the cavity, bone grafts can be used to fill the hole. However, bone cement can be used in areas close to the articular surface with high risk of fracture. Several studies have reported that ABC can be more aggressive in childhood, particularly in those younger than 10 years of age.^{16,24-26} Despite all the aforementioned treatment modalities, the rate of recurrence still varies widely (3.7% to 59%).^[14-23]

The purpose of this study was to investigate the factors that could have an impact on the recurrence and the effects of adjuvant therapies on prognosis in the treatment of ABC.

Patients and methods

Patients diagnosed with ABC and treated between 1979 and 2008 in our clinic were retrospectively evaluated. Inclusion criteria were; diagnosis of ABC, treatment with

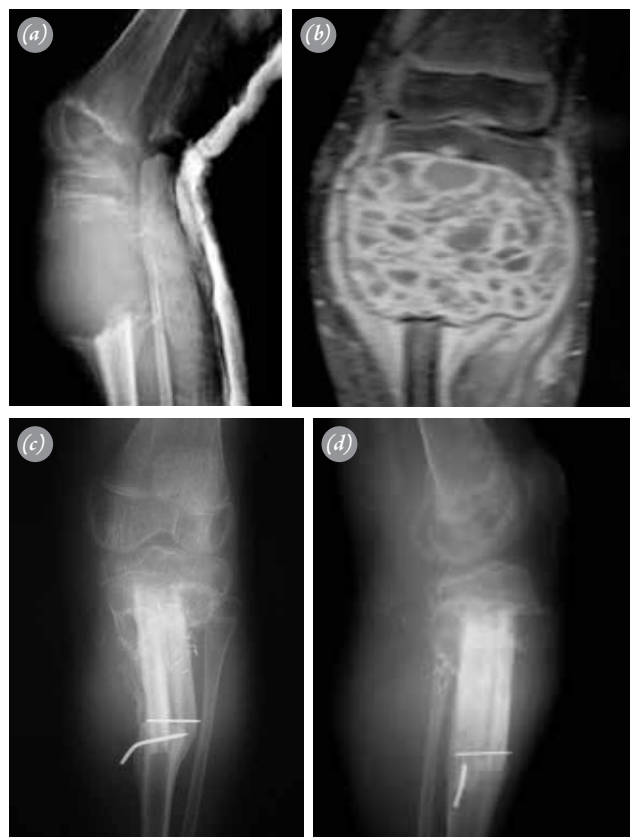

Fig. 2. (a) Lateral radiograph of a large-sized mass in the proximal left tibia in a 12-year-old boy. (b) Magnetic resonance image of the same lesion. (c) Anteroposterior radiograph taken 6 months after resection of the cyst and reconstruction with fibular autograft. (d) Lateral radiograph taken at the follow-up examination.

surgical methods, all biopsies and treatment procedures performed in our center, and a follow-up period of at least 48 months. Patients presenting with recurrent lesions, those with comorbid bone lesions on direct radiographs who were diagnosed with secondary ABC, those without final follow-up data and those with inadequate follow-up time were excluded from the study.

Histological diagnoses were available for all patients. All pre- and postoperative radiological images, clinical reports related to surgery, clinical observation and pathology reports were documented for each patient. Postoperative physical and radiological examinations were performed every 6 months for the first 2 years and thereafter once every year. Computed tomography (CT) was used as an advanced imaging technique in cases operated on before 1993 and MRI in those operated on after 1993.

A total of 85 patients (40 females and 45 males) were included in the study. Mean postoperative follow-up was

Table 1. Distribution of patients according to surgical treatment methods.

Treatment method	Number of patients	Average age	Average follow-up period (months)	Sex (Female/Male)
Aggressive curettage	14	16.78	133.28	3/11
Aggressive curettage + HSB	19	17.42	126.36	10/9
Aggressive curettage + HSB + alcohol/phenol	43	18.13	88.65	22/21
Resection	9	19.66	117.77	5/4
Total	85	17.91	107.5	40/45

HSB: High-speed burr.

107.5 (range: 48 to 300) months. Mean age was 17.91 (range: 3 to 66) years. Figure 1 shows tumor localizations.

Patients were treated with two different surgical techniques depending on the size and location of the cyst; resection of the cyst and intralesional curettage. In large-sized lesions with a high risk of recurrence and in locations with no risk of morbidity upon removal of the lesion, wide resection of the cyst was preferred (Figs. 2a and b). Depending on the results of the preoperative imaging techniques, scrapping out of the contents of the cyst by curettage was performed in relatively smaller lesions with adequate bone stock around the cyst to carry load. In this technique, an access is made where it is most secure anatomically and the cystic wall is thinnest and the contents of the cyst are scrapped out with curettes of different sizes. This method was performed in our clinic until 1992. Thereafter, an HSB technique was combined with aggressive curettage. As chemical adjuvants, 70 to 80% methyl alcohol was administered for 10 minutes, followed by the use of phenol solutions for the subsequent 10 minutes. Following the adjuvant therapy, depending on the location and size of the cyst and the adjacency of the cyst to a load-bearing joint, the cavity was filled with bone grafts or bone cement. The cysts

close to the articular surface and those with the risk of collapse on weight-bearing were filled with bone cement (Figs. 3a and b).

Patients were treated using four different types of surgical techniques; resection of the cyst, aggressive curettage, aggressive curettage and HSB, or aggressive curettage plus HSB and chemical adjuvant therapy (Table 1). Rate of recurrence was evaluated for each surgical group individually and the effects of each surgical technique on recurrence were statistically analyzed.

Patients were also grouped regardless of the surgical procedure performed in bone graft and bone cement groups (Table 2). The rate of recurrence was calculated for each group individually and the effects of each surgical technique on recurrence were analyzed via statistical methods.

In order to examine the effects of age on recurrence, patients were compared according to age. First, patients aged 10 years or younger were compared to those older than 10 years of age. Mean follow-up time of the 24 patients younger than 10 years of age (mean age: 6.91; 9 females and 15 males) was 112.5 months. Mean follow-up time of the 61 patients older than 10 years of age

Table 2. Distribution of cavity filling materials which were used after cyst excision. Cyst resection group was also included in the table.

Groups	Treatment method	Number of patients	Average age	Average follow-up period (months)	Sex (Female/Male)
Bone cement group (1+2+3)	(1) Ag. Cur. + BC	21	21.6	97.23	10/11
	(2) Ag. Cur. + HSB + BC				
	(3) Ag. Cur. + HSB + A/P + BC				
Bone graft group (A+B+C)	(A) Ag. Cur. + BG	55	16.2	109.7	25/30
	(B) Ag. Cur. + HSB + BG				
	(C) Ag. Cur. + HSB + A/P + BG				
Resection	Resection	9	19.66	117.77	5/4
Total		85	17.91	107.5	40/45

A/P: Alcohol/Phenol; Ag. Cur: Aggressive curettage; BC: Bone cement; BG: Bone graft; HSB: High-speed burr.

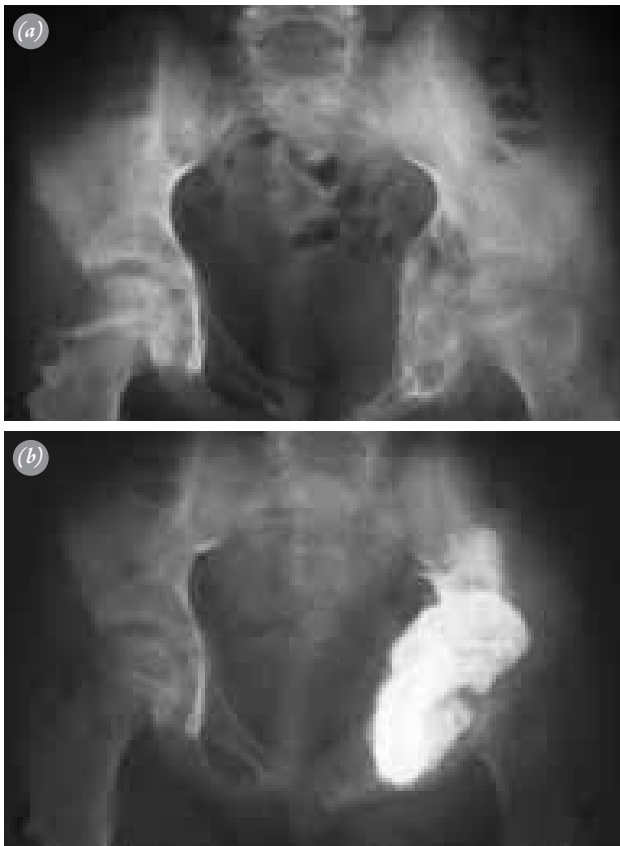

Fig. 3. (a) Preoperative anteroposterior image of the pelvis in a 9-year-old boy with ABC in the left acetabulum. (b) Image of the pelvis after curettage and bone cementing.

(mean age: 22.24; 31 females and 30 males) was 105.55 months. In the second comparison, patients younger than 20 years of age were compared to those older than 20 years of age. Mean follow-up time of the 65 patients younger than 20 years of age (mean age: 12.51; 26 females and 39 males) was 110.64 months. Mean follow-up time of 20 patients older than 20 years of age (mean age 35.5; 14 females and 6 males) was 97.35 months.

Data analysis was performed using SPSS 18 for Windows (SPSS Inc., Chicago IL, USA). Pearson's chi-squared test was used to compare the effects of each surgical technique on recurrence and the Fisher's exact test was used to compare recurrence rates. The recurrence-free survival was evaluated using the Kaplan-Meier survival analysis and the Cox-Mantel test was used for the evaluation of the difference between groups. A p value of <0.05 was considered statistically significant.

Results

Of all patients, 10 (11.8%) had postoperative local recurrence. The mean time to local recurrence was 10 (range: 3 to 18) months.

A total of 76 patients underwent curettage, 10 of which (13.2%) had local recurrence. A total of 9 patients underwent resection in the treatment of ABC. None of these patients had local recurrence (Figs. 2c and d). Comparison of the two surgical techniques demonstrated no superiority of resection statistically in the prevention of the development of local recurrence ($p>0.05$).

Three groups were constructed depending on the technique performed. In the aggressive curettage group, 1 of 14 (7.1%) patients (3 females and 11 males) had local recurrence. In the enucleation of the cavity by aggressive curettage and HSB group, 3 (15.8%) of 19 patients (10 females and 9 males) had local recurrence. In the aggressive curettage, HSB and administration of chemical adjuvant therapy with alcohol/phenol group, 6 (14%) of 43 patients (22 females and 21 males) had local recurrence. No statistically significant differences were noted in the prevention of the development of local recurrence between surgical techniques ($p>0.05$).

Cavity filling with bone cement was performed in a total of 21 patients (10 females and 11 males). In these patients, 5 cysts were located in the pubis, 3 in the iliac bone, 3 in the proximal tibia, 3 in the distal tibia, 3 in the proximal humerus, 1 in the proximal fibula, 1 in the distal femur, 1 in the proximal femur and 1 in the cuneiform. Of these patients, only 1 (4.8%) had recurrence. In the prevention of the development of recurrence, there were no statistically significant differences between the cement group and the allograft group ($p>0.05$) (Fig. 4).

To investigate the effects of age on recurrence in patients with ABC, patients aged 10 years or younger were compared with those older than 10 years. Two (8.3%) of the 24 patients (9 females and 15 males) younger than 10 years of age had local recurrence. The cysts of patients with recurrence were located in the acetabulum and the cavity was filled with allograft. Eight (13.1%) of the 61 patients (31 females and 30 males) older than 10 years had recurrence. No statistically significant differences were noted between these two groups in the development of local recurrence ($p>0.05$).

The effect of age on recurrence was reevaluated by comparing patients aged 20 years or younger with those older than 20 years of age. No statistically significant differences were found between the groups ($p>0.05$).

Discussion

In this study, two procedures were used as surgical treatment methods for the treatment of aneurysmal bone cysts; curettage of the cystic cavity and the excision of the cyst. Post-curettage adjuvant therapies were not

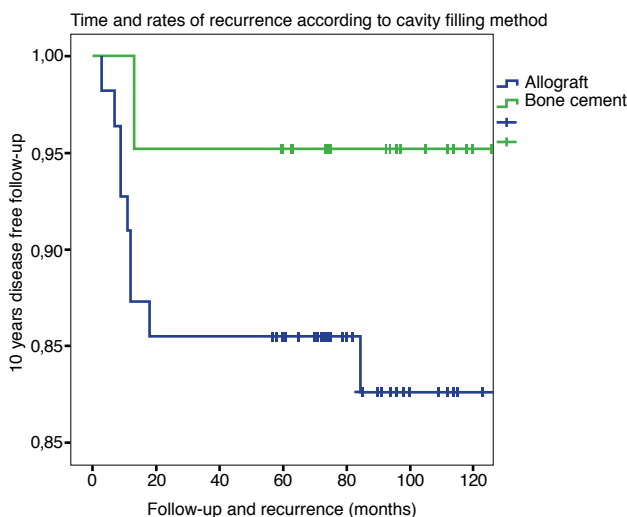


Fig. 4. Ten-year disease-free survival of bone cement and bone graft groups. (Disease-free survivals were calculated with the Kaplan-Meier survival analysis and difference between two groups were analyzed with the Cox-Mantel test ($p=0.180$)).

taken into consideration in the comparison of these two groups. While it is promising that patients undergoing resection had lower recurrence rates, reconstruction of the defects can pose problems and decreased functional capacity may occur.^[17,18,21,23] In the current study, 6 patients undergoing postresection reconstruction with bone grafts had no functional limitation. Mankin et al. reported that patients with lesions of the proximal or mid-fibula or the clavicle or body of the scapula could be treated with resection alone whereas the lesions located in the metatarsal bones should be treated with arthrodesis with autograft after resection.^[18]

The rate of recurrence was 7.1% in the group undergoing aggressive curettage alone, 15.8% in the group undergoing aggressive curettage and further enucleation of the cavity with HSB and 14% in the group undergoing aggressive curettage supplemented with HSB and alcohol/phenol solution. There were no statistically significant differences in the prevention of the development of recurrence between the groups ($p>0.05$). A comparison of our results with those of other studies demonstrated that the rate of recurrence was lower in these three groups than those reported in the literature.^[14-23] We believe that the relatively low recurrence rates in our study were due to the small number of patients undergoing aggressive curettage, the wide variation in the location and size of the cysts, our inability to construct a homogeneous group of patients regarding cavity filling and the use of aggressive curettage, which is the most important step in the surgical treatment of ABC.

In this study, we attempted to demonstrate whether

bone cement used both as a cavity filling material and an adjuvant therapeutic agent had a positive effect on the prevention of recurrence. Ozaki et al.^[20] reported 30 patients who underwent bone graft and 35 bone cement after aggressive curettage and found local recurrence rates of 37% in the group undergoing bone graft and 17% in the group undergoing cementation. The comparison of relapse-free survival revealed that the use of bone cement was more efficient compared to the use of bone graft in the prevention of recurrence ($p=0.038$). In a study by Mankin et al., 18 110 patients underwent bone grafting and 20 cementation. The rates of local recurrence were 21.8% and 25%, respectively. No statistically significant differences were noted between the groups ($p>0.05$). In our study, 55 patients underwent bone grafting and 21 cementation. Only 4.8% of the patients undergoing cementation had local recurrence whereas 16.4% of the patients undergoing bone grafting had local recurrence. The comparison of relapse-free survival between the two groups revealed no statistically significant differences in the development of recurrence ($p>0.05$).

Liquid nitrogen used as an adjuvant therapy (cryotherapy) has similar recurrence rates to those of bone cement. In a study by Schreuder et al., only 1 (3.7%) of 27 patients undergoing cryotherapy using liquid nitrogen had recurrence.^[22] In a small series by Biesecker et al., only 1 (14.3%) of 7 patients had local recurrence.^[16] Marcove et al. reported that 9 (17.6%) of 51 patients had local recurrence.^[19] Despite the low recurrence rates, some side effects may occur as a result of treatment with liquid nitrogen. The low temperature used in cryotherapy can result in necrosis and damage to the surrounding tissue. The skin should be protected during the practice. Dabak et al. sprayed nitrogen on the cyst walls in 9 patients with primary ABC and none experienced recurrence.^[27]

Aneurysmal bone cysts usually present clinically during childhood or adolescence. The role of age in the development of recurrence has been investigated, yielding mixed results. A study by Dormans et al.²⁶ classified 45 children with primary ABC into two groups depending on age; children aged 10 years or younger and those older than 10 years of age. No statistically significant differences were found in recurrence between the two groups. Gibbs et al. reported considerably high recurrence rates in children younger than 10 years of age.^[24] Freiberg et al. reported recurrence in 5 of 7 children younger than 10 years of age.^[25] The results of our study failed to demonstrate any positive or negative effects of age on recurrence.

The identification of certain prognostic factors at

the end of long-term follow-ups, the high number of patients and the determination of treatment algorithms by providing some surgical tricks may be considered advantages of our study. On the other hand, the limitation of our study was our inability to standardize the patient groups.

In conclusion, effective curettage is the most important step in the surgical treatment of ABC, the proper performance of which results in reduced recurrence rates. Adjuvant treatment methods should be included in the treatment. While the association of the use of bone cement both as a cavity-filling material and an adjuvant therapeutic agent with a statistically significant decrease in the development of recurrence could not be determined, the ability to use imaging techniques for the early diagnosis of recurrence with the use of bone cement should be noted.

Conflicts of Interest: No conflicts declared.

References

- Leithner A, Windhager R, Lang S, Haas OA, Kainberger F, Kotz R. Aneurysmal bone cyst. A population based epidemiologic study and literature review. *Clin Orthop Relat Res* 1999;363:176-9.
- Mirra JM. Aneurysmal bone cyst. In: Mirra JM, Picci P, Gold RH, editors. *Bone Tumors: Clinical, Radiological, and Pathologic Correlations*. Philadelphia, PA: Lea and Febiger; 1989. p.1267-311.
- Capanna R, Campanacci DA, Manfrini M. Unicameral and aneurysmal bone cysts. *Orthop Clin North Am* 1996;27:605-14.
- Yüçetürk G, Sabah D, Keçeci B, Kara AD, Yalçinkaya S. Prevalence of bone and soft tissue tumors. *Acta Orthop Traumatol Turc* 2011;45:135-43. [CrossRef](#)
- Leithner A, Machacek F, Haas OA, Lang S, Ritschl P, Radl R, et al. Aneurysmal bone cyst: a hereditary disease? *J Pediatr Orthop B* 2004;13:214-17. [CrossRef](#)
- Lichtenstein L. Aneurysmal bone cyst. A pathological entity commonly mistaken for giant-cell tumor and occasionally for hemangioma and osteogenic sarcoma. *Cancer* 1950;3:279-89. [CrossRef](#)
- Dabezies EJ, D'Ambrosia RD, Chuinard RG, Ferguson AB Jr. Aneurysmal bone cysts after fracture. A report of three cases. *J Bone Joint Surg Am* 1982;64:617-21.
- Ginsburg LD. Congenital aneurysmal bone cyst. Case report with comments on the role of trauma in the pathogenesis. *Radiology* 1974;110:175-6. [CrossRef](#)
- Ratcliffe PJ, Grimer RJ. Aneurysmal bone cyst arising after tibial fracture. A case report. *J Bone Joint Surg Am* 1993;75:1225-7.
- Althof PA, Ohmori K, Zhou M, Bailey JM, Bridge RS, Nelson M, et al. Cytogenetic and molecular cytogenetic findings in 43 aneurysmal bone cysts: aberrations of 17p mapped to 17p13.2 by fluorescence in situ hybridization. *Mod Pathol* 2004;17:518-25. [CrossRef](#)
- Leithner A, Windhager R, Kainberger F, Lang S. A case of aneurysmal bone cyst in father and son. *Eur J Radiol* 1998;29:28-30. [CrossRef](#)
- Oliveira AM, Perez-Atayde AR, Inwards CY, Medeiros F, Derr V, Hsi BL, et al. USP6 and CDH11 oncogenes identify the neoplastic cell in primary aneurysmal bone cysts and are absent in so-called secondary aneurysmal bone cysts. *Am J Pathol* 2004;165:1773-80. [CrossRef](#)
- Martinez V, Sissons HA. Aneurysmal bone cyst. A review of 123 cases including primary lesions and those secondary to other bone pathology. *Cancer* 1988;61:2291-304.
- Cottalorda J, Kohler R, Chotel F, De Gauzy JS, Lefort G, Louahem D, et al. Recurrence of aneurysmal bone cysts in young children: a multicentre study. *J Pediatr Orthop B* 2005;14:212-8. [CrossRef](#)
- Cottalorda J, Bourelle S. Current treatments of primary aneurysmal bone cysts. *J Pediatr Orthop B* 2006;15:155-67.
- Biesecker JL, Marcove RC, Huvos AG, Miké V. Aneurysmal bone cysts. A clinicopathologic study of 66 cases. *Cancer* 1970;26:615-25. [CrossRef](#)
- Campanacci M, Capanna R, Picci P. Unicameral and aneurysmal bone cysts. *Clin Orthop Relat Res* 1986;204:25-36.
- Mankin HJ, Hornicek FJ, Ortiz-Cruz E, Villafuerte J, Gebhardt MC. Aneurysmal bone cyst: a review of 150 patients. *J Clin Oncol* 2005;23:6756-62. [CrossRef](#)
- Marcove RC, Sheth DS, Takemoto S, Healey JH. The treatment of aneurysmal bone cyst. *Clin Orthop Relat Res* 1995;311:157-63.
- Ozaki T, Hillmann A, Lindner N, Winkelmann W. Cementation of primary aneurysmal bone cysts. *Clin Orthop Relat Res* 1997;337:240-8. [CrossRef](#)
- Ruiter DJ, van Rijssel TG, van der Velde EA. Aneurysmal bone cysts: a clinicopathological study of 105 cases. *Cancer* 1977;39:2231-9. [CrossRef](#)
- Schreuder HW, Veth RP, Pruszczynski M, Lemmens JA, Koops HS, Molenaar WM. Aneurysmal bone cysts treated by curettage, cryotherapy and bone grafting. *J Bone Joint Surg Br* 1997;79:20-5. [CrossRef](#)
- Vergel De Dios AM, Bond JR, Schives TC, McLeod RA, Unni KK. Aneurysmal bone cyst. A clinicopathologic study of 238 cases. *Cancer* 1992;69:2921-31. [CrossRef](#)
- Gibbs CP Jr, Hefele MC, Peabody TD, Montag AG, Aithal V, Simon MA. Aneurysmal bone cyst of the extremities. Factors related to local recurrence after curettage with a high-speed burr. *J Bone Joint Surg Am* 1999;81:1671-8.
- Freiberg AA, Loder RT, Heidelberger KP, Hensinger RN. Aneurysmal bone cysts in young children. *J Pediatr Orthop* 1994;14:86-91. [CrossRef](#)

-
26. Dormans JP, Hanna BG, Johnston DR, Khurana JS. Surgical treatment and recurrence rate of aneurysmal bone cysts in children. *Clin Orthop Relat Res* 2004;421:205-11. [CrossRef](#)
27. Dabak N, Tomak Y, Piskin A, Gulman B, Ozcan H. Early results of a modified technique of cryosurgery. *Int Orthop* 2003;27:249-53. [CrossRef](#)