



Lateral versus medial approach for intra-articular knee injections

Panayiotis KOULOUVARIS¹, Marios LYKISSAS², Stavros RISTANIS²,
George AGGELIDAKIS², Alexandros MAVRODONTIDIS²

¹Department of Orthopedics, Attikon Hospital, School of Medicine, University of Athens, Athens, Greece;

²Department of Orthopedic Surgery, School of Medicine, University of Ioannina, Ioannina, Greece

Objective: The aim of this study was to determine whether the medial or the lateral mid-patellar approach is the most reliable for intra-articular knee injections.

Methods: The study included 76 knees of 76 patients divided into 2 groups. The first group consisted of 38 patients with a knee injury and resultant knee effusion. The second group included 38 patients without any known knee pathology. Patients were matched according to age and gender. The medial joint opening (medial patellofemoral angle) was calculated on a T1-weighted transverse image by measuring the anatomic angle between the femur and the patella. The lateral joint opening (lateral patellofemoral angle) was calculated in a similar way.

Results: The medial patellofemoral angle was significantly higher than the lateral patellofemoral angle in both groups ($p < 0.001$).

Conclusion: The medial patellofemoral angle is significantly higher than the lateral patellofemoral angle in both healthy knees and knees with effusion. Therefore, the medial approach appears to be more accurate for intra-articular knee injection due to the medial joint's larger opening.

Key words: Intra-articular injection; knee; lateral patellofemoral angle; medial patellofemoral angle; MRI.

Joint injections are straightforward procedures that can be performed by orthopedists and primary physicians.^[1] Injections are most common in the knee joint (37%), followed by the glenohumeral joint (17%).^[2] Despite its widespread use in orthopedic and rheumatologic office settings, the accuracy of the injection has been debated and the techniques have not been standardized.^[3] An accuracy rate of 71 to 93% for placement of intra-articular knee injections by an experienced orthopedic surgeon was reported in a prospective series of 240 injections.^[4]

Another study confirming needle accuracy with imaging and ultrasonic methods reported accuracy rates of only 66% for intra-articular and 33% for extra-articular injections.^[5]

Several approaches to the knee joint have been described, including the medial, lateral and anterior approach.^[4,6,7] The majority of studies have reported the lateral approach to be more accurate than the others.^[8,9] However, 100% accuracy could not be obtained in any study through any of the possible portals.

Correspondence: Marios Lykissas, MD. Department of Orthopedic Surgery, School of Medicine, University of Ioannina, Ioannina 45100, Greece.

Tel: (+30-2651) 007 472 e-mail: mariolyk@yahoo.com

Submitted: April 17, 2014 **Accepted:** July 06, 2014

©2015 Turkish Association of Orthopaedics and Traumatology

Available online at
www.aottt.org.tr
doi: 10.3944/AOTT.2015.14.0142
QR (Quick Response) Code



The purpose of the present study was to compare the lateral and medial approaches and to determine the most reliable approach for the intra-articular space of the knee joint using magnetic resonance imaging (MRI).

Patients and methods

The study included 76 knees of 76 patients (18 males, 58 females; mean age: 47.4 years, range: 16 to 81 years) divided into 2 groups. The first group consisted of 38 patients with a knee injury and resultant knee effusion. Patients in this group underwent MRI examination 2 days after the injury which revealed isolated knee injury without fracture. The second group included 38 patients without knee injury or any known knee pathology. Patients were matched according to age and gender. All patients agreed with the testing protocol and consent form was obtained according to our institution policy.

The medial and lateral joint opening were measured on MRI. The examination protocol included sequences in all 3 planes in order to obtain an overview of the joint structure. The implementation of a 3-dimensional spoiled gradient-echo sequence with fat suppression in the oblique sagittal plane was used for determining the actual margins of the joint capsule, medially and laterally, according to the different signal intensity of the synovial fluid. Two experienced radiologists reviewed the MRIs separately. Analysis was performed on the MRI workstation, which was used to apply lines on each image and to measure the appropriate angles automatically.

The medial joint opening was calculated on a T1-weighted axial image by measuring the anatomic angle between the femur and the patella (at the upper edge of the patella, the middle patella, and at the lower edge of the patella) after drawing a line that was parallel to the corresponding femoral condyle and a line that was parallel to the opposite side of the patella (Fig. 1a). The lateral joint opening was calculated in a similar way (Fig. 1b).

Statistical analyses were carried out using SPSS v.19.0 (SPSS Inc., Chicago, IL, USA) software. T-tests were used within each group for post hoc comparisons. The level of significance was set at $p < 0.05$.

Results

There were significant differences in all three heights of the patella between the medial and lateral patellofemoral angles in the control group (Table 1). The mean medial patellofemoral angle at the upper edge of the patella was 39.6° (range: 36.0° to 43.1°), while the mean lateral patellofemoral angle was 18.6° (range: 15.7° to 21.6°) ($p < 0.001$). The mean medial angle was 30.6° (range: 26.8° to 33.2°) and the mean lateral angle was 6.6° (range: 5.6° to 7.5°) at the mid-patella ($p < 0.001$). At the lower edge of the patella, the mean medial angle was 19.5° (range: 16.5° to 22.6°), while the mean lateral angle was 10.4° (range: 9.1° to 11.7°) ($p < 0.001$).

There were significant differences between the medial and lateral patellofemoral angles in the knee effusion group (Table 1). At the upper edge of the patella,

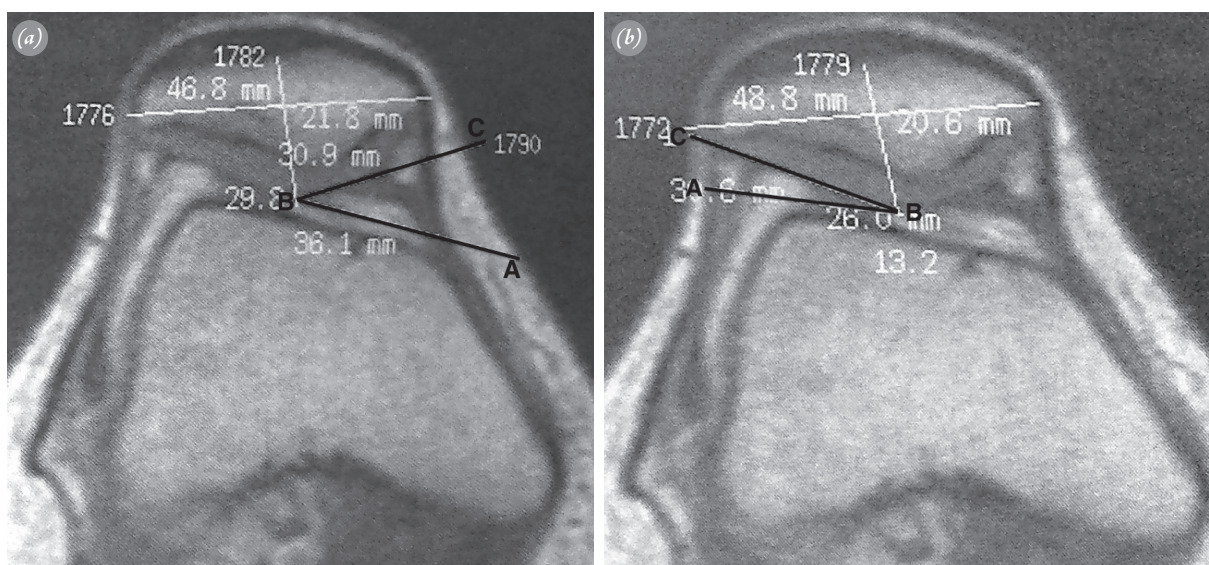


Fig. 1. (a) The medial joint opening was calculated on an axial MRI view by measuring the angle between the femur and the patella after drawing a line parallel to the medial femoral condyle (AB) and a line parallel to the medial side of the patella (BC). (b) The lateral joint opening was calculated on an axial MRI view by measuring the angle between the femur and the patella after drawing a line parallel to the lateral femoral condyle (AB) and a line parallel to the lateral side of the patella (BC).

Table 1. Lateral and medial patellofemoral angles at the upper-lower pole and mid-patella heights.

	Mean lateral angle (range)	Mean medial angle (range)	p
Healthy knees			
Upper pole of the patella	18.6° (15.7°-21.6°)	39.6° (36.0°-43.1°)	<0.001
Mid-patella	6.6° (5.6°-7.5°)	30.6° (26.8°-33.2°)	<0.001
Lower pole of the patella	10.4° (9.1°-11.7°)	19.5° (16.5°-22.6°)	<0.001
Knees with effusion			
Upper pole of the patella	25.02° (22.7°-27.5°)	46.1° (42.1°-50.1°)	<0.001
Mid-patella	8.8° (7.5°-10.2°)	34.4° (30.4°-37.6°)	<0.001
Lower pole of the patella	11.7° (9.7°-13.8°)	24.6° (21.1°-28.09°)	<0.001

the mean medial angle was 46.1° (range: 42.1° to 50.1°) while the mean lateral angle was 25.02° (range: 22.7° to 27.5°) ($p < 0.001$). The mean medial angle was 34.4° (range: 30.4° to 37.6°) and the mean lateral angle was 8.8° (range: 7.5° to 10.2°) at the mid-patella ($p < 0.001$). At the lower edge of the patella, the mean medial angle was 24.6° (range: 21.1° to 28.09°) and the mean lateral angle was 11.7° (range: 9.7° to 13.8°) ($p < 0.001$).

Discussion

Our results revealed that it is easier to enter the knee joint space from the medial side of the upper edge of the patella since the anatomic patellofemoral angle was found to be higher at this site. The medial angle was higher in all three heights of the patella. These findings were confirmed in both healthy knees and knees with effusion.

The use of intra-articular injections in the knee joint has increased with the introduction of agents such as hyaluronic acid. The presence of an effusion eases needle placement because fluid aspiration documents the intra-articular placement of the needle. In the absence of an effusion, intra-articular needle placement is more difficult to confirm. Few studies have evaluated the accuracy of needle placement and there is no consensus in the literature on the appropriate technique.^[4,8,9]

Jones et al.^[5] used a single radiograph to evaluate the accuracy of injection of a mixture of depo-methylprednisolone and radiographic contrast medium, performed by 5 rheumatologists. The authors reported that 39 out of 59 (66%) knee joint injections were intra-articular and almost one-third were extra-articular. In view of the poor accuracy rate, the authors recommended that knee injection techniques should be refined. Jackson et al.^[4] evaluated the accuracy of needle placement in 80 obese patients undergoing treatment for symptomatic degenerative joint disease with the use of fluoroscopy and found an accuracy rate of 71% (57 out of 80 knees) when

the anterolateral injection portal was used, 75% (60 out of 80 knees) with the anteromedial injection portal, and 93% (74 out of 80 knees) when the lateral mid-patellar portal injection site was used.

In a meta-analysis, Hermans et al.^[10] reported that among 9 studies the accuracy of the superolateral approach was higher than that of the anteromedial approach (93% vs. 75%). In another systematic review of the literature, Daley et al.^[11] evaluated the accuracy rate with and without imaging guidance. The authors reported 99% accuracy rate with imaging compared to 79% accuracy rate without imaging guidance. In a similar study, the short-term clinical efficacy of ultrasound guidance intra-articular injections was greater than the efficacy of anatomic/palpation injections.^[12] However, the long-term efficacy was not significantly different with either technique. In a randomized, double-blind, controlled study, while ultrasound guided injections were more accurate than the anatomic/palpation injections, the short-term clinical outcomes were not significantly different.^[13]

Employing radiographic evidence, Toda and Tsukimura^[7] reported a higher accuracy rate using the anterolateral approach than the anteromedial approach with the knee at 30° of flexion. The authors highlighted that the approach should be modified according to the radiographic severity of knee osteoarthritis. In a cadaver study, Esenyel et al.^[9] reported lower accuracy rates using the mid-patellar medial approach than the anteromedial or anterolateral approaches. While the accuracy rate was higher with the anterolateral approach, the results were not statistically significant when compared to the anteromedial approach. One case has been reported in the literature with saphenous neuropathy following knee joint injection via the medial approach.^[14]

In the present study, we aimed to provide scientific evidence for accurate intra-articular knee injections using the medial approach. The superolateral approach

is the most commonly investigated approach. To our knowledge, there are no studies in the literature that have evaluated the medial approach. The present study is the first to suggest that the medial mid-patellar approach can facilitate an accurate injection since it offers a larger joint space for an intra-articular entry. Many rheumatologists prefer the medial approach with the knee extended because the lateral patellofemoral cleft is narrower and the joint capsule is tougher laterally than medially.^[15]

Our results also confirm that the medial patellofemoral angle is larger than the lateral. The medial angle in the upper edge of the patella in knees without effusion was 39.6° compared with the lateral angle which was only 18.6°. In knees with effusion, the medial angle was 46.1° compared with the lateral angle of 25.2°.

The medial mid-patellar approach is also easier for the surgeon in cases of overweight patients where there is a difficulty establishing anatomical landmarks about the knee. The large quantity of subcutaneous fat increases the distance between the skin and the joint space and some authors have reported difficulty aspirating and injecting from the lateral joint line.^[15] The medial femoral condyle is more prominent as an anatomic landmark than the lateral femoral condyle and the medial edge of the patella is more easily accessible with the patient's lower limb externally rotated.

Knee injections using imaging guidance have a higher accuracy rate than those using the anatomic/palpation approach. This is more evident for joints with difficult anatomic landmarks, such as the hip and midtarsal joints. However, there is an extra cost, time, and difficulty in the use of imaging in daily clinical application. Moreover, the short- and long-term clinical benefits have not yet been clearly shown.^[16] We agree with the notion that imaging guided approach should be used in cases in which the anatomic approach is difficult.^[16]

The current study was limited to the assessment of the patellofemoral angle according to the type and severity of the underlying disease. Another limitation was the fact that the amount of effusion in the first group varied between the patients. In addition, mean body mass index was different between the two groups.

In conclusion, the medial patellofemoral angle was significantly higher than the lateral in both healthy individuals and knees with effusion. Therefore, intra-articular knee injections appear to be more accurate when performed via the medial approach due to the larger medial joint opening.

Conflicts of Interest: No conflicts declared.

References

1. Zuckerman JD, Meislin RJ, Rothberg M. Injections for joint and soft tissue disorders: when and how to use them. *Geriatrics* 1990;45:45-55.
2. Wittich CM, Ficalora RD, Mason TG, Beckman TJ. Musculoskeletal injection. *Mayo Clin Proc* 2009;84:831-7.
3. Schumacher HR Jr. Aspiration and injection therapies for joints. *Arthritis Rheum* 2003;49:413-20. [CrossRef](#)
4. Jackson DW, Evans NA, Thomas BM. Accuracy of needle placement into the intra-articular space of the knee. *J Bone Joint Surg Am* 2002;84:1522-7.
5. Jones A, Regan M, Ledingham J, Pattrick M, Manhire A, Doherty M. Importance of placement of intra-articular steroid injections. *BMJ* 1993;307:1329-30. [CrossRef](#)
6. Thomsen TW, Shen S, Shaffer RW, Setnik GS. Videos in clinical medicine. Arthrocentesis of the knee. *N Engl J Med* 2006;354:19. [CrossRef](#)
7. Toda Y, Tsukimura N. A comparison of intra-articular hyaluronan injection accuracy rates between three approaches based on radiographic severity of knee osteoarthritis. *Osteoarthritis Cartilage* 2008;16:980-5. [CrossRef](#)
8. Roberts WN, Hayes CW, Breitbach SA, Owen DS Jr. Dry taps and what to do about them: a pictorial essay on failed arthrocentesis of the knee. *Am J Med* 1996;100:461-4.
9. Esenyel C, Demirhan M, Esenyel M, Sonmez M, Kahraman S, Senel B, et al. Comparison of four different intra-articular injection sites in the knee: a cadaver study. *Knee Surg Sports Traumatol Arthrosc* 2007;15:573-7. [CrossRef](#)
10. Hermans J, Bierma-Zeinstra SM, Bos PK, Verhaar JA, Reijman M. The most accurate approach for intra-articular needle placement in the knee joint: a systematic review. *Semin Arthritis Rheum* 2011;41:106-15. [CrossRef](#)
11. Daley EL, Bajaj S, Bisson LJ, Cole BJ. Improving injection accuracy of the elbow, knee, and shoulder: does injection site and imaging make a difference? A systematic review. *Am J Sports Med* 2011;39:656-62. [CrossRef](#)
12. Gilliland CA, Salazar LD, Borchers JR. Ultrasound versus anatomic guidance for intra-articular and periarticular injection: a systematic review. *Phys Sportsmed* 2011;39:121-31. [CrossRef](#)
13. Cunnington J, Marshall N, Hide G, Bracewell C, Isaacs J, Platt P, et al. A randomized, double-blind, controlled study of ultrasound-guided corticosteroid injection into the joint of patients with inflammatory arthritis. *Arthritis Rheum* 2010;62:1862-9.
14. Iizuka M, Yao R, Wainapel S. Saphenous nerve injury following medial knee joint injection: a case report. *Arch Phys Med Rehabil* 2005;86:2062-5. [CrossRef](#)
15. Lockman LE. Practice tips. Knee joint injections and aspirations: the triangle technique. *Can Fam Physician* 2006;52:1403-4.
16. Hall S, Buchbinder R. Do imaging methods that guide needle placement improve outcome? *Ann Rheum Dis* 2004;63:1007-8. [CrossRef](#)