



Posterior tibial nerve as a tendon transfer for drop foot reconstruction: a devastating complication

Mehmet ARMANGIL¹, H. Çağdaş BASAT², S. Sinan BİLGİN¹

¹Department of Hand Surgery, Department of Orthopedics and Traumatology, Faculty of Medicine, Ankara University, Ankara, Turkey;

²Department of Orthopedics and Traumatology, Etimed Hospital, Ankara, Turkey

Iatrogenic peripheral nerve injuries can result from numerous medical procedures, particularly transection, stretching, compression, injections, heat, radiation, and the use of anticoagulant agents. Late diagnosis may lead to atrophy of the motor endplate and result in poor outcomes. We report a case in which the posterior tibial nerve was accidentally sectioned as the posterior tibial tendon for transfer to the anterior tibial tendon in the reconstruction of drop foot. This iatrogenic complication ultimately required foot amputation. Physicians must be aware of the anatomy of the posterior tibial nerve in order to avoid such complications.

Key words: Drop foot; iatrogenic nerve injury; posterior tibial nerve.

Iatrogenic nerve injuries are mostly seen in orthopedic surgery.^[1] The various operative and non-operative mechanisms of iatrogenic injury are well known and include transection, stretching, compression, injections, heat, radiation, and the use of anticoagulant agents.^[1,2] Iatrogenic transection of a major nerve during surgery is an avoidable problem and negative outcomes can be minimized with early recognition and treatment.^[1-4]

We report a patient whose posterior tibial nerve was accidentally sectioned as the posterior tibial tendon for transfer to the anterior tibial tendon in the reconstruction of drop foot, resulting in foot amputation.

Case report

A 34-year-old male patient referred to our clinic following inadequate surgical tarsal tunnel release. The patient underwent microneural surgery for the injury

of his right peroneal nerve after a stab wound 12 years prior to presentation. Motor and sensory recovery was not achieved. Ten years following the initial nerve repair, the patient underwent posterior tibial tendon transfer for reconstruction of the drop foot. Immediately following reconstruction, plantar sensory loss developed in the foot. First, compression of the posterior tibial nerve was suspected due to the proximity of the surgery site to the nerve and the patient was referred to rehabilitation. While partial dorsiflexion was achieved according to the referring surgeon, the patient claimed that dorsiflexion of the right foot was not achieved following tendon transfer. One year after the tendon reconstruction, hardly healing wounds developed on the plantar surface under the metatarsal heads of the right forefoot. Tarsal tunnel syndrome had been determined on electromyography (EMG) in the previous epicrisis. Tarsal tunnel release was attempted by the same surgeon and sufficient

Correspondence: H. Çağdaş Basat, MD. Özel Etimed Hastanesi, Ortopedi ve Travmatoloji Kliniği, Elvan Mah., 1934. Sok., No: 4, Etimesgut, Ankara, Turkey.

Tel: +90 505 – 772 14 89 e-mail: cagdasbasat@gmail.com

Submitted: October 25, 2012 **Accepted:** November 29, 2013

©2015 Turkish Association of Orthopaedics and Traumatology

Available online at

www.aott.org.tr

doi: 10.3944/AOTT.2015.3086

QR (Quick Response) Code



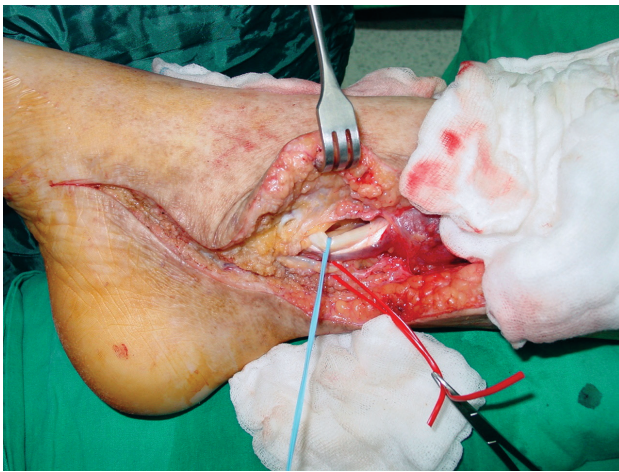


Fig. 1. Posterior tibial artery (red cord) and intact posterior tibial tendon (blue cord) exposed. [Color figure can be viewed in the online issue, which is available at www.aott.org.tr]

dissection was not performed due to the excessive scar tissue as reported in the epicrisis. The patient was referred to our clinic for further evaluation.

Physical examination on 14 December 2005 revealed an infected, purulent, 1x1 cm sized wound under the metatarsal heads on the plantar surface of the foot and significant sensory loss on the plantar surface. EMG was performed the following day and showed total denervation distal to the short branch of the posterior tibial nerve of the right tibial nerve.

Posterior tibial nerve exploration was performed. Under epidural anesthesia and tourniquet control, the previous incision was used to release the tarsal tunnel for exploration. The posterior tibial artery was found proximal to the tarsal tunnel and marked with a silicone loop. While the posterior tibial nerve was not located in

its natural position, the posterior tibial tendon was observed to be intact in its original position (Fig. 1) and dissection to the insertion of the tendon was performed to determine if it was intact. It was thought that the nerve had been accidentally transferred as the posterior tibial tendon. A second incision was then made in the posteromedial calf to explore the tibial nerve (Fig. 2a). The nerve was found proximally and followed distally (Fig. 2b) and found to cross from posterior to anterior from the anterior of the tibia and sutured to the insertion of the anterior tibial tendon (Fig. 3a). The nerve was then divided from the tendon and brought to its anatomic location for microneural repair (Figs. 3b and c). The medial and lateral plantar branches of the nerve could not be found distally for reconstruction due to excessive scar tissue and destructed anatomy. The case was considered to be an irreparable nerve lesion. After hemostasis, the wound was closed in an anatomic fashion and debridement was performed in the forefoot. There were no wound complications after the surgery and the patient was referred to the rehabilitation center for neuropathic foot management. In September 2009, long transtibial amputation was performed at a different clinic due to osteomyelitis and non-healing wounds of the foot. The patient currently walks using prosthesis.

Discussion

Treatment of iatrogenic nerve injuries is challenging as such injuries are often diagnosed late. Motor endplate atrophy leads to inferior results when reconstruction is performed more than 3 to 6 months after the nerve damage occurs. However, even immediate restoration of original function does not always result in satisfactory outcomes.^[3]

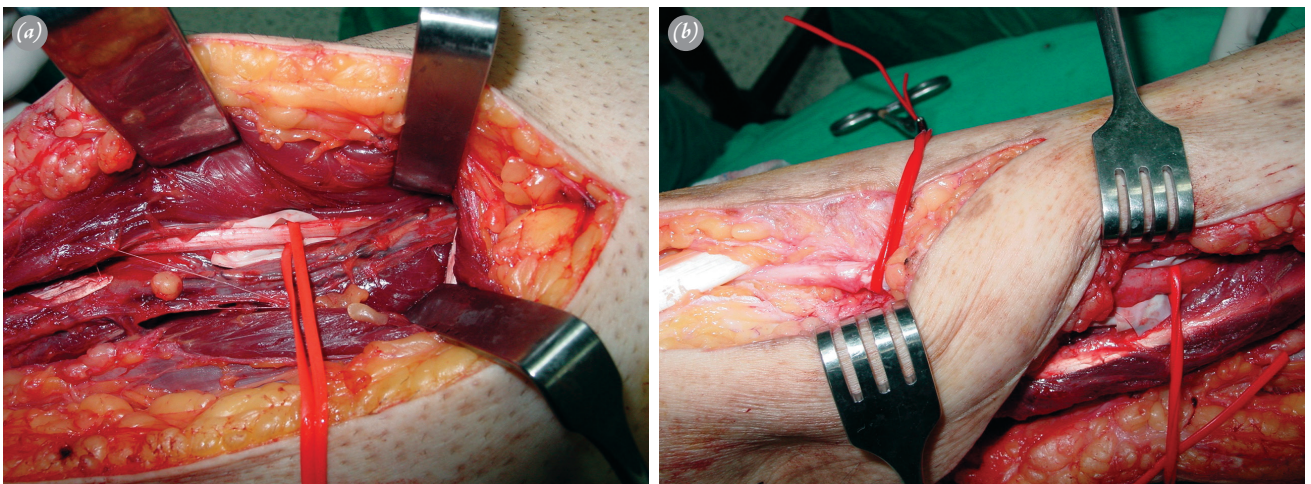


Fig. 2. (a) Tibial nerve (red cord) explored in the posteromedial calf. (b) Tibial nerve (red cords) followed distally by another incision. [Color figure can be viewed in the online issue, which is available at www.aott.org.tr]

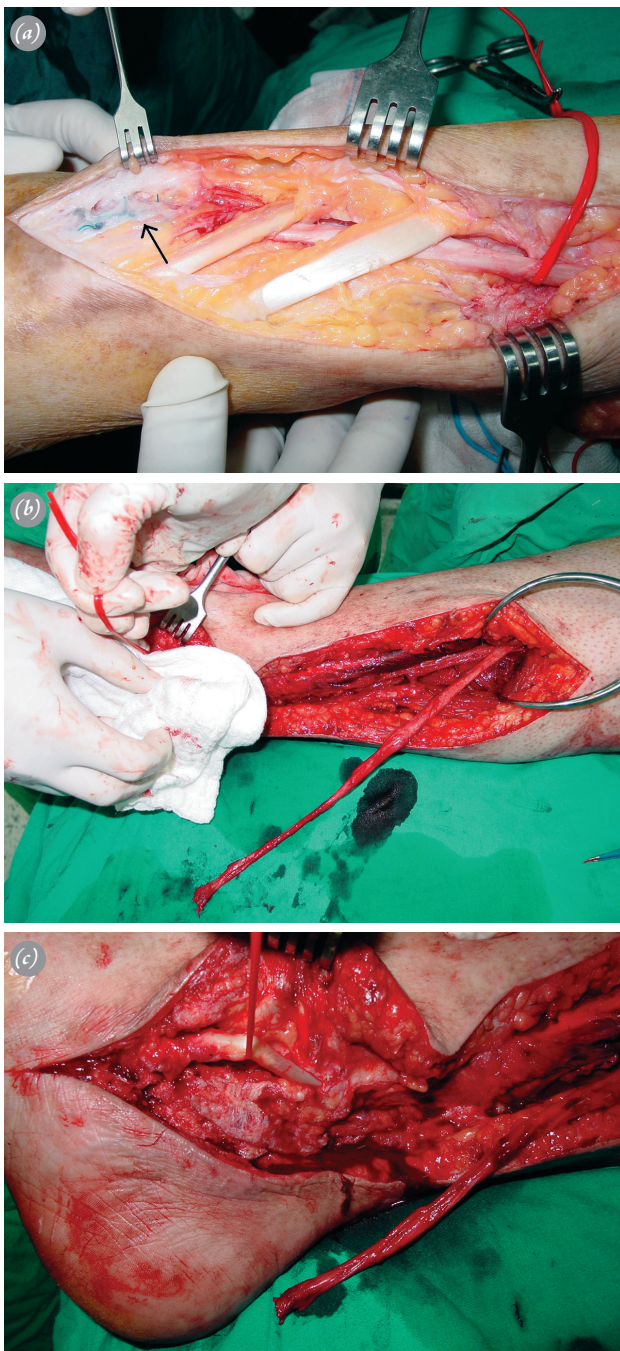


Fig. 3. (a) Tibial nerve is sutured (arrow) to the anterior tibial tendon. (b) The nerve is divided from where it was sutured. (c) Tibial nerve is brought back to its anatomic position. Red cord demonstrates the intact posterior tibial tendon. [Color figure can be viewed in the online issue, which is available at www.aott.org.tr]

The most frequent causes for nerve injuries are seen during orthopedic surgery for scapula dislocation and knee and hip prosthesis. Other causes are endoscopic carpal tunnel release, cervical lymph node biopsy, hematoma resulting from transaxillary angiography and

intramuscular injection. The spinal accessory nerve and brachial plexus are most frequently injured nerves during operation, with tibial nerve injuries rarely seen.^[1,3]

The tibial nerve is a major branch of the sciatic nerve and provides protective sensory supply to the foot and innervation of the posterior leg and intrinsic foot muscles. Injury of this nerve results in lack of foot or plantar flexion, loss of toe flexion and inversion and lack of protective sensation on the sole of the foot.^[5] The tibial nerve is located along with the tibial artery and vein, running through the leg medial and posterior to the tibia and the intermuscular septum, separating the anterior and posterior compartments. As the tibial nerve approaches the ankle, it courses inferior to the medial malleolus and becomes superficial, lying on the medial side of the ankle and then passing into the foot beneath the tarsal tunnel. The tibial nerve enters the tarsal tunnel between the overlying flexor retinaculum and the underlying tendon sheaths of the posterior tibia, flexor digitorum longus and flexor hallucis longus. The artery and vein are attached to these sheaths by the surrounding areolar tissues. At the ankle, the nerve divides into three branches; the medial calcaneal, medial plantar and lateral plantar nerves. This complex anatomy requires a great deal of attention during surgery to avoid complications.

Posterior tibial tendon transfer for the reconstruction of drop foot is widely used.^[6,7] Although we could not find a complication matching our case in the literature, 3 cases of tibial nerve mistakenly used as a tendon graft for plantaris tendon have been reported. Microsurgical reconstruction was performed in all 3 patients; motor recovery was not achieved in any and sensory recovery was poor.^[8] Kim et al.^[5] evaluated the results of 135 tibial nerve lesions. Of these, 79 were located at the level of the ankle and etiology was tarsal tunnel syndrome in 46, contusion with fracture in 19, contusion without fracture in 8 and other causes in 6. The authors reported good functional results. Appropriate treatment results in good functional outcomes in tibial nerve lesions. In our case, the destructed anatomy and excessive scar tissue made microneural repair impossible. However, if diagnosed earlier in the operation or just after, the result would have been better and probably would not have led to amputation.

In conclusion, during posterior tibial tendon transfer, the surgeon should follow the tendon to its insertion to avoid error due to the similar appearance of the tendon and nerve under tourniquet. For surgeons inexperienced in foot and ankle surgery, this case should be kept in mind to avoid such error.

Conflicts of Interest: No conflicts declared.

References

1. Kretschmer T, Antoniadis G, Braun V, Rath SA, Richter HP. Evaluation of iatrogenic lesions in 722 surgically treated cases of peripheral nerve trauma. *J Neurosurg* 2001;94:905-12. [CrossRef](#)
2. Birch R, Bonney G, Dowell J, Hollingdale J. Iatrogenic injuries of peripheral nerves. *J Bone Joint Surg Br* 1991;73:280-2.
3. Kömürçü F, Zwolak P, Benditte-Klepetko H, Deutinger M. Management strategies for peripheral iatrogenic nerve lesions. *Ann Plast Surg* 2005;54:135-9; discussion 140-2.
4. Khan R, Birch R. Latro-pathic injuries of peripheral nerves. *J Bone Joint Surg Br* 2001;83:1145-8. [CrossRef](#)
5. Kim DH, Ryu S, Tiel RL, Kline DG. Surgical management and results of 135 tibial nerve lesions at the Louisiana State University Health Sciences Center. *Neurosurgery* 2003;53:1114-25. [CrossRef](#)
6. Kiliç A, Parmaksizoğlu AS, Kabukçuoğlu Y, Bilgili F, Sökücü S. Extramembranous transfer of the tibialis posterior tendon for the correction of drop foot deformity. *Acta Orthop Traumatol Turc* 2008;42:310-5. [Article in Turkish] [CrossRef](#)
7. Vigasio A, Marcoccio I, Patelli A, Mattiuzzo V, Prestini G. New tendon transfer for correction of drop-foot in common peroneal nerve palsy. *Clin Orthop Relat Res* 2008;466:1454-66. [CrossRef](#)
8. McGeorge D, Sturzenegger M, Buchler U. Tibial nerve mistakenly used as a tendon graft. Reports of three cases. *J Bone Joint Surg Br* 1992;74:365-6.