



Effects of hyaluronic acid (Hyalonect) on callus formation in rabbits

Semih AYANOĞLU¹, Cem Zeki ESENYEL¹, Oktay ADANIR²,
Semih DEDEOĞLU³, Yunus İMREN³, Tuğçe ESEN⁴

¹Okmeydanı Training and Research Hospital, Department of Orthopedics and Traumatology, İstanbul, Turkey

²Bağcılar Training and Research Hospital, Department of Orthopedics and Traumatology, İstanbul, Turkey

³Bezmi Alem Vakıf University Faculty of Medicine Hospital, Department of Orthopedics and Traumatology, İstanbul, Turkey

⁴İstanbul University Cerrahpaşa Faculty of Medicine, Department of Pathology, İstanbul, Turkey

Objective: Bone fragment and graft stabilization are important during reconstructive surgery of cases with comminuted fractures and bone defects. We examined the effect of Hyalonect surgical mesh on the healing dynamics of metaphyseal bone defects created in rabbit tibiae.

Methods: Approximately 5-mm defects were created on the anterior aspect of the proximal tibial metaphysis of 80 male rabbits. The rabbits were randomly assigned to four groups: Group I, bone defects left alone (control group); Group II, bone defect covered with Hyalonect; Group III, bone defect filled with allograft; and Group IV, bone defect filled with allograft and covered with Hyalonect.

Results: No significant histological differences were noted between Groups II and III or Groups III and IV at 3 and 6 weeks. At 3 weeks, Groups II, III, and IV had significantly better healing than Group I ($p < 0.05$). In addition, Group IV showed significantly better healing than Group II at 3 and 6 weeks. At 6 weeks, only Group IV showed better healing than Group I ($p < 0.05$). Radiologically, Groups II, III, and IV showed better healing than Group I at 3 and 6 weeks ($p < 0.05$).

Conclusion: Hyalonect application and bone grafting significantly accelerated the healing process when used alone or together. Hyalonect application along with bone grafting resulted in better early radiological healing than bone grafting alone.

Keywords: Bone defect; fracture; fracture healing; hyalonect; hyaluronic acid; pseudoarthrosis.

Bone defects and comminuted fractures with periosteal loss are common in orthopedic trauma cases. The periosteum is critical for bone regeneration after injury because it guarantees a supply of blood and osteogenic progenitor cells to the underlying cortical bone.^[1] Conventional

strategies for the periosteal repair often require the use of biological tissues, protein-based glues, or synthetic membranes;^[1,2] however, these materials are not ideal for this purpose. A natural polymer matrix consisting of type-1 collagen can provide an excellent environment

Correspondence: Semih Ayanoğlu, MD. Okmeydanı Eğitim ve Araştırma Hastanesi, Ortopedi ve Travmatoloji Kliniği, Okmeydanı, İstanbul, Turkey.

Tel: +90 532 – 322 10 37 e-mail: semihayanoglu@gmail.com

Submitted: July 01, 2014 **Accepted:** September 28, 2014

©2015 Turkish Association of Orthopaedics and Traumatology

Available online at
www.aott.org.tr
doi: 10.3944/AOTT.2015.14.0231
QR (Quick Response) Code



for osteoinduction and osteogenesis; however, it has a low mechanical modulus and cannot provide sufficient structural cellular support.^[3,4] Naturally produced ceramics such as corals have good biocompatibility and appropriate mechanical properties, but the high dissolution rate has limited the clinical application of coralline calcium carbonate, especially when high load-bearing capacity is required. Synthetic calcium-based ceramics are also usually fragile when high porosity is needed.^[5,6] The resorption rate of bioactive inorganic materials such as glass and bioceramics can be modified with crystalline hyaluronic acid (HA), and this effect may persist for years following implantation.^[6] Biological polymers such as collagen have the potential risks of immunogenic reactions and disease transmission.^[6,7] In addition, there are concerns such as difficult sourcing, poor handling, and weak mechanical properties.^[6] Relative to bone, the mechanical properties of the current composites are poor.^[6]

Recent studies have demonstrated that HA aids in both soft tissue and bone regeneration.^[2–11,12] HA delays or decreases granulation tissue development.^[13] HA likely increases cell migration, proliferation, and differentiation at the operative site, and enhances extracellular matrix organization.^[1,2–11,14,15] Furthermore, it stimulates newly formed capillaries surrounding subcutaneous implants.^[13] When in close contact with bone, HA participates in bone morphogenesis^[16] and the early osteogenic events,^[17] modulating the effects of several cytokines and growth factors.^[18,19] HA also induces bone similar to osteogenic substrates such as calcitonin and bone morphogenic protein.^[8] In addition, it binds proteins crucial for wound healing such as fibrinogen, fibrin, fibronectin, and collagen.^[20]

Recently, Hyalonect® (Fidia Farmaceutici, Italy) was developed for use in orthopedics. Hyalonect is a knitted mesh composed of HYAFF®, a naturally occurring benzyl ester of HA, which is a constituent of the extracellular matrix. Hyalonect is a resorbable, suturable, biocompatible mesh that can be used as a periosteal substitute.^[1] It may be fixed to the operative site using sutures.

Considering the osteogenic and remodeling properties of HA, we hypothesized that the bone-healing rate of the allograft covered with Hyalonect would be augmented. Therefore, we aimed to compare the bone-healing rate of the allograft covered with Hyalonect and allograft alone in an experimental tibial defect model, both radiologically and histologically.

Materials and methods

Eighty adult male (8–10 months) white New Zealand rabbits weighing 2000–3000 g were included in the

study. We obtained approval from the Ethics Committee for the study. The rabbits were handled according to the guidelines of the Ethics Committee for animals used in experimental studies.

For preparing bone grafts, tibiae were harvested from two rabbits. The harvested grafts were stored in double plastic containers used for bone banking at -80°C . After 3 weeks, bone grafts were thawed before soft tissues and cartilage were removed. Using the finest grater in a standard bone mill, the graft was milled to 5-mm chips. Most cortical bone fragments were separated during the milling process. The processed graft was used as an allograft.

The rabbits were randomly assigned to four groups of 20 rabbits each: Group I, a bone defect was created and left to heal by themselves (control group). Group II, the cavities were covered with Hyalonect. Group III, the cavities were filled with allograft. Group IV, the cavities were filled with allograft and covered with Hyalonect. Ten rabbits in each group were sacrificed after 3 and 6 weeks.

First, a 22G catheter was inserted in the lateral auricular vein of each rabbit. Anesthesia was then induced by injecting 10 mg/kg of propofol. Intraoperatively, a 10-mg/ml propofol solution was infused at the rate of 30 ml/h as indicated. For creating the bone deformity, a 5-mm burr was passed through the whole cortical bone. A motor with a low revolution-per-minute value was used for cavity creation. Saline irrigation was used to prevent thermal bone necrosis during. The same burr was used to create 5-mm cavities in the anterior of the proximal tibial metaphysis (Figure 1). The cavities were filled with chips allograft. Hyalonect was cut according

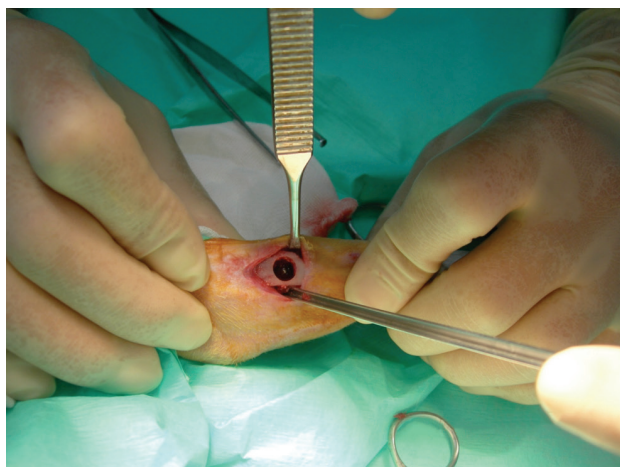


Fig. 1. A defect in the anterior aspect of the rabbit proximal tibial metaphysis. [Color figure can be viewed in the online issue, which is available at www.aott.org.tr]

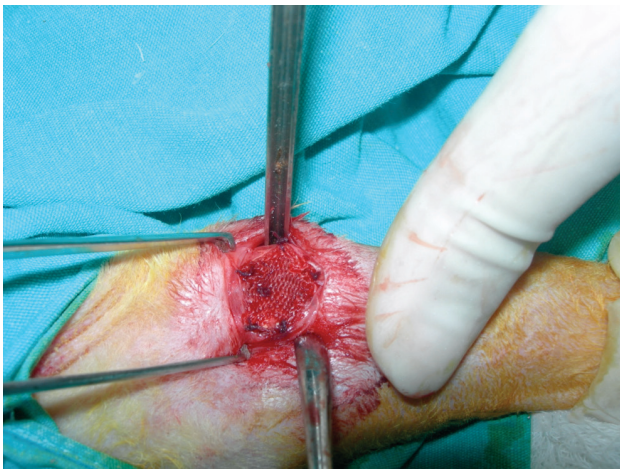


Fig. 2. Hyalonect after application. [Color figure can be viewed in the online issue, which is available at www.aott.org.tr]

to cavity size and sutured to the surrounding soft tissues around with 3–0 coated Vicryl (Figure 2). Afterward, the skin was closed with 2–0 silk. Postoperatively, the wound dressings were changed for 1 week. The rabbits were examined daily for wound healing and complications, and they were administered the same diet. At 3 and 6 weeks, 10 rabbits from each group were sacrificed using high-dose sodium phenobarbital and bone healing was radiologically and histologically assessed.

Bone segments were removed, cut into 5- μ m-thick cross-sections, fixed in formalin, decalcified with acid, and embedded in paraffin wax. After the sections were stained with hematoxylin–eosin and van Gieson–Hansen stains, they were examined under a light microscope by the same pathologist (Figure 3). Emery's histopatho-

logical healing criteria were used for histopathological evaluation^[21] (Table 1).

Radiographs of the tibia were obtained to evaluate new bone formation in the defects (Figure 4) using the scoring system developed by Yasko et al. (Table 2).^[22]

Kruskal–Wallis variant analyses were used to identify differences among the group scores. Mann–Whitney U-tests were then used to identify significant differences. The Wilcoxon rank test was used to detect significant differences within each group. The level of statistical significance was set at $p < 0.05$. The statistical analyses were performed using SPSS for Windows version 10.0.1.

Results

Histopathological Evaluation at 3 weeks showed better healing in Groups II, III, and IV than in Group I ($p < 0.05$). Group IV showed better healing than Group II ($p < 0.05$). No significant differences were found between Groups II and III or between Groups III and IV ($p > 0.05$). At 6 weeks, a significant difference remained between Groups I and IV ($p < 0.05$). Group IV showed better healing than Group II ($p < 0.05$). No significant differences were found between Groups I and II, between Groups I and III, between Groups II and III, or between Groups III and IV ($p > 0.05$) (Table 3).

Radiological Evaluation at 3 weeks showed better healing in Groups II, III, and IV than in Group I ($p < 0.05$). No significant differences were found between Groups II and III or between Groups II and IV ($p > 0.05$). Better radiological healing was observed in Group IV than in Group III ($p < 0.05$). At 6 weeks, Groups II, III,

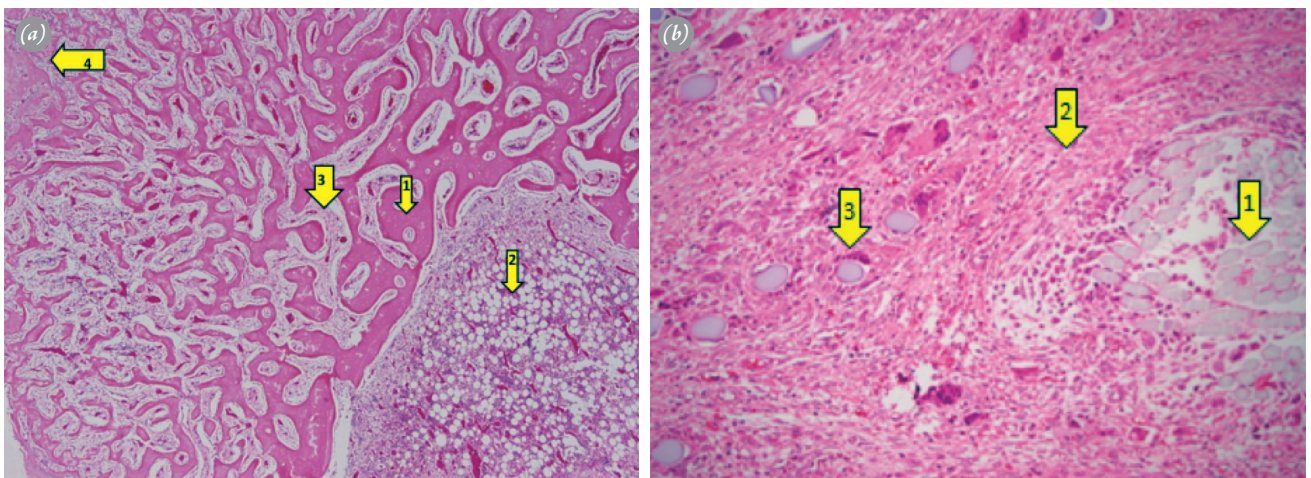


Fig. 3. (a) Images of the hematoxylin–eosin-stained samples, which show the foreign materials (Hyalonect), osteoblastic activity, and new bone formation under a light microscope (score was 6). (b) Images of the hematoxylin–eosin-stained samples, which show the foreign materials (Hyalonect), foreign body reaction, and fibrosis and new bone formation under a light microscope (score was 6). [Color figures can be viewed in the online issue, which is available at www.aott.org.tr]

Table 1. Emery's histological healing criteria.

Score (points)	Tissue present
0	Empty cavity
1	Fibrous tissue only
2	More fibrous tissue than fibrocartilage
3	More fibrocartilage than fibrous tissue
4	Fibrocartilage only
5	More fibrocartilage than bone
6	More bone than fibrocartilage
7	Bone only

Table 2. Radiological healing criteria.

Score	Radiological appearance
0	No callus
1	New bone fills <25% of the defect
2	New bone fills 25%–50% of the defect
3	New bone fills 50%–75% of the defect
4	New bone fills >75% of the defect
5	New bone is a solid contiguous mass that fills the entire defect

and IV showed better radiological healing than Group I ($p < 0.05$). No significant differences were found between Groups II and III, between Groups II and IV, or between Groups III and IV ($p > 0.05$) (Table 4).

Discussion

The structural and functional integrity of the periosteum profoundly influences subsequent osseous regeneration. The periosteum is a membrane tightly bound to the bone surface. It is composed of fibrous and elas-

tic tissues and has blood vessels containing osteoblasts and progenitor cells. The periosteum can be destroyed by moderate and severe trauma to the bone. It also mechanically contributes to the resistance to fractures and is critical in post-traumatic bone regeneration.^[1,23] A periosteal defect may lead to the dispersion of engrafted bone substitutes or favor the adhesion of adjacent soft tissues to the underlying bone. Consequently, graft stability is compromised and pain may result. In addition, in comminuted fracture cases, it is frequently necessary to maintain the graft or bone fragments in position.^[1] Hyalonect is a membrane substitute that was designed to participate in periosteal regeneration.^[1,23] Rhodes et al.^[1] reported that Hyalonect is capable of restoring the function of damaged connective tissues such as the periosteum without interfering with the natural tissue repair process. The current results showed that Hyalonect and grafting significantly enhance the healing process when used alone or together. The use of both Hyalonect and grafting together resulted in better early radiological healing than bone grafting alone.

Aslan et al. compared the effects of autologous bone grafting with or without HA in a rabbit tibia defect model and reported that HA requires an osteoconductive scaffold to be effective.^[2] The addition of HA led to higher bone formation scores at each time period in their study.^[2] Conversely, Oakes et al.^[23] found no signs of radiological healing, enchondral ossification, and only minimal periosteal ossification of defects treated solely with HA in a rat femoral defect model. Maus et al. reported similar findings in a sheep model.^[24] In the present study, Hyalonect was applied to the defects in group

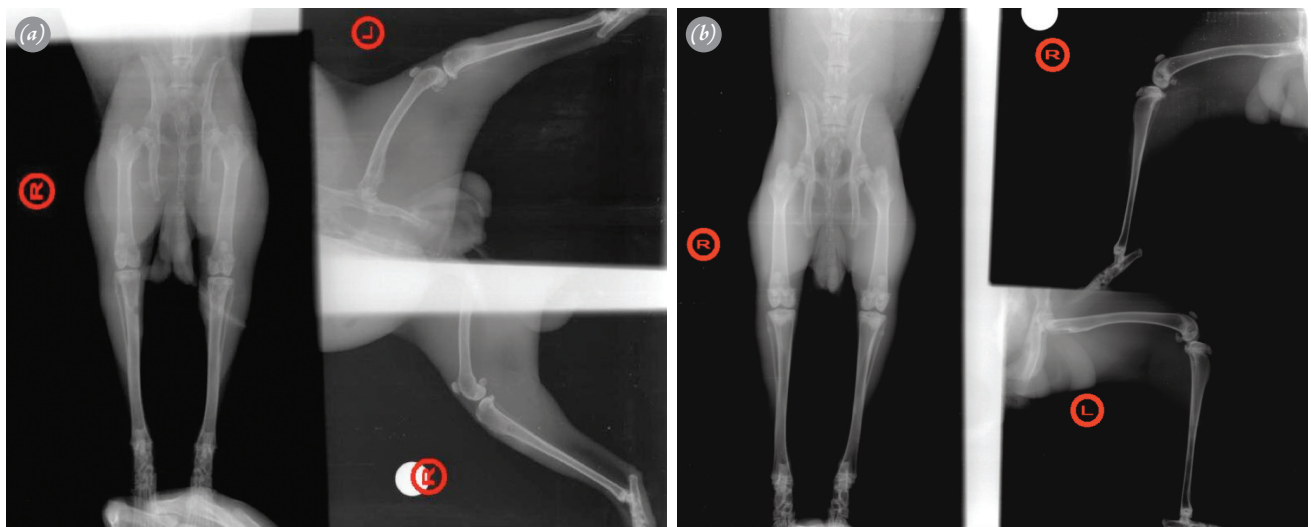


Fig. 4. (a) Radiological appearance at 3 weeks of the defect covered with Hyalonect. (b) Radiological appearance at 6 weeks of the defect filled with graft. [Color figure can be viewed in the online issue, which is available at www.aott.org.tr]

Table 3. Statistical comparison of the histological results.

Time (week)	Group 1		Group 2		Group 3	
	3	6	3	6	3	6
Group 2						
3	0.0372					
6		0.6242				
Group 3						
3	0.0160		0.0809			
6		0.215		0.2330		
Group 4						
3	0.0157		0.0463		0.4386	
6		0.0180		0.0127		1.000

Differences between groups are shown with p values.

Table 4. Statistical comparison of the radiological results.

Time (week)	Group 1		Group 2		Group 3	
	3	6	3	6	3	6
Group 2						
3	0.0059					
6		0.0099				
Group 3						
3	0.010		1.000			
6		0.0058		0.6008		
Group 4						
3	0.0061		0.1514		0.05	
6		0.0015		0.0856		0.207

Differences between groups are shown with p values.

II, which showed better healing than group I. Moreover, when a graft and Hyalonect were both applied, the callus formation was better in group I than in the other groups at 3 weeks.

Several authors have suggested that application of HA is beneficial when it is used as a structured scaffold, in the form of HA sponges (HYAFF 11) or in combination with osteoconductive biomaterials such as hydroxyapatite.^[25–28] On the other hand, the osseointegration of bone substitutes is reported to depend on the pore size of the substitutes.^[28] In the current study we applied HA as a scaffold. This scaffold is composed of HYAFF, a benzyl ester of HA. As a scaffold, it allows for rapid cell colonization and neovascularization at the application site.

Previous studies have examined the effects of various compounds with different molecular weights on osteogenesis. In one study, low-molecular-weight HA accelerated osteogenesis in vitro in a rat bone marrow ablation model.^[29] In another study, however, high-molecular-weight HA increased bone formation compared with

untreated controls.^[1] Therefore, the optimal molecular weight of HA is not clear. The Hyalonect membrane used in the current study was constructed from fiber of HYAFF 11, in which the carboxyl groups of the D-glucuronic acid units of HA are completely esterified with benzyl groups. HYAFF 11 is one of the most analyzed HYAFF polymers, from both the physicochemical and biological viewpoints. They are produced starting from HA of about 200000 Daltons.^[30]

In the present study, 8–10-month-old rabbits were used. The bone defects were made with the same burr to obtain similarly sized defects. The tibial defect, a standardized full-thickness defect that will not heal during specific extended observation periods, has been used successfully to evaluate bone regeneration in connection with different biomaterials. Compared with other experimental bone defects, it is a convenient model for studying bone regenerative materials because of its effective accessibility and the lack of fixation requirements.^[31–34] An experimental osseous injury performed to examine repair mechanisms should be wide enough to preclude

spontaneous healing. Therefore, the non-regeneration threshold of bone was investigated in various models to determine the critical-sized defect, i.e., the smallest intraosseous wound in a specific bone and animal species that will not heal spontaneously during the lifetime of the animal.^[31,35]

In clinical practice, the repair of large bone defects is generally achieved using osteogenic fillers such as demineralized bone matrix often with mineral additives such as calcium sulfate for osteoconduction. Furthermore, synthetic graft substitutes can be used. The defect closure method is important for successful surgical repair. In addition, clinical and experimental data indicate that the periosteum plays an important role in bone healing and remodeling.^[1] Rhodes et al.^[1] used Hyalocort surgical mesh as a periosteal replacement scaffold in a canine humeral drill-hole model to limit the migration of various bone graft materials, including autologous corticocancellous bone fragments, demineralized bone matrix, and calcium sulfate putty. Histological studies showed that the mesh prevented extravasation of the materials from the bone defects and provided a contained environment for tissue healing. Rhodes et al. also showed that the mesh was consistently repopulated with viable host cells and prevented fibrous tissue penetration of the defects, allowing restoration of a new functional bone marrow environment.^[1] In the previous study, extravasation of the grafts covered with Hyalocort was not observed.

The current study has several limitations. First, the experimental time frame was not long enough. The results should have been evaluated at the 2nd, 3rd, 6th, 8th, 12th, and 24th week postoperatively to better observe the effect of Hyalocort on bone integration in a rabbit tibial defect. Second, further studies should be performed to compare Hyalocort with other bone substitutes.

In conclusion, Hyalocort is suitable for restoring tissue continuity whenever the periosteal membrane is structurally impaired or inadequate. The results show that Hyalocort or grafting significantly speeds the healing process. The use of both Hyalocort and grafting together resulted in better early radiological healing than bone grafting alone, especially in the short term (at 3 weeks).

Conflicts of Interest: No conflicts declared.

References

- Rhodes NP, Hunt JA, Longinotti C, Pavesio A. In vivo characterization of Hyalocort, a novel biodegradable surgical mesh. *J Surg Res* 2011;168:31–8. [CrossRef](#)
- Aslan M, Simsek G, Dayi E. The effect of hyaluronic acid-supplemented bone graft in bone healing: experimental study in rabbits. *J Biomater Appl* 2006;20:209–20. [CrossRef](#)
- Fröhlich M, Grayson WL, Wan LQ, Marolt D, Drobnic M, Vunjak-Novakovic G. Tissue engineered bone grafts: biological requirements, tissue culture and clinical relevance. *Curr Stem Cell Res Ther* 2008;3:254–64. [CrossRef](#)
- Mizuno M, Shindo M, Kobayashi D, Tsuruga E, Amemiya A, Kuboki Y. Osteogenesis by bone marrow stromal cells maintained on type I collagen matrix gels in vivo. *Bone* 1997;20:101–7. [CrossRef](#)
- Grundel RE, Chapman MW, Yee T, Moore DC. Autogenic bone marrow and porous biphasic calcium phosphate ceramic for segmental bone defects in the canine ulna. *Clin Orthop Relat Res* 1991;266:244–58.
- Stevens MM. Biomaterials for bone tissue engineering. *Materials today* 2008;11:18–25. [CrossRef](#)
- Schwartzmann M. Use of collagen membranes for guided bone regeneration: a review. *Implant Dent* 2000;9:63–6.
- Pirnazar P, Wolinsky L, Nachmani S, Haake S, Pilloni A, Bernard GW. Bacteriostatic effects of hyaluronic acid. *J Periodontol* 1999;70:370–4. [CrossRef](#)
- Kennedy CI, Diegelmann RF, Haynes JH, Yager DR. Pro-inflammatory cytokines differentially regulate hyaluronan synthase isoforms in fetal and adult fibroblasts. *J Pediatr Surg* 2000;35:874–9. [CrossRef](#)
- Nandi A, Estess P, Siegelman MH. Hyaluronan anchoring and regulation on the surface of vascular endothelial cells is mediated through the functionally active form of CD44. *J Biol Chem* 2000;275:14939–48. [CrossRef](#)
- Watanabe H, Cheung SC, Itano N, Kimata K, Yamada Y. Identification of hyaluronan-binding domains of aggrecan. *J Biol Chem* 1997;272:28057–65. [CrossRef](#)
- Pilloni A, Bernard GW. The effect of hyaluronan on mouse intramembranous osteogenesis in vitro. *Cell Tissue Res* 1998;294:323–33. [CrossRef](#)
- West DC, Hampson IN, Arnold F, Kumar S. Angiogenesis induced by degradation products of hyaluronic acid. *Science* 1985;228:1324–6. [CrossRef](#)
- Wight TN, Kinsella MG, Qvarnström EE. The role of proteoglycans in cell adhesion, migration and proliferation. *Curr Opin Cell Biol* 1992;4:793–801. [CrossRef](#)
- Fraser JR, Laurent TC, Laurent UB. Hyaluronan: its nature, distribution, functions and turnover. *J Intern Med* 1997;242:27–33. [CrossRef](#)
- Toole BP. Hyaluronate and hyaluronidase in morphogenesis and differentiation. *Amer Zool* 1973;13:1061–5. [CrossRef](#)
- Handley CJ, Lowther DA. Inhibition of proteoglycan biosynthesis by hyaluronic acid in chondrocytes in cell culture. *Biochim Biophys Acta* 1976;444:69–74. [CrossRef](#)
- Boyce DE, Thomas A, Hart J, Moore K, Harding K. Hyaluronic acid induces tumour necrosis factor-alpha production by human macrophages in vitro. *Br J Plast Surg* 1997;50:362–8. [CrossRef](#)

19. Sasaki T, Watanabe C. Stimulation of osteoinduction in bone wound healing by high-molecular hyaluronic acid. *Bone* 1995;16:9–15. [CrossRef](#)
20. Stern M, Schmidt B, Dodson TB, Stern R, Kaban LB. Fetal cleft lip repair in rabbits: histology and role of hyaluronic acid. *J Oral Maxillofac Surg* 1992;50:263–9. [CrossRef](#)
21. Emery SE, Brazinski MS, Koka A, Bensusan JS, Stevenson S. The biological and biomechanical effects of irradiation on anterior spinal bone grafts in a canine model. *J Bone Joint Surg Am* 1994;76:540–8.
22. Yasko AW, Lane JM, Fellingner EJ, Rosen V, Wozney JM, Wang EA. The healing of segmental bone defects, induced by recombinant human bone morphogenetic protein (rh-BMP-2). A radiographic, histological, and biomechanical study in rats. *J Bone Joint Surg Am* 1992;74:659–70.
23. Oakes DA, Lee CC, Lieberman JR. An evaluation of human demineralized bone matrices in a rat femoral defect model. *Clin Orthop Relat Res* 2003;413:281–90. [CrossRef](#)
24. Maus U, Andereya S, Gravius S, Siebert CH, Ohnsorge JA, Niedhart C. Lack of effect on bone healing of injectable BMP-2 augmented hyaluronic acid. *Arch Orthop Trauma Surg* 2008;128:1461–6. [CrossRef](#)
25. Hunt DR, Jovanovic SA, Wikesjö UM, Wozney JM, Bernard GW. Hyaluronan supports recombinant human bone morphogenetic protein-2 induced bone reconstruction of advanced alveolar ridge defects in dogs. A pilot study. *J Periodontol* 2001;72:651–8. [CrossRef](#)
26. Kim HD, Valentini RF. Retention and activity of BMP-2 in hyaluronic acid-based scaffolds in vitro. *J Biomed Mater Res* 2002;59:573–84. [CrossRef](#)
27. Solchaga LA, Dennis JE, Goldberg VM, Caplan AI. Hyaluronic acid-based polymers as cell carriers for tissue-engineered repair of bone and cartilage. *J Orthop Res* 1999;17:205–13. [CrossRef](#)
28. Gauthier O, Bouler JM, Aguado E, Pilet P, Daculsi G. Macroporous biphasic calcium phosphate ceramics: influence of macropore diameter and macroporosity percentage on bone ingrowth. *Biomaterials* 1998;19:133–9. [CrossRef](#)
29. Sasaki T, Watanabe C. Stimulation of osteoinduction in bone wound healing by high-molecular hyaluronic acid. *Bone* 1995;16:9–15. [CrossRef](#)
30. Campoccia D, Doherty P, Radice M, Brun P, Abatangelo G, Williams DF. Semisynthetic resorbable materials from hyaluronan esterification. *Biomaterials* 1998;19:2101–27. [CrossRef](#)
31. Schmitz JP, Hollinger JO. The critical size defect as an experimental model for craniomandibulofacial nonunions. *Clin Orthop Relat Res* 1986;205:299&308.
32. de Brito Bezerra B, Mendes Brazão MA, de Campos ML, Casati MZ, Sallum EA, Sallum AW. Association of hyaluronic acid with a collagen scaffold may improve bone healing in critical-size bone defects. *Clin Oral Implants Res* 2012;23:938–42. [CrossRef](#)
33. Najjar TA, Kahn D. Comparative study of healing and remodeling in various bones. *J Oral Surg* 1977;35:375–9.
34. Aaboe M, Pinholt EM, Hjørtting-Hansen E. Healing of experimentally created defects: a review. *Br J Oral Maxillofac Surg* 1995;33:312–8. [CrossRef](#)
35. Kilborn SH, Trudel G, Uhthoff H. Review of growth plate closure compared with age at sexual maturity and lifespan in laboratory animals. *Contemp Top Lab Anim Sci* 2002;41:21–6.