



# Effect of platelet-rich plasma for treatment of Achilles tendons in free-moving rats after surgical incision and treatment

Serdar YÜKSEL<sup>1</sup>, Oktay ADANIR<sup>2</sup>, Muhammet Zeki GÜLTEKİN<sup>3</sup>, Aysel CAĞLAR<sup>4</sup>,  
Bedri Onur KÜÇÜKYILDIRIM<sup>5</sup>, Mehmet Akif GÜLEÇ<sup>2</sup>, Ender ALAGÖZ<sup>2</sup>

<sup>1</sup>Trabzon Kanuni Training and Research Hospital, Department of Orthopedics and Traumatology, Trabzon, Turkey

<sup>2</sup>Bağcılar Training and Research Hospital, Department of Orthopedics and Traumatology, İstanbul, Turkey

<sup>3</sup>Şanlıurfa Balıklıgöl State Hospital, Department of Orthopedics and Traumatology, Şanlıurfa, Turkey

<sup>4</sup>Bağcılar Training and Research Hospital, Department of Pathology, İstanbul, Turkey

<sup>5</sup>Yıldız Technical University, Department of Mechanical Engineering, İstanbul, Turkey

**Objective:** The purpose of this study is to investigate, both histopathologically and biomechanically, the effect of platelet-rich plasma (PRP) on surgically repaired Achilles tendon rupture recovery in rats.

**Methods:** The study included 25 17-month-old male Sprague-Dawley rats with an average weight of 500–550 g. Five rats were used as donors, while 20 rats were separated as PRP group (n=10) and control group (n=10). The Achilles tendons of the rats were cut transversely, and PRP was administered to the PRP group, while the control group received serum physiologically to create the same surgical effect. In previous studies, it was shown that this serum does not affect tendon recovery. Fifteen and 30 days post-treatment, the rats were sacrificed, and their Achilles tendons were extracted and examined histopathologically and biomechanically.

**Results:** Based on the obtained findings, it was observed that the histopathologic Movin and Bonar scores of PRP group on the 15<sup>th</sup> and 30<sup>th</sup> day post-treatment were significantly lower than those of the control group (p=0.019, p=0.017, respectively), while no significant difference was found in maximum force (Fmax) values in biomechanical measures on the 15<sup>th</sup> and 30<sup>th</sup> day post-treatment.

**Conclusion:** It is thought that PRP use in Achilles tendon ruptures positively affects histopathological recovery in the early period, but that it does not produce the same biomechanical effect. We believe that PRP use for qualified tendon recovery is histopathologically beneficial.

**Keywords:** Achilles tendon injuries; biomechanics; histopathology; platelet-rich plasma; rat.

The Achilles tendon is the thickest and most powerful tendon in the human body.<sup>[1]</sup> Achilles tendon injury prevalence is 1/10.000, but despite new developments and

techniques in its treatment, it is still a serious problem in middle-age adults and athletes due to its long recovery time and high rerupture rate.<sup>[2]</sup> In the last decade, plate-

**Correspondence:** Serdar Yüksel, MD. Trabzon Kanuni Eğitim ve Araştırma Hastanesi, Ortopedi ve Travmatoloji Kliniği, Trabzon, Turkey.

Tel: +90 462 – 341 56 56 e-mail: serdar84yukse@gmail.com

**Submitted:** December 28, 2014 **Accepted:** March 28, 2015

©2015 Turkish Association of Orthopaedics and Traumatology

Available online at  
www.aott.org.tr  
doi: 10.3944/AOTT.2015.15.0028  
QR (Quick Response) Code



let-rich plasma (PRP) practice came into use, in addition to existing treatments, and its prevalence has increased gradually. Studies in the field suggest that the platelets interact with leucocytes and endothelial cells and provide autoactivation with autocrine and paracrine effects, as a result of which inflammatory response emerges, and situations such as chemotaxis, atherothrombosis, coagulation, and cellular differentiation occur.<sup>[3–6]</sup>

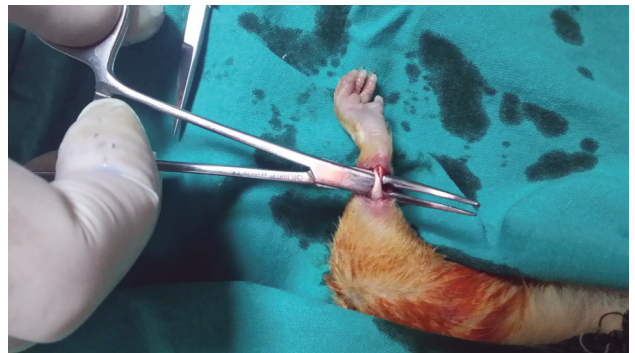When compared with whole blood, PRP contains a much greater concentration of growth factor (GF) and other glycoproteins. The effectiveness of PRP depends on the dose, concentration, and technique by which it is obtained.<sup>[7]</sup> PRP obtained by current techniques has a richer platelet count by 300–700%, and its platelet number is  $>1.000.000$  platelet/ $\mu\text{l}$ . The concentration increase in this platelet enables GF concentration increase in damaged tissue, which increases the injury recovery potential.<sup>[8]</sup>

Robert and Sporn<sup>[9]</sup> and Marx et al.<sup>[10,11]</sup> showed that the primary responsible factors in cell proliferation increase, collagen production in high density and quantity, angiogenesis and cellular differentiation were GFs with high density within PRP. As a result of the enzymatic analyses, when compared with whole blood, it was found that transforming growth factor beta (TGF- $\beta$ ) was 7 times denser, platelet-derived growth factor (PDGF) was 30 times denser, and epidermal growth factor (EGF) was 10 times denser.<sup>[12]</sup> However, studies with contradictory results—that GF affects recovery negatively<sup>[13]</sup>—and the insufficient number of studies on the effect of PRP limit the current use of PRP.

The purpose of our study is to investigate whether local use of PRP in Achilles tendon repairs is beneficial by investigating rat models on this issue in the literature. Our hypothesis was that PRP practice in rats, in tandem with surgery, would have positive effects on Achilles tendon recovery, both histopathologically and biomechanically.

## Materials and methods

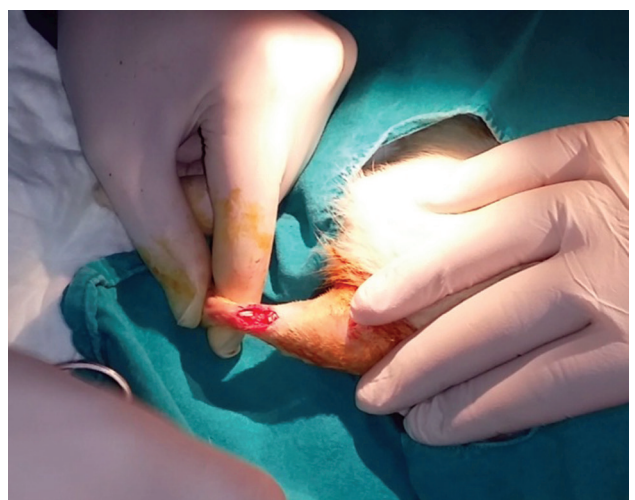Consent was obtained from the local ethical board before beginning the project. The study included 25 17-month-old 25 Sprague-Dawley male rats with an average weight of 500–550 g. The rats were fed standard rodent food ad libitum in 22°C in a dark environment for 12 hours. Five rats were used as donors, while 20 rats were separated as PRP group and control group. The rats were taken into surgery under 60 mg/kg intraperitoneal ketamine-hydrochloride (HCl) and 5 mg/kg intraperitoneal xylazine anesthesia in sterile conditions. Thirty min prior to surgery, 8 mg/kg subcutaneous antibiotic prophylaxis with gentamicin was administered. Within the first 24 hours



**Fig. 1.** Achilles tendon exploration. [Color figure can be viewed in the online issue, which is available at [www.aott.org.tr](http://www.aott.org.tr)]

postsurgery, carprofen 3–5 mg/kg was administered subcutaneously to control pain. After shaving the right lower extremity of the rats and painting the region with povidone-iodine (BatticonR, Adeka Laboratories, Istanbul, Turkey) and covering it with sterile green drape, the Achilles tendons received a nearly 2-cm longitudinal incision, exposing the tendon (Figure 1). A transverse cut was made in the 4–5 mm proximal of the sticking place of the Achilles tendon to calcaneus with a Bisturi No. 11 scalpel (Figure 2). The incised tendon was restitched with atraumatic PDO II 4/0 (Boz, Ankara, Turkey) by Kessler<sup>[14]</sup> method.

On average, 5 cc intracardiac blood was taken from the 5 rats in the donor group under high dose anesthesia, after which they were decapitated. The blood was taken by injectors with 3.8% sodium citrate, diluted by 1/10. By using Smith&Nephew Prosys PRS (PRP) bio kit (Prodizen, Inc., Seoul, South Korea) and table-type VS-5000i2 centrifuge device (Unity Medica, Sandwich,



**Fig. 2.** Transverse cut from the 4–5 mm proximal to the sticking place of Achilles tendon. [Color figure can be viewed in the online issue, which is available at [www.aott.org.tr](http://www.aott.org.tr)]

United Kingdom), 1 cc PRP was obtained after 3-min centrifuge at 3.000 rpm. The obtained PRP was counted by biochemistry analyzer (ADVIA® 2120i, Siemens Healthcare, Erlangen, Germany), and the platelet number was found to be  $4.500 \times 10^3 / \mu\text{L}$ . It was observed that at least 5–6 times more platelets were obtained from the average blood by means of this measurement. The samples were incubated at 4°C for 2 hours until a blood clot formed, and the obtained PRP was transferred into tubes of 96  $\mu\text{L}$  through a micropipette. Immediately before the application, the platelets were activated by adding 16  $\mu\text{L}$  of 10%  $\text{CaCl}_2$  to each tube and then applied to the repair region through a micropipette. In total, 112  $\mu\text{L}$  serum physiologic was injected to the repair region of the rats the in the control group, and the wound was closed with 3/0 propilen (Dogsan, Trabzon, Turkey) under sterile conditions. After they had been kept in isolation in conventional Type 2 cages for the first postoperative 24 hours, the rats were observed in conventional Type 4 cages for the second postoperative day, with 5 rats in each cage. The conventional cages included a minimum base area for each rat of 350  $\text{cm}^2$ , height of 18 cm, and plastic base and sides, with the upper part covered by wire cloth. Postoperative immobilization was not applied to the rats.

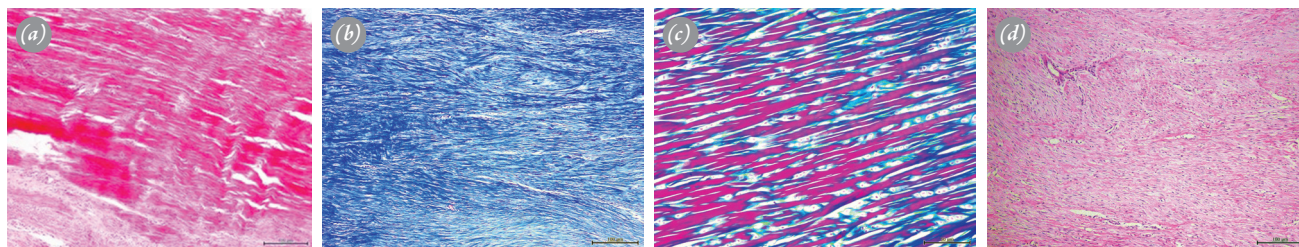
On the 15<sup>th</sup> and 30<sup>th</sup> days post-treatment, the rats were sacrificed with 10 mg/kg xylazine and 90 mg/kg ketamine-HCl. The repaired right Achilles tendons were cut from the connection places on the calcaneus, and femoral condyles and were extracted. Care was taken not to extract the plantaris tendon together with the Achilles tendon, which may affect biomechanical measures. All samples were assigned a number. Biomechanical measurement and histopathologic evaluation were made blind as to which group each sample came from.

The samples were assessed histopathologically by

a single pathologist. After being fixed in a 10% formaldehyde solution of 20 ml for 24 hours, 4 samples from each group were macroscopically taken into cassettes and then dehydrated in a tissue tracking device by being passed through alcohol, acetone, xylene, and paraffin phases, after which paraffin blocking was conducted. By taking cuts of 4  $\mu\text{m}$ , each block was painted with hematoxylin and eosin (HE), Masons trichrome (MT), and alcian blue (pH 2.5). Covering solution was dripped on the painted lames, and they were closed with lamellas. A BX51TF (Olympus, Tokyo, Japan) light microscope was used in the examination. Assessments were made with Movin semiquantitative ranking scale and Bonar semiquantitative scale.<sup>[14]</sup>

In Movin semiquantitative scale, 8 variables were assessed: 1) fiber structure, 2) fiber sequence, 3) curvature of nuclei, 4) cellularity regional variations, 5) vasculature growth, 6) reduction of collagen dyeability, 7) hyalinization, and 8) glycosaminoglycans (GAGs). The first 7 variables were assessed with HE dyed lames, while the 8<sup>th</sup> variable with GAG content was assessed with alcian blue (pH 2.5) dyed lames (Figures 3a–d). Each variable was scored on a 4-point scale between 0–3: 0: Normal; 1: Mild abnormal; 2: Abnormal; 3: Distinctly abnormal. Total semiquantitative histological score was assigned between 0 (normal tendon) and 24 (most severe abnormality). In Bonar scoring, 4 variables were assessed: 1) tenocytes, 2) ground material, 3) collagen, and 4) vascularity. Each variable was scored on a 4-point scale between 0–3: 0: Normal; 1: Mild abnormal; 2: Abnormal; 3: Distinctly abnormal. Total score was assigned between 0 (normal tendon) and 12 (most severe abnormality). The low Bonar and Movin scores show that recovery is good histopathologically, while its height means it is bad.

The samples used in the biomechanical study were



**Fig. 3.** (a) PRP group, 1 month post-treatment, x100, HE. Nucleus in the tenocytes is observed in more ovoid way, while cytoplasm cannot be selected. There is at least 1 capillary set in each 10 growing area. The collagen fiber dispersion is tight; well-bordered and bright homogenous polarization pattern is prominent. (b) PRP group, 1 month post-treatment, x100, MT. The collagen fiber dispersion is tight; well-bordered and homogenous polarization pattern is prominent. (c) Healthy tendon, x200, MT. The collagen fiber dispersion is tight; well-bordered and bright homogenous polarization pattern is prominent. (d) Control group, 15<sup>th</sup> day post-treatment, x100, HE. The nucleus in tenocytes is rounded and slightly widened, and the cytoplasm is also slightly visible. In each of 10 large enlargement areas, there are more than 2 capillary clusters. Loss and separation of boundaries of collagen fibers bundles are observable. [Color figure can be viewed in the online issue, which is available at [www.aott.org.tr](http://www.aott.org.tr)]

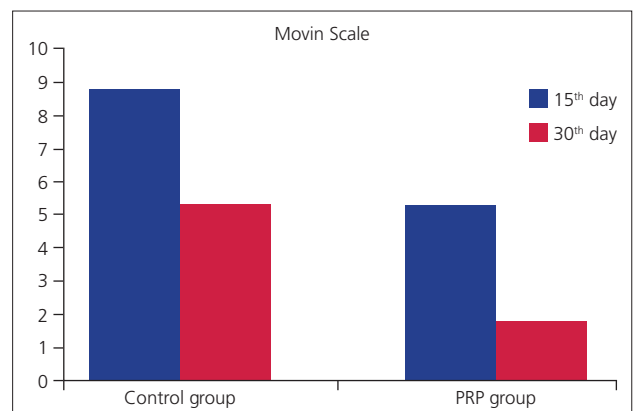


**Fig. 4.** (a) Mecmesin mechanical testing device and specially designed gripper jaws without nails. (b) Status of the tendon while plugged into the device during tensile test. [Color figure can be viewed in the online issue, which is available at [www.aott.org.tr](http://www.aott.org.tr)]

covered with serum-soaked gases and frozen at  $-20^{\circ}\text{C}$  until the day of the study. In order to assess preoperative data in the biomechanical study, the healthy left Achilles tendons of the subjects were also measured. All samples were measured after being frozen for 15 days. The samples were thawed in room temperature on the day of the study, the Achilles tendons were connected to the device from their origos and insertions, and the measures were obtained. In order to measure the axial (longitudinal) resistance of samples, a tensile test using Multitest 5-i mechanical tester (Mecmesin, West Sussex, United Kingdom) was conducted (Figure 4a). To connect the samples to the tester, a gripper jaw with 2 mm for the lower jaw and 1.5 mm for the upper jaw, which was specifically designed and produced in the Machining and Machine Tools Laboratory by Yıldız Technical University Mechanical Engineering Department, was used. The edges of the parts enabling a shape-link in the gripper jaw were planned by radius, so as not to create a cutting effect (Figure 4b). For each group, 6 samples were tested. The tests were performed at 10 mm/min pulling speed. The loading values were measured at 0.1% sensitivity by the load cell of the device and were transferred to computer software (Emperor™, Mecmesin, West Sussex, United Kingdom), and force values were obtained in newtons. The tests were completed when it was observed that the force fell and the sample broke. The highest force value among the obtained data was determined to be the maximum strength value  $F_{\max}$ . The cross-sectional area of the tendons subjected to the tensile test was 1 of the critical factors affecting pulling strength. As the cross-sectional area increased, the greater the load the tendon could endure. Considering this situation, pulling

durability of the tendons and the percentage ductility value until pulling durability were examined.

According to the average value and standard deviation obtained in the pilot study conducted previously, the sample volume of the groups was found to be  $n=10$  with 80% power and a 5% of margin of error. The standard effect size for biomechanical measure (2.23,  $n=6$ ) was calculated as the standard effect size for histopathologic evaluation (3.16,  $n=4$ ). Statistical analyses in this study were conducted with Number Cruncher Statistical System (NCSS) 2007 package program (NCSS, Kaysville, Utah, USA). In addition to descriptive statistical methods (mean, standard deviation, median, interquartile range), Mann-Whitney U test was used to compare binary groups, and Wilcoxon signed-rank test was used to compare repeated measurements when examining the data. A value of  $p<0.05$  was considered significant.



**Fig. 5.** Comparison graphic of score scale scores. [Color figure can be viewed in the online issue, which is available at [www.aott.org.tr](http://www.aott.org.tr)]

**Table 1.** Comparison of Bonar scale scores between groups statistically.

Histopathology	Control group		PRP group		p
	Mean±SD	Median (IQR)	Mean±SD	Median (IQR)	
15th day	10±0.82	10 (9.25–10.75)	6.25±0.96	6.5 (5.25–7)	0.019
30th day	6.25±0.96	6.5 (5.25–7)	3.25±0.5	3 (3–3.75)	0.017
p		0.059		0.066	

## Results

The histopathology Movin scale values of the PRP group on the 15<sup>th</sup> day post-treatment were found to be significantly lower than those of the control group ( $p=0.019$ ). The Movin scale values of the PRP group on the 30<sup>th</sup> day post-treatment were found to be significantly lower than those of the control group ( $p=0.017$ ). There were no differences in Movin scale values between the 15<sup>th</sup> and 30<sup>th</sup> day post-treatment in the control group ( $p=0.066$ ). There were no differences in Movin scale values between the 15<sup>th</sup> and 30<sup>th</sup> day post-treatment in the PRP group ( $p=0.066$ ) (Figure 5).

The histopathology Bonar scale values of the PRP group on the 15<sup>th</sup> day post-treatment were found to be significantly lower than those of the control group ( $p=0.019$ ). The Bonar scale values on the 30<sup>th</sup> day post-treatment were found to be significantly lower than those of the control group ( $p=0.017$ ). There were no differences in Bonar scale values between the 15<sup>th</sup> and 30<sup>th</sup> day post-treatment in the control group ( $p=0.059$ ). There was no significant change in Bonar scale values between the 15<sup>th</sup> and 30<sup>th</sup> day post-treatment in the PRP group ( $p=0.066$ ) (Table 1).

No difference was observed between  $F_{max}$  values between the 15<sup>th</sup> day and 30<sup>th</sup> day post-treatment of either the control or PRP groups ( $p=0.109$ ;  $p=0.749$ ).  $F_{max}$  values on the 15<sup>th</sup> day post-treatment of the control group were found to be significantly lower than those

of the 30<sup>th</sup> day post-treatment ( $p=0.028$ ). There was no difference between  $F_{max}$  values between the 15<sup>th</sup> and 30<sup>th</sup> day post-treatment in the PRP group ( $p=0.463$ ).  $F_{max}$  healthy side values on the 15<sup>th</sup> day post-treatment of the control group were found to be significantly higher than the surgically repaired side values on the 15<sup>th</sup> day post-treatment ( $p=0.004$ ). No difference was observed between  $F_{max}$  values of either healthy side or repaired side of the PRP group on the 15<sup>th</sup> day post-treatment ( $p=0.109$ ). No difference was observed between  $F_{max}$  values of either healthy side or repaired side of the control group on the 30<sup>th</sup> day post-treatment ( $p=0.998$ ). No difference was observed between  $F_{max}$  values of either healthy side or repaired side of the PRP group on the 30<sup>th</sup> day post-treatment ( $p=0.522$ ) (Table 2).

Tendon section, tensile force, tensile strength, and average elongation percent until tensile strength values are presented in Table 3. Following 15 days of treatment, the results show that strength values of healthy tendons for the control group could not be achieved. At the end of the same period, PRP repair group values became higher than those of the control group. Following 30 days of treatment, it was observed that the control group's tendons showed close values to healthy tendons; the PRP repair group tendons showed similar values to the control group at this time. When the tendons of the rats treated in the control group regained durability after treatment, no significant decrease in their stretching

**Table 2.** Comparison of  $F_{max}$  values between groups according to days.

BM ( $F_{max}$ )	Control group		PRP group		p
	Mean±SD	Median (IQR)	Mean±SD	Median (IQR)	
15th day	19.69±5.5	21.43 (13.31–24)	29.43±8.9	34.31 (18.07–35.83)	0.109
30th day	37.52±3.11	36.86 (35.12–40.64)	35.04±8.81	38.28 (24.37–42.48)	0.749
p		<b>0.028</b>		0.463	
15th day healthy	40.35±5.8	42.94 (34.19–44.75)	50.03±3.12	50.86 (46.79–52.84)	<b>0.006</b>
30th day healthy	40.31±8.17	36.04 (34.31–50.67)	52.15±24.66	46.27 (28.41–81.58)	0.749
p		0.917		0.917	
15th day patient/healthy		<b>0.004</b>		0.109	
30th day patient/healthy		0.998		0.522	

**Table 3.** Pulling force of Achilles tendons subjected to tensile test, tendon section, tensile force, tensile strength, average elongation percent till tensile strength values, and standard deviation values.

	Control healthy		Control repair		PRP healthy		TZP repair	
	15th day	30th day	15th day	30th day	15th day	30th day	15th day	30th day
Tensile force (n)	40.35±5.80	40.31±8.17	19.69±5.50	37.52±3.11	50.03±3.12	52.15±24.66	29.43±8.90	35.04±8.81
Cross-sectional area (mm <sup>2</sup> )	10.17±0.76	10.17±2.02	8.00±2.65	9.83±1.26	11.00±0.50	10.50±2.78	8.50±3.04	9.17±2.84
Tensile strength (Mpa)	3.89±0.54	3.91±0.16	2.61±0.10	3.87±0.29	4.57±0.06	4.69±1.30	3.48±0.13	3.81±0.13
Average elongation (%)	5.44±0.68	5.39±0.74	5.32±2.60	5.39±0.85	7.08±0.57	6.17±1.74	5.39±1.58	5.31±0.89

was observed. Although the standard deviation of percentage ductility values obtained as a result of 15 days of treatment was high, these values returned to normal after 30 days of treatment.

## Discussion

In soft tissue injury, PRP has recently been discovered, and studies in the literature report different results.<sup>[15–20]</sup> Although there is not sufficient clinical evidence, PRP is used to accelerate recovery, especially of the tendons and ligaments of athletes.<sup>[21]</sup> It is easy to implement and is not very expensive.<sup>[20]</sup>

Upon examination of our findings, we observed that PRP was histopathologically influential during the early phases of tendon recovery, and even though it was not statistically significant in terms of biometrics, we found that it was still influential on tendon recovery in the early phases and increased tendon strength. Repaired tendons in PRP group assimilated to the ductility value of the control group, and the results demonstrate that the treatment is beneficial.

Aspenberg et al. demonstrated that percutaneous PRP injection in rats with tendon injury led to a 30% increase in the stiffness and strength of the tendon callus within the first 3 weeks.<sup>[20]</sup> In the same study, it was reported that PRP showed its biomechanical effect on the 3<sup>rd</sup> and 5<sup>th</sup> days post-treatment. Spindler et al. showed that PRP accelerated tendon recovery process in animal models.<sup>[22]</sup>

Kaux et al. examined the Achilles tendons of PRP (2 hours postsurgery) applied and postsurgery immobilization unapplied rats biomechanically on the 5<sup>th</sup>, 15<sup>th</sup>, and 30<sup>th</sup> days post-treatment.<sup>[23]</sup> They found the values on the 15<sup>th</sup> and 30<sup>th</sup> days post-treatment to be higher and reported that the biomechanical effect of PRP was observed in the late period of recovery. We could not find significant differences in biomechanical measures between the 15<sup>th</sup> and 30<sup>th</sup> days post-treatment. In the same study, when histopathologic data was compared, the tendon callus amount on the 5<sup>th</sup> day post-treatment was found to be significantly higher. Accordingly, it was con-

cluded that PRP is effective in the early period of recovery, histopathologically. These results are similar to ours.

Murray et al.<sup>[24]</sup> and Majewski et al.<sup>[25]</sup> examined biomechanically the effect of PRP on tendon recovery and did not find significant differences. Nurden et al. reported that platelets have critical importance in tissue recovery, especially in the early period.<sup>[26]</sup> This finding explains the significantly lower histopathologic recovery scores we obtained in the early period.

Sanchez et al. reported good results regarding use of PRP after Achilles tendon surgery.<sup>[15]</sup> The retrospective nature and low number of subjects are weaknesses of the study.

Garder<sup>[27]</sup> and Alissa<sup>[28]</sup> demonstrated the analgesic effect of PRP in knee arthroplasty and periodontal surgery. This effect was explained by the presence of serotonin, dopamine, and catecholamines besides GFs in the PRP.<sup>[29]</sup> Amendola stated that the complication rate after Achilles tendon repair in active people was 15–20% and, parallel with that, the re-rupture rate increased.<sup>[30]</sup> We did not apply immobilization to any rat, nor did we find any re-rupture after the observation period; however, it is difficult to compare the results of these 2 studies, as human subjects were used in Amendola's study. In a study combining surgical and biological treatments by using autologous PRP caused by the problems in tendon recovery, Anitua et al. showed the positive effects of PRP on tendon recovery.<sup>[31]</sup> Sadoghi et al. reviewed the studies on platelet effect in Achilles tendon ruptures in animals and humans.<sup>[32]</sup> Powerful evidence that platelet use improves biomechanical, histological, and clinical results of the Achilles tendon has been obtained. Hapa et al. demonstrated in rats that in chronic focal chondral defects, applying PRP together with microfracture can make cartilage recovery more effective.<sup>[33]</sup>

In their study on Achilles tendon ruptures in rats, Virchenko and Aspenberg<sup>[34]</sup> implemented botox injections in order to unburden the repaired tendon and then observed the rats in 2 different kinds of cages, standard and activity cages. They showed that PRP had an effect on the early regeneration phase of tendon recovery and

that physical activity was absolutely necessary for the platelets, which have a short lifespan, to have a long-term effect. Moreover, they concluded that the use of PRP in the human Achilles tendon without early physical therapy could be ineffective. Since we did not apply immobilization to any rat and observed all of them in standard cages, we could not find any evidence regarding the interaction between mechanical stimulation and early regeneration. However, we can explain the positive results of PRP in later periods with the use of immobilization and allowing early movement.

In their study on the flexor tendons of dogs, Morizaki et al.<sup>[35]</sup> emphasized the effect of stitching material in the tendon repair area. They also emphasized the importance of tendon strength in terms of the time that the strength of stitching material disappears, gives a movement and burden for tendons. We could not investigate the effect of stitching material.

Our study has some limitations. The low number of subjects and the experimental nature of the study are weaknesses, which do not demonstrate clinical and functional results. Since we experimented with live animals, we worked with a subject number sufficient for statistical validity. As it is favorable to use 3 consistent results for European norms, which are applied in mechanical studies on tensile testing, the results obtained are sufficient. That we did not examine the biomechanical effect of stitching material and technique is 1 of the weaknesses of our study. However, as the same stitching material and technique were used in both of the surgically repaired groups, the possibility of comparing both groups in this respect is not limited. The only limitation is on the comparison and interpretation of measures of the subjects with surgical repair and the healthy tendons. Further fundamental and clinical studies are needed before use of PRP as a principle can be recommended. Firstly, a standard methodology regarding PRP preparation methods, as well as application amounts and methods, should be developed, as the current multiplicity of methods can create confusion,<sup>[36]</sup> which negatively affects standardization. Further research needs to investigate the applicability and effect of PRP for various causes (acute, chronic, degenerative, and traumatic) and kinds (soft tissue, bone, or both) of injury in more detail. In this study, we created an acute and iatrogenic Achilles tendon rupture and then repaired it. However, in humans, most Achilles tendon ruptures occur on a degenerative ground.

In this study, we have shown that, with the use of PRP in Achilles tendon repairs of rats, significant structural histopathologic effects emerged on the 15<sup>th</sup> and

30<sup>th</sup> days post-treatment but that their biomechanical effects were not significant. Since the sample sizes in the comparison groups were low, we suggest that these results should be interpreted with caution and that future studies with larger sample sizes will enlarge the understanding of this issue.

**Acknowledgements:** For their contributions and support, we would like to thank the Bağcılar Training and Research Hospital Management and the Bağcılar Training and Research Hospital Experimental Research and Skill Development Center (BADABEM). For their help during the biomechanical laboratory studies, we would like to thank Yıldız Technical University Mechanical Engineering Department member Prof. Dr. Ayşegül Akdoğan Eker and Research Asst. Ali Avcı.

**Conflicts of Interest:** No conflicts declared.

## References

1. Karahan M, Erol B. Aşil tendon yırtıklarına yaklaşım. TOTBİD (Türk Ortopedi ve Travmatoloji Birliği Dergisi) 2004;1-2.
2. Suchak AA, Bostick G, Reid D, Blitz S, Jomha N. The incidence of Achilles tendon ruptures in Edmonton, Canada. *Foot Ankle Int* 2005;26:932-6.
3. Kashiwagi K, Mochizuki Y, Yasunaga Y, Ishida O, Deie M, Ochi M. Effects of transforming growth factor-beta 1 on the early stages of healing of the Achilles tendon in a rat model. *Scand J Plast Reconstr Surg Hand Surg* 2004;38:193-7.
4. Wang XT, Liu PY, Tang JB. Tendon healing in vitro: genetic modification of tenocytes with exogenous PDGF gene and promotion of collagen gene expression. *J Hand Surg Am* 2004;29:884-90.
5. Zhang F, Liu H, Stile F, Lei MP, Pang Y, Oswald TM, et al. Effect of vascular endothelial growth factor on rat Achilles tendon healing. *Plast Reconstr Surg* 2003;112:1613-9.
6. Rickert M, Jung M, Adiyaman M, Richter W, Simank HG. A growth and differentiation factor-5 (GDF-5)-coated suture stimulates tendon healing in an Achilles tendon model in rats. *Growth Factors* 2001;19:115-26.
7. Freymiller EG. Platelet-rich plasma: evidence to support its use. *J Oral Maxillofac Surg* 2004;62:1046-8.
8. Rozman P, Bolta Z. Use of platelet growth factors in treating wounds and soft-tissue injuries. *Acta Dermatovenerol Alp Pannonica Adriat* 2007;16:156-65.
9. Roberts AB, Sporn MB. Physiological actions and clinical applications of transforming growth factor-beta (TGF-beta). *Growth Factors* 1993;8:1-9.
10. Marx RE. Platelet-rich plasma (PRP): what is PRP and what is not PRP? *Implant Dent* 2001;10:225-8.
11. Marx RE, Carlson ER, Eichstaedt RM, Schimmele SR,

- Strauss JE, Georgeff KR. Platelet-rich plasma: Growth factor enhancement for bone grafts. *Oral Surg Oral Med Oral Pathol Oral Radiol Endod* 1998;85:638–46.
12. Babbush CA, Kevy SV, Jacobson MS. An in vitro and in vivo evaluation of autologous platelet concentrate in oral reconstruction. *Implant Dent* 2003;12:24–34.
  13. de Vos RJ, Weir A, van Schie HT, Bierma-Zeinstra SM, Verhaar JA, Weinans H, et al. Platelet-rich plasma injection for chronic Achilles tendinopathy: a randomized controlled trial. *JAMA* 2010;303:144–9.
  14. Krackow KA, Thomas SC, Jones LC. A new stitch for ligament-tendon fixation. Brief note. *J Bone Joint Surg Am* 1986;68:764–6.
  15. Sánchez M, Anitua E, Azofra J, Andía I, Padilla S, Mujika I. Comparison of surgically repaired Achilles tendon tears using platelet-rich fibrin matrices. *Am J Sports Med* 2007;35:245–51.
  16. Orrego M, Larrain C, Rosales J, Valenzuela L, Matas J, Durruty J, et al. Effects of platelet concentrate and a bone plug on the healing of hamstring tendons in a bone tunnel. *Arthroscopy* 2008;24:1373–80.
  17. Peerbooms JC, Sluimer J, Bruijn DJ, Gosens T. Positive effect of an autologous platelet concentrate in lateral epicondylitis in a double-blind randomized controlled trial: platelet-rich plasma versus corticosteroid injection with a 1-year follow-up. *Am J Sports Med* 2010;38:255–62.
  18. Cetti R, Christensen SE, Ejsted R, Jensen NM, Jorgensen U. Operative versus nonoperative treatment of Achilles tendon rupture. A prospective randomized study and review of the literature. *Am J Sports Med* 1993;21:791–9.
  19. Puddu G, Ippolito E, Postacchini F. A classification of Achilles tendon disease. *Am J Sports Med* 1976;4:145–50.
  20. Aspenberg P, Virchenko O. Platelet concentrate injection improves Achilles tendon repair in rats. *Acta Orthop Scand* 2004;75:93–9.
  21. Creaney L, Hamilton B. Growth factor delivery methods in the management of sports injuries: the state of play. *Br J Sports Med* 2008;42:314,20.
  22. Spindler KP, Murray MM, Carey JL, Zurakowski D, Fleming BC. The use of platelets to affect functional healing of an anterior cruciate ligament (ACL) autograft in a caprine ACL reconstruction model. *J Orthop Res* 2009;27:631–8.
  23. Kaux JF, Drion PV, Colige A, Pascon F, Libertiaux V, Hoffmann A, et al. Effects of platelet-rich plasma (PRP) on the healing of Achilles tendons of rats. *Wound Repair Regen* 2012;20:748–56.
  24. Murray MM, Palmer M, Abreu E, Spindler KP, Zurakowski D, Fleming BC. Platelet-rich plasma alone is not sufficient to enhance suture repair of the ACL in skeletally immature animals: an in vivo study. *J Orthop Res* 2009;27:639–45.
  25. Majewski M, Ochsner PE, Liu F, Flückiger R, Evans CH. Accelerated healing of the rat Achilles tendon in response to autologous conditioned serum. *Am J Sports Med* 2009;37:2117–25.
  26. Nurden AT, Nurden P, Sanchez M, Andia I, Anitua E. Platelets and wound healing. *Front Biosci* 2008;13:3532–48.
  27. Gardner MJ, Demetrakopoulos D, Klepchick PR, Moor PA. The efficacy of autologous platelet gel in pain control and blood loss in total knee arthroplasty. An analysis of the haemoglobin, narcotic requirement and range of motion. *Int Orthop* 2007;31:309–13.
  28. Alissa R, Esposito M, Horner K, Oliver R. The influence of platelet-rich plasma on the healing of extraction sockets: an explorative randomised clinical trial. *Eur J Oral Implantol* 2010;3:121–34.
  29. Creaney L, Hamilton B. Growth factor delivery methods in the management of sports injuries: the state of play. *Br J Sports Med* 2008;42:314–20.
  30. Amendola N. Surgical treatment of acute rupture of the tendo Achillis led to fewer reruptures and better patient-generated ratings than did nonsurgical treatment. *J Bone Joint Surg Am* 2002;84–A:324.
  31. Anitua E, Sánchez M, Nurden AT, Nurden P, Orive G, Andía I. New insights into and novel applications for platelet-rich fibrin therapies. *Trends Biotechnol* 2006;24:227,34.
  32. Sadoghi P, Rosso C, Valderrabano V, Leithner A, Vavken P. The role of platelets in the treatment of Achilles tendon injuries. *J Orthop Res* 2013;31:111–8.
  33. Hapa O, Çakici H, Yüksel HY, Fırat T, Kükner A, Aygün H. Does platelet-rich plasma enhance microfracture treatment for chronic focal chondral defects? An in-vivo study performed in a rat model. *Acta Orthop Traumatol Turc* 2013;47:201–7.
  34. Virchenko O, Aspenberg P. How can one platelet injection after tendon injury lead to a stronger tendon after 4 weeks? Interplay between early regeneration and mechanical stimulation. *Acta Orthop*. 2006;77:806–12.
  35. Morizaki Y, Zhao C, An KN, Amadio PC. The effects of platelet-rich plasma on bone marrow stromal cell transplants for tendon healing in vitro. *J Hand Surg Am* 2010;35:1833–41.
  36. Taylor DW, Petrera M, Hendry M, Theodoropoulos JS. A systematic review of the use of platelet-rich plasma in sports medicine as a new treatment for tendon and ligament injuries. *Clin J Sport Med* 2011;21:344–52.