



Omentum and reverse turnover latissimus dorsi musculocutaneous flap for the treatment of cerebrospinal fluid fistula

Yetkin SÖYÜNCÜ¹, Zekiye BİGAT², İlkyay SÖYÜNCÜ³, Ömer ÖZKAN⁴

¹Akdeniz University Faculty of Medicine, Department of Orthopedics and Traumatology, Antalya, Turkey

²Akdeniz University Faculty of Medicine, Department of Anesthesiology and Reanimation, Antalya, Turkey

³Antalya Training and Research Hospital, Department of Plastic Surgery, Antalya, Turkey

⁴Akdeniz University Faculty of Medicine, Department of Plastic Surgery, Antalya, Turkey

Conventional procedures can usually prevent cerebrospinal fluid (CSF) leakages, but they may not work for complicated cases. In this case presentation, we demonstrated the effectiveness of combined omental and latissimus dorsi musculocutaneous flaps for management of difficult CSF fistula. A reverse turnover latissimus dorsi musculocutaneous flap and omental flap were transferred for reconstruction of the posterior wound and CSF leakage. The omental flap component was used for CSF absorption, and the latissimus dorsi muscle component was used for obliteration of the dead space, covering of the exposed bone, and tension-free closure of the wound. The wound healed dramatically, with no observed severe donor site morbidity. The patient has been followed for 30 months with no evidence of CSF leakage and no pseudomeningocele formation, which was confirmed by magnetic resonance imaging (MRI). Although this is a case presentation, we can say that the combination of the omental and musculocutaneous flaps allow effective treatment and prevention of CSF fistulas in selected high-risk patients and provide durable coverage of complex spinal wounds.

Keywords: Cerebrospinal fluid fistula; flap; omental transposition; reverse latissimus musculocutaneous flap; spine.

Postoperative cerebrospinal fluid (CSF) leakage is a common complication in the practice of spinal surgery. Most injuries heal uneventfully if the dura mater is repaired. If dural closure is not possible, CSF may leak through the surgical tract to form a cutaneous CSF fistula. Immediate measures must be taken to stop the leakage, as the fistula tract is a conduit for infection.^[1] Various treatment modalities such as primary repair, closed subarachnoid drainage, grafts consisting of muscle, fat or fascia, blood

patches, fibrin-adhesive or cyanoacrylate polymer sealant, and the application of Gelfoam® (Pfizer, New York, NY, USA) have been described to manage this problem.^[2,3] In cases of large spinal wounds secondary to cerebrospinal fistula or exposed hardware, muscle coverage may become the only tool for providing effective well-vascularized dural coverage. Depending on the location of the wound, a number of techniques have been documented in the repair of such defects, such as the superior

Correspondence: Yetkin Söyüncü, MD. Akdeniz Üniversitesi Tıp Fakültesi, Ortopedi ve Travmatoloji Anabilim Dalı, Antalya, Turkey.

Tel: +90 242 – 249 61 51 e-mail: ysoyuncu@hotmail.com

Submitted: December 10, 2013 **Accepted:** May 28, 2014

©2015 Turkish Association of Orthopaedics and Traumatology

Available online at
www.aottt.org.tr
doi: 10.3944/AOTT.2015.13.0157
QR (Quick Response) Code



gluteal artery flap, trapezius flap, latissimus muscle flap, a variety of free flaps, and the paraspinous muscle flap.^[4-10]

We presented a case illustrating the use of combined pedicled omental flap and latissimus dorsi musculocutaneous flap to repair a persistent CSF leakage and to maintain healthy skin coverage on the lumbar area. We did not focus on the surgical indication and treatment procedure concerning degenerative disc disease in this case.

Case report

A 72-year-old man presented to our clinic with complaints of lower back and left leg pain, as well as bilateral lower extremity numbness. He stated that the symptoms had started 3 years ago and had been progressively worsening for the previous 6 months.

On clinical examination, the quadriceps muscle was weak, and lower deep tendon reflexes were hypoactive on the left side. No sensory deficits were evident. In his past medical history, he had taken chemotherapy and radiation therapy to the lumbar area for plasmacytoma 10 years ago, but currently he was asymptomatic.

Preoperative imaging work-up included plain X-ray including dynamic graphics, as well as a lumbar spine magnetic resonance imaging (MRI) study and computed tomography (CT). An L2–L3 and L3–L4 central and lateral stenosis with L3–L4 and L4–L5 instability were shown. The patient underwent L2–L4 posterior decompression and T10–L5 posterior transpedicular fixation and posterolateral fusion with an autologous bone graft.

The patient was discharged on the 5th postopera-

tive day. Eleven days later, he sought treatment for CSF leakage at the lower end of the wound. The patient was neurologically intact, afebrile, and presented with no nuchal rigidity.

At this point, due to the wound quality, we decided to proceed with a revision of the surgical wound. Intraoperatively, a small dural tear was seen at the L3–L4 level. The dura was repaired with 5-0 silk and then covered with muscle patch and fibrin glue. An L1–L2 intrathecal lumbar drain was also placed. The patient was kept supine in bed rest during a 2-week follow-up period, during which CSF leakage continued. The intrathecal lumbar drain was replaced with a lumboperitoneal shunt; however, CSF leakage did not resolve at follow-up (Fig 1).

Due to the failure of standard surgical intervention, we decided to close the wound with a pedicled omental flap and reverse latissimus flap (Fig 2).

A midline laparotomy incision was made. The greater curvature of the stomach and the right and left gastroepiploic vessels were dissected. The omentum was flipped superiorly. The posterior attachments to the large colon were exposed and dissected. Small perforating branches were ligated and divided. The omentum was then isolated from stomach ligating gastric vessels. The left gastroepiploic artery was ligated and divided. The right gastroepiploic artery was ligated between the right and middle omental vessels. The distal middle omental arcade was ligated. The entire flap was isolated on the right omental artery pedicle. The flap was then passed through a tunnel created lateral to the external oblique muscle to the lumbar area and then rotated into the wound. The patient

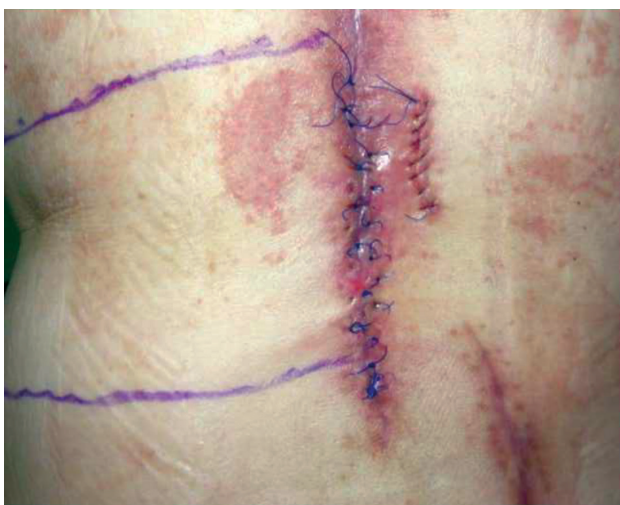

Fig. 1. Intrathecal lumbar drain was replaced with lumboperitoneal shunt, but CSF leakage from wound did not resolve. [Color figure can be viewed in the online issue, which is available at www.aott.org.tr]

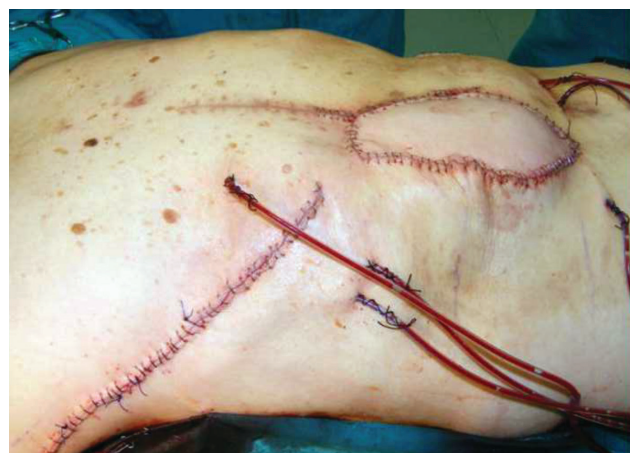

Fig. 2. A pedicular flap of the greater omentum was transported through the posterior abdominal wall to the lumbar epidural space, and reverse pedicled latissimus dorsi musculocutaneous flap was rotated to maintain healthy skin coverage on the lumbar area. [Color figure can be viewed in the online issue, which is available at www.aott.org.tr]

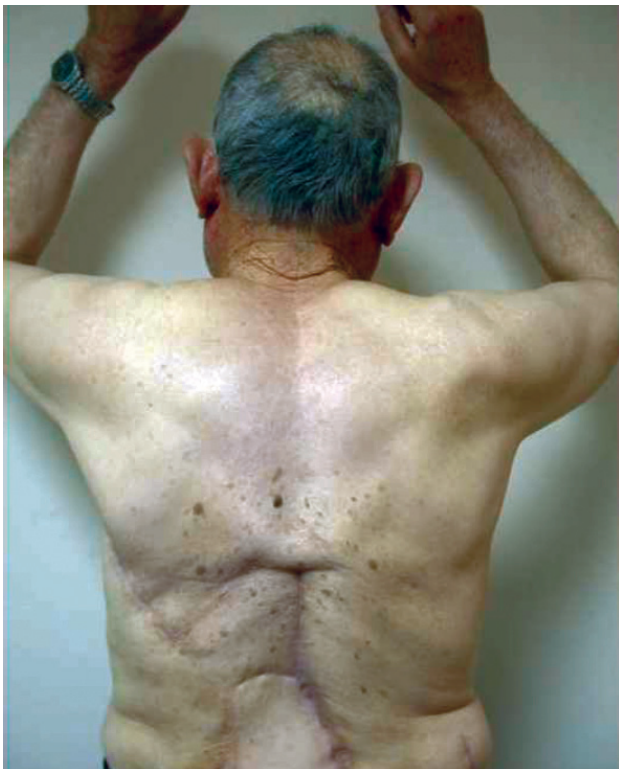

Fig. 3. 30-month follow-up. The wound healed dramatically. No donor site morbidity was observed. The patient's functional result was good. [Color figure can be viewed in the online issue, which is available at www.aott.org.tr]

was then positioned prone for the final graft placement. After opening the back in standard fashion, the tunneled omental flap was accessed.

At the second stage, a reverse latissimus flap (skin pedicle: 8x18 cm) based on the secondary segmental vessels was harvested and rotated to cover the omental surface, creating a multilayer closure of the wound. Suction drains were inserted in both surgical and flap donor sites to avoid seroma formation as well as to facilitate graft integration. The donor area of the latissimus dorsi flap was primarily closed.

Drains were discontinued when the drain output was 30 mL/day. A pressure relief bed was used in the immediate postoperative period to limit local tissue edema and prevent pressure necrosis of the wound. The patient was not allowed to assume the supine position for 1 week. At 1 week postoperatively, he was allowed to lie on the flap and started ambulation.

The patient was discharged on the 16th postoperative day with a healed wound. A review at 30 months revealed no wound problems, abdominal complications, or pseudomeningocele formation, which was confirmed by MRI (Figure 3, 4a, b).

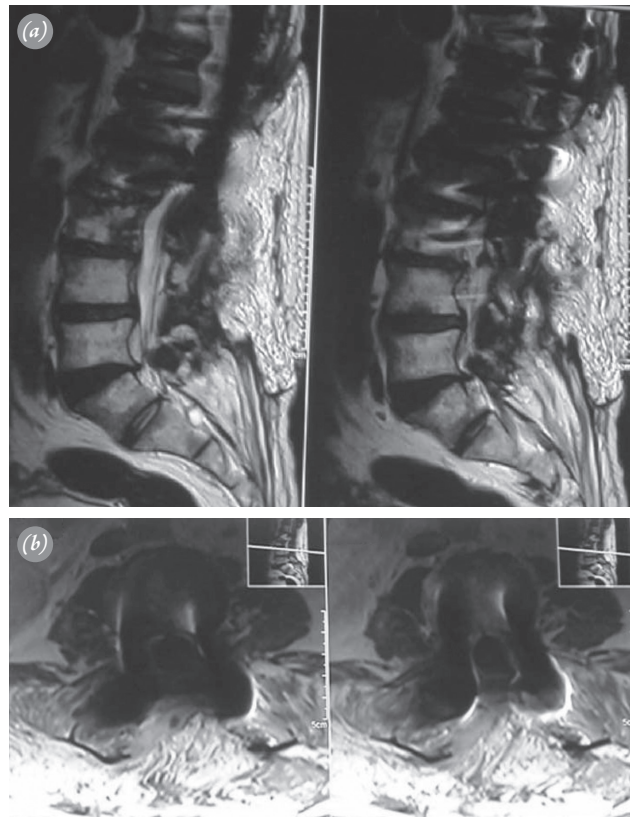


Fig. 4. (a, b) There is no pseudomeningocele formation, which was confirmed by MRI at last follow-up.

Discussion

The treatment of postsurgical lumbosacral wound dehiscence can be challenging, particularly when complicated by CSF leak. Surgical flaps are needed to deliver a fresh blood supply, fill dead space, and provide soft tissue coverage. Previous studies have described paraspinous muscle flaps, extended latissimus dorsi flaps with vein grafts, free tissue transfer, greater omentum flaps, and gluteus maximus muscle flaps for the closure of complex spinal wounds, but few have addressed their use for the prevention and treatment of CSF fistulas.^[9,11-13] Saint-Cyr et al. evaluated the efficacy of paraspinous muscle flap coverage using a “vest-over-pants” closure in the prevention and treatment of CSF fistulas. There was no evidence of a CSF fistula after an average follow-up of 176.7 days. No wound infections occurred. The only complications were a superficial hematoma and a seroma.^[9] However, in more severe cases with exposed hardware, the extensive skin and muscle reactive fibrosis adjacent to the wound makes the paraspinous muscle flaps difficult to move. Moreover, even if they could be dissected, they would not have sufficient volume to fill these wide and deep wounds. In this situation, the pedicled latissimus dorsi and trapezius muscle flaps have proven to be the

most reliable methods of treatment.

Fasciocutaneous flaps also have been used but are unable to provide the optimal well-vascularized tissue needed in cases of exposed spinal bone, exposed hardware, infected wounds, and cerebrospinal fistulas.^[14] The surface area, pedicle length, plasticity, angiogenic, and immunogenic qualities of the greater omentum make it particularly useful for the reconstruction of irradiated and ischemic wounds. In addition to these properties, the dense lymphatic network provides tremendous absorptive potential.^[15,16] No significant increase in operative time occurs, as a microvascular anastomosis is not required. The only potential morbidity is due to risks associated with laparotomy, such as hernia formation, bowel injury, ileus, bowel obstruction, and intestinal volvulus. Despite numerous advantages for the management of spinal wounds, the use of omental flaps in spinal surgery has been minimal, consisting largely of anecdotal reports with limited follow-up.^[7,17–23] The greater omentum flap has been used for back defects when the erector spinae has been previously used or been subjected to irradiation.^[20] O'Shaughnessy et al. evaluated the safety and efficacy of using an omental flap in complex spine reconstruction in patients at high-risk for wound dehiscence. At the time of follow-up, all patients had well-healed surgical wounds with an acceptable structural and aesthetic result. In terms of spinal outcome, all patients achieved successful bony arthrodesis.^[23] In our case, the primary criteria for using a pedicled omental flap was scarred, irradiated, divided, and unusable back musculature suitable for paraspinous muscle flap transfer in the patient. It has great absorptive potential, which we believe has helped lessen the CSF leak of the wound of our patient. The patient had a well-healed wound at the time of follow-up, and no complications related to the procedure were seen.

Another local flap option, the reverse latissimus flap, is based on the paraspinous perforating vessels and provides enough muscle to fill the defects. While some may argue that the latissimus could have been used to treat our patient's wound, we selected an alternative flap to salvage this difficult lower back wound. In the lumbar region, enough muscle bulk can be coopted to permit a double layer, and in our case, the reconstruction was bolstered by a second muscle layer of latissimus closed in the midline over the omental flap. Our hypothesis put forth that wide drainage in both deep and superficial planes by flaps would decrease the incidence of seroma and could help control a CSF fistula. Another reason for the preference of the latissimus dorsi flap was our previous experience with this flap in microsurgical cases.

While we were concerned about the latissimus dorsi muscle flap, the patient did not complain of any loss of strength or changed function. Manual muscle testing of the donor site showed minor shoulder adduction, internal rotation and extension weakness when compared with the other side.

Although this is a case presentation, a favorable outcome could be achieved in the patient with problematic CSF leakage and spinal wound problems. The omental flaps can be used as primary deep flaps in combination with superficial secondary flaps such as the latissimus dorsi muscle in selected cases, depending on the location of the defect. Although we do not recommend this procedure in primary durotomy repair, it may be useful to augment repair in cases of persistent CSF leak refractory to conventional management.

Conflicts of Interest: No conflicts declared.

References

1. Riew KD, Khanna N. Treatment of cerebrospinal fluid leaks. In: Vaccaro AR, Betz RR, Zeidman SM, editors. Principles and practice of spine surgery. Philadelphia, USA: Mosby; 2003. p. 735–43.
2. Pomeranz S, Constantini S, Umansky F. The use of fibrin sealant in cerebrospinal fluid leakage. *Neurochirurgia (Stuttgart)* 1991;34:166–9.
3. Jankowitz BT, Atteberry DS, Gerszten PC, Karausky P, Cheng BC, Faught R, et al. Effect of fibrin glue on the prevention of persistent cerebral spinal fluid leakage after incidental durotomy during lumbar spinal surgery. *Eur Spine J* 2009;18:1169–74.
4. Hochberg J, Ardenghy M, Yuen J, Gonzalez-Cruz R, Mura Y, Conrado RM, et al. Muscle and musculocutaneous flap coverage of exposed spinal fusion devices. *Plast Reconstr Surg* 1998;102:385–92.
5. de Fontaine S, Gaede F, Berthe JV. The reverse turnover latissimus dorsi flap for closure of midline lumbar defects. *J Plast Reconstr Aesthet Surg* 2008;61:917–24.
6. Meiners T, Flieger R, Jungclaus M. Use of the reverse latissimus muscle flap for closure of complex back wounds in patients with spinal cord injury. *Spine (Phila Pa 1976)* 2003;28:1893–8.
7. Dumanian GA, Ondra SL, Liu J, Schafer MF, Chao JD. Muscle flap salvage of spine wounds with soft tissue defects or infection. *Spine (Phila Pa 1976)* 2003;28:1203–11.
8. Abuzayed B, Kafadar AM, Oğuzoğlu SA, Canbaz B, Kaynar MY. Duraplasty using autologous fascia lata reinforced by on-site pedicled muscle flap: technical note. *J Craniofac Surg* 2009;20:435–8.
9. Saint-Cyr M, Nikolis A, Moumdjian R, Frenette G, Ciaburro H, Harris PG, et al. Paraspinous muscle flaps for the

- treatment and prevention of cerebrospinal fluid fistulas in neurosurgery. *Spine (Phila Pa 1976)* 2003;28:86–92.
10. Chun JK, Lynch MJ, Poultsides GA. Distal trapezius musculocutaneous flap for upper thoracic back wounds associated with spinal instrumentation and radiation. *Ann Plast Surg* 2003;51:17–22.
 11. Vitaz TW, Oishi M, Welch WC, Gerszten PC, Disa JJ, Bilsky MH. Rotational and transpositional flaps for the treatment of spinal wound dehiscence and infections in patient populations with degenerative and oncological disease. *J Neurosurg* 2004;100(1 Suppl Spine):46–51.
 12. Azizkhan RG, Roberson JB Jr, Powers SK. Successful use of a vascularized intercostal muscle flap to seal a persistent intrapleural cerebrospinal fluid leak in a child. *J Pediatr Surg* 1991;26:744–6.
 13. Weber SM, Kim J, Delashaw JB, Wax MK. Radial forearm free tissue transfer in the management of persistent cerebrospinal fluid leaks. *Laryngoscope* 2005;115:968–72.
 14. Chang N, Mathes SJ. Comparison of the effect of bacterial inoculation in musculocutaneous and random-pattern flaps. *Plast Reconstr Surg* 1982;70:1–10.
 15. Levander B, Zwetnow NN. Bulk flow of cerebrospinal fluid through a lumbo-omental pedicle graft in the dog. *Acta Neurochir (Wien)* 1978;41:147–55.
 16. Levander B, Zwetnow NN. Bulk flow of cerebrospinal fluid through a lumbo-omental pedicle graft in the dog. *Acta Neurochir (Wien)* 1978;41:147–55.
 17. Giordano PA, Griffet J, Argenson C. Pedicled greater omentum transferred to the spine in a case of postoperative infection. *Plast Reconstr Surg* 1994;93:1508–11.
 18. Barrow DL, Nahai F, Tindall GT. The use of greater omentum vascularized free flaps for neurosurgical disorders requiring reconstruction. *J Neurosurg* 1984;60:305,11.
 19. Liebermann-Meffert D. The greater omentum. Anatomy, embryology, and surgical applications. *Surg Clin North Am* 2000;80:275–93.
 20. Lantieri LA, Tantaoui B, Rimareix FA, Raulo YF, Baruch JP. Lower back coverage with endoscopically harvested pedicled greater omental flap. *Plast Reconstr Surg* 1999;103:960–3.
 21. Hentschel SJ, Rhines LD, Wong FC, Gokaslan ZL, McCutcheon IE. Subarachnoid-pleural fistula after resection of thoracic tumors. *J Neurosurg* 2004;100(4 Suppl Spine):332–6.
 22. Heller JG, Kim HS, Carlson GW. Subarachnoid-pleural fistulae--management with a transdiaphragmatic pedicled greater omental flap: report of two cases. *Spine (Phila Pa 1976)* 2001;26:1809–13.
 23. O'Shaughnessy BA, Dumanian GA, Liu JC, Ganju A, Ondra SL. Pedicled omental flaps as an adjunct in the closure of complex spinal wounds. *Spine (Phila Pa 1976)* 2007;32:3074–80.