

# A case of giant lipoma of parietal peritoneum with literature review

Bharath B, G Sagar Reddy, John M Francis

PES Institute of Medical Sciences and Research,  
Kuppam, Chittoor District, Andhra Pradesh-  
517425, India

**ORCID ID of the author(s)**

BB: 0000-0001-7553-8380  
GSR: 0000-0002-4985-0108  
JMF: 0000-0002-6907-9402

## Abstract

Lipomas are the most typically diagnosed soft tissue tumors. A lipoma is composed of adipose tissue, may vary in size, and is usually seen in the subcutaneous region, most commonly over the extremities followed by trunk and neck. In this case report, a rare case of giant lipoma that was found in the preperitoneal space arising from the parietal peritoneum measuring 40 x 36 x 5 cm and weighing 3.7 kg is described. This lipoma was successfully excised without any immediate or late post-operative complications and no recurrence for 24 months post-operatively.

**Keywords:** Giant lipoma, Parietal peritoneum, Mass, Surgical excision

## Introduction

A lipoma is a common and asymptomatic soft tissue tumor which is a benign encapsulated fatty tumor, sometimes admixed with other elements (such as fibrous tissue, blood vessels, cartilage) universally can occur anywhere in the human body and does differ in size. The incidences of simple solitary and multiple lipomas are reported to be higher in males than females. Most lipomas are solitary, but multiple lipomas associated with several syndromes have been described. Small lipomas do not require intervention unless the patient requests it. Symptomatic large or deep lesions may be removed by excision. Recurrence rates after excision of a simple superficial lipoma are 1%–2%, whereas rates are significantly higher for other lipoma types [1]. A case of a giant lipoma arising from parietal peritoneum, which presented as an abdominal mass, is described.

### Corresponding Author

Bharath B

S171, Dwarakavasa Road 2<sup>nd</sup> stage, Bharathnagar,  
BEL Layout, Herohalli, Near Anupama Hospital,  
Bengaluru, Karnataka, India 560091  
E-mail: bharathbasavraj@gmail.com

### Informed Consent

The authors stated that the written consent was obtained from the patient presented with images in the study.

### Conflict of Interest

No conflict of interest was declared by the authors.

### Financial Disclosure

The authors declared that this study has received no financial support.

### Published

2022 April 22

Copyright © 2022 The Author(s)

Published by JOSAM

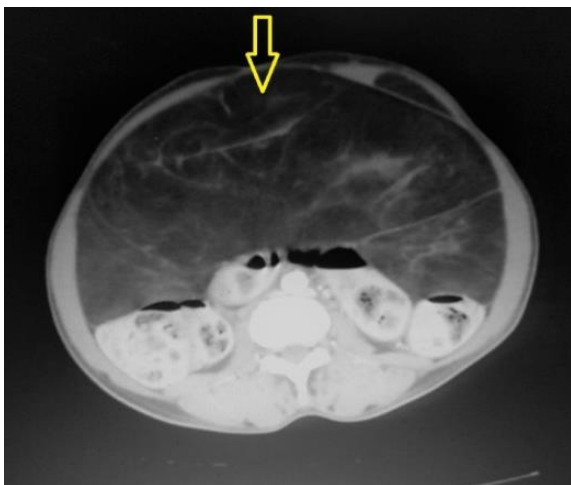This is an open access article distributed under the terms of the Creative Commons Attribution-Non Commercial-NoDerivatives License 4.0 (CC BY-NC-ND 4.0) where it is permissible to download, share, remix, transform, and build upon the work provided it is properly cited. The work cannot be used commercially without permission from the journal.



## Case presentation

A 50-year-old woman presented with complaints of a vague non-radiating lower abdominal pain, nausea, reduced appetite, and constipation. No significant bladder disturbances were present, and her vital signs and general physical examination were normal. On examination of the abdomen, lower abdominal distension and a soft, vague mass occupying umbilical, lumbar, iliac fossa, and hypogastric regions were detected. The swelling was intraabdominal with a dull note on percussion. Bowel sounds were present, and no hepatosplenomegaly was noted. No specific laboratory investigation abnormalities were present; abdominal ultrasonography (USG) revealed a sizeable intraperitoneal mass, probably a lipomatous neoplasm with anterior intramural fibroid. The patient had an abdominal computed tomography (CT) scan, which showed a large mass of fat echogenicity measuring approximately 25 x 22 cm within the peritoneal cavity extending from epigastrium to hypogastrum (Figure 1). The lesion created an indentation in the superior surface of the bladder and caused displacement of adjacent small and large bowel loops with anterior intramural uterine fibroid measuring approximately 2 cm.

Figure 1: Computed tomography (CT) scan shows a mass of fat echogenicity measuring approximately 25 x 22cm noted within the peritoneal cavity extending from epigastrium to hypogastrum; the lesion is noted to cause indentation of the superior bladder surface and cause displacement of adjacent small and large bowel loops.



The patient underwent laparotomy. Intra-operatively, a giant lipoma measuring 40 cm vertically and 36 cm horizontally arising from the parietal peritoneum in the preperitoneal space posterior to the anterior abdominal wall was noted. Excision of the tumor was done after ligating the feeding vessels (Figure 2). The parietal peritoneum was preserved since no infiltration to the surrounding structures had occurred. The specimen weighed 3.7 kg and was sent for histopathological analysis, which showed a well-encapsulated tumor with lobules of fat separated by fibrous septa with no obvious lipoblast, suggestive of a benign lipoma (Figure 3). The post-operative period was uneventful, and the patient was discharged on the 8th post-operative day. She remained asymptomatic for 24 months post-operatively.

Figure 2: Intra-operative images of the parietal peritoneal lipoma

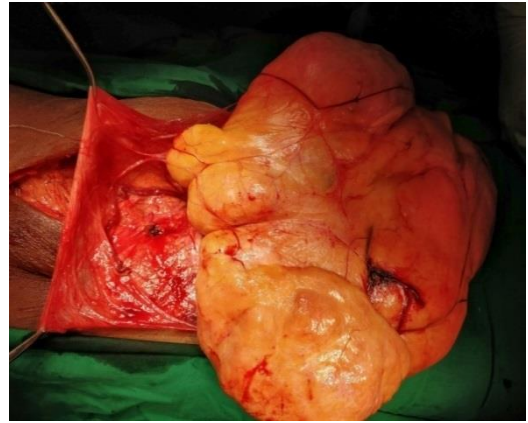
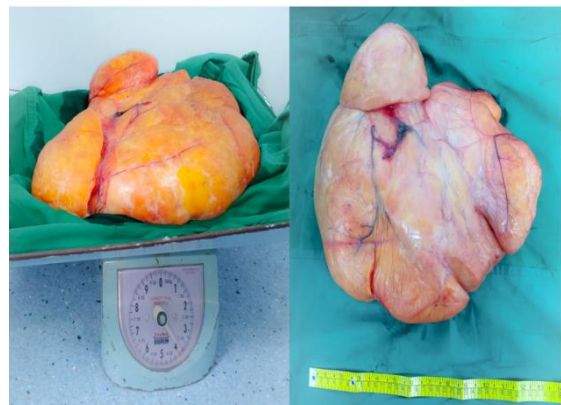

Figure 3: Resected specimen of parietal peritoneal lipoma showing the weight and measurements



## Discussion

Lipomas in the abdominal cavity can present themselves in the mesentery, omentum, and retroperitoneum, but a lipoma of the parietal peritoneum is extremely rare. A deep lipoma usually presents itself when the tumor grows in size or when the patient becomes symptomatic. A giant lipoma can cause symptoms of indigestion, abdominal pain, diarrhea, constipation, ulcer, intestinal obstruction, and even intussusceptions that require surgical or endoscopic treatment [2]. The pathogenesis of a lipoma in the parietal peritoneum is obscure and debatable as it has been classified as a primary peritoneal tumor. Some reports have loosely classified sub-peritoneal lipomas as primary peritoneal tumors, whereas other studies did not [3]. A giant lipoma is defined by Sanchez et al. as a lesion that measures at least 10 cm in one dimension or weighs a minimum of 1000 g [4]. Seven cases of parietal peritoneal lipoma were reported in 2016 (Table 1). The first case of lipoma of the parietal peritoneum was reported by Barut et al. [5] in 2016. Three patients presented to the emergency department with symptoms mimicking appendicitis. These patients presented with abdominal pain, either diffuse or localized to the right iliac fossa. One patient reported by Barut et al. presented with nausea, loss of appetite, and constipation, which were complaints similar to our case. The largest lipoma up to this point had a diameter of 22 cm as reported by Hanlim Choi et al. and weighed 942 grams [5–11]. CT and magnetic resonance imaging (MRI) scans have a significant role in diagnosing a giant intra-abdominal lipoma. Features associated with liposarcoma are lipoma with a size > 10 cm, presence of thick (> 2 mm) septa, presence of non-adipose areas, and lesions that are < 75% adipose tissue [12]. Lipomas

are best treated by a simple excision beyond the tumor capsule, whereas liposarcoma treatment involves a more complex resection with attention to adequate margins. Other differential diagnoses to be considered while diagnosing peritoneal lipoma are lipoblastoma, lymphangioma, and liposarcoma while lymphangiolipoma should also be considered when the tumor size is > 10 cm in size.

Table 1: Cases reported in literature with diagnosis of lipoma of parietal peritoneum and treatment

No	Reference	Year	Age (years)	Sex	Surgical procedure	Maximum diameter (cm)	Weight (kg)	Presentation
1	Barut et al. [5]	2006	67	F	Open	6	-	Abd pain, nausea vomiting
2	Bunker et al. [6]	2013	34	F	Laparoscopy	-	-	Abd pain
3	Bang et al. [7]	2014	75	M	Open	4.5	-	Abd pain, palpable mass
4	Shrestha et al. [8]	2014	32	M	Laparoscopy	3	-	Abd pain, loss of appetite
5	Sathyakrishna et al. [9]	2014	21	F	Laparoscopy	-	-	Abd pain
6	Salgaonkar et al. [10]	2016	79	M	Laparoscopy	6.3	-	Abd pain
7	Hanlim Choi et al. [11]	2018	36	M	Laparoscopy	22	0.94	Urinary frequency
8	Present case	2020	50	F	Open	40	3.7	Abd pain, loss of appetite

## Conclusion

This case is the rarest presentation of a lipoma and highlights the clinical manifestation based on the location and massive size of the tumor. The case highlights the need for consideration as one of the differential diagnoses for pain and mass abdomen. Surgical treatment is based on tumor size and tumor association with the surrounding structure.

## References

- Goldblum JR, Andrew L, Folpe, Sharon W, Weiss. Benign lipomatous tumors. In: Goldblum JR et al. editor. Enzinger and Weiss's Soft Tissue Tumors. 7th ed. Elsevier; 2020:476-519.
- Wolko JD, Rosenfeld DL, Lazar MJ, Underberg-Davis SJ. Torsion of a giant mesenteric lipoma. *Pediatr Radiol.* 2003 Jan;33(1):34-6. doi: 10.1007/s00247-002-0810-8. Epub 2002 Sep 25. PMID: 12497235.
- Levy AD, Arnáiz J, Shaw JC, Sobin LH. From the archives of the AFIP: primary peritoneal tumors: imaging features with pathologic correlation. *Radiographics.* 2008 Mar-Apr;28(2):583-607; quiz 621-2. doi: 10.1148/rg.282075175. PMID: 18349460.
- MR, Golomb FM, Moy JA, Potozkin JR. Giant lipoma: case report and review of the literature. *J Am Acad Dermatol.* 1993 Feb;28(2 Pt 1):266-8. doi: 10.1016/s0190-9622(08)81151-6. PMID: 8432930.
- Barut I, Tarhan OR, Cercı C, Cırıs M, Taslıyar E. Lipoma of the parietal peritoneum: an unusual cause of abdominal pain. *Ann Saudi Med.* 2006 Sep-Oct;26(5):388-90. doi: 10.5144/0256-4947.2006.388. PMID: 17019086; PMCID: PMC6074097.
- Bunker DL, Ilie VG, Halder TK. Torsion of an abdominal-wall pedunculated lipoma: a rare differential diagnosis for right iliac fossa pain. *Case Rep Surg.* 2013;2013:587380. doi: 10.1155/2013/587380. Epub 2013 May 23. PMID: 23781377; PMCID: PMC3676979.
- Bang CS, Kim YS, Baik GH, Han SH. A case of lipoma of parietal peritoneum causing abdominal pain. *Korean J Gastroenterol.* 2014 Jun;63(6):369-72. doi: 10.4166/kjg.2014.63.6.369. PMID: 24953615.
- Shrestha BB, Karmacharya M. Torsion of a lipoma of parietal peritoneum: a rare case mimicking acute appendicitis. *J Surg Case Rep.* 2014 Jun 18;2014(6):rju062. doi: 10.1093/jscr/rju062. PMID: 24941942; PMCID: PMC4062179.
- Sathyakrishna BR, Boggaram SG, Jannu NR. Twisting lipoma presenting as appendicitis-a rare presentation. *J Clin Diagn Res.* 2014 Aug;8(8):ND07-8. doi: 10.7860/JCDR/2014/9663.4728. Epub 2014 Aug 20. PMID: 25300572; PMCID: PMC4190759.
- Salgaonkar HP, Behera RR, Katara AN, Bhandarkar DS. Laparoscopic excision of a lipoma of parietal peritoneum. *J Minim Access Surg.* 2016 Apr-Jun;12(2):196-7. doi: 10.4103/0972-9941.178515. PMID: 27073320; PMCID: PMC4810961.
- Choi H, Ryu D, Choi JW, Xu Y, Kim Y. A giant lipoma of the parietal peritoneum: Laparoscopic excision with the parietal peritoneum preserving procedure - a case report with literature review. *BMC Surg.* 2018 Aug 2;18(1):49. doi: 10.1186/s12893-018-0382-7. PMID: 30068347; PMCID: PMC6071372.
- Kransdorf MJ, Bancroft LW, Peterson JJ, Murphey MD, Foster WC, Temple HT. Imaging of fatty tumors: distinction of lipoma and well-differentiated liposarcoma. *Radiology.* 2002 Jul;224(1):99-104. doi: 10.1148/radiol.224101113. PMID: 12091667.

This paper has been checked for language accuracy by JOSAM editors.

The National Library of Medicine (NLM) citation style guide has been used in this paper.