

A Case of Telangiectatic Osteosarcoma in a Dog

Gulbin SENNAZLI^{1*}, Ozge ERDOGAN¹, Yalcin DEVECIOGLU², Busra INAL²

¹Istanbul University Veterinary Faculty, Department of Pathology, 34320 Avcilar, Istanbul, Turkey

²Istanbul University Veterinary Faculty, Department of Surgery, 34320 Avcilar, Istanbul, Turkey

*Corresponding Author: Gulbin SENNAZLI, Istanbul Üniversitesi Veteriner Fakültesi
Patoloji Anabilim Dalı 34320, Avcılar, İstanbul
e-mail: ayildiz@istanbul.edu.tr

Geliş Tarihi / Received: 29.12.2011

ABSTRACT

A 10-year-old female Rottweiler was referred to the clinic of the Department of Surgery, Veterinary Faculty of Istanbul University with a history of spontaneous fracture in the right hind limb. Radiographical examinations showed proliferative bone tissue, osteoporosis and fracture in the distal part of the femur. An osteolytic malignant tumor was suspected. The affected hind limb was amputated and was presented to the department of the Pathology for histological examination. Histopathologically, the dog was diagnosed with telangiectatic osteosarcoma of the femur. The purpose of this study is to present clinical and histopathological features of a telangiectatic osteosarcoma which is rarely reported in dogs.

Key Words: Dog, osteosarcoma, telangiectatic osteosarcoma

ÖZET

BİR KÖPEKTE TELANJEKTATİK OSTEOSARKOMA OLGUSU

Fakültemizin Cerrahi Kliniği'ne 10 yaşındaki dişi Rottweiler ırkı bir köpek sağ arka bacakta spontan gelişen kırık şikayeti ile getirilmiştir. Radyografik muayenesi sonucunda proliferatif kemik dokusu, osteoporozis ve femur distalinde kırık saptandı. Osteolitik malign bir tümörden şüphe edilerek, sağ arka bacağa amputasyon uygulandı. Yapılan histopatolojik muayenede femurda telanjiektatik osteosarkoma teşhis edilmiştir. Bu çalışmanın amacı köpeklerde nadir bildirilen telanjiektatik osteosarkomanın klinik ve histopatolojik özelliklerini sunmaktır.

Anahtar Kelimeler: Köpek, osteosarkoma, telanjiektatik osteosarkoma

Introduction

Canine osteosarcoma is the most common primary bone tumor in dogs and is characterized by locally aggressive and highly metastatic behavior. (Cavalcanti et al., 2004; Dernell et al., 2007; Ru et al., 1998; Thompson and Pool, 2002). Various classification systems have been used for osteosarcomas, both in man

and in animals. The scheme used here is based on the nature of the matrix produced by the malignant cells and is consistent with that proposed in a bulletin of the World Health Organization. Osteosarcoma is classified into subtypes such as; poorly differentiated, osteoblastic, chondroblastic, fibroblastic, telangiectatic, giant cell type osteosarcomas. A similar classification system is used for

osteosarcomas in humans (Slayter et al., 1994). Telangiectatic osteosarcoma is a less common form of osteosarcoma (Norrdin et al., 1989). It is an aggressive tumor and is associated with a less favourable prognosis than all other forms of osteosarcoma and moreover is highly fatal. Tumor can metastasize easily (Slayter et al., 1994; Thompson and Pool, 2002). The clinical manifestations of telangiectatic osteosarcoma resemble those of conventional osteosarcoma. Dogs with osteosarcoma most often present with local tenderness or pain, a soft-tissue mass, and pathologic fracture (Discepolo et al., 2009).

The purpose of this study is to present clinical and histological features of telangiectatic osteosarcoma which was detected in the right hind limb of a 10-year-old female Rottweiler.

Case

A 10-year-old female Rottweiler was presented with a complaint of lameness at right hind limb. It was observed that the dog could not use her hind limb and had pain in genu and distal femur during the clinical examination. Radiography revealed osteophytes and osteoporotic areas in the distal part of the femur (Figure 1A, 1B). Lesions detected were suggestive of chondrosarcoma and osteosarcoma, thus biopsy was recommended. However it was declined by the owner. The dog was treated with non-steroidal anti-inflammatory drug. The patient was brought to our clinic again 4 months later. It was stated that no trauma existed and a spontaneous fracture occurred in the hind limb during walking. Clinical and radiographical evaluation showed oblique middle diaphyseal pathologic fracture at right femur. Furthermore, radiographs showed osteoporotic areas in the femur condylus (Figure 2 A, 2B). It was considered that the patient had osteosarcoma or chondrosarcoma, and amputation surgery was decided.

The dog was anesthetized with 6 mg/kg propofol IV, intubated and ventilated with 2% isoflurane. Amputation was performed with disarticulation technique. Ceftriaxone sodium was administered over 7 days at dose of

30 mg/kg daily intramuscular and carprofen was given 3.5 mg/kg/day PO postoperatively. Primary wound closure was observed and sutures were removed 10 days later. The amputated leg was submitted to the department of pathology. The samples were initially fixed in 10% neutral buffered formalin and then immersed in 5% nitric acid solution for decalcification. The specimens were routinely processed, and embedded in paraffin. Paraffin-embedded tissues were cut at 5 µm, stained with haematoxylin and eosin. For immunohistochemical staining, Avidin-biotin complex method was performed using primary monoclonal antibody against von Willebrand factor (factor VIII-related antigen) (DAKO) and all of the slides were examined by light microscopy. Suture was removed 10 days later.

Discussion

Gross inspection of the amputated right hind limb revealed multicystic hemorrhagic destructive bone-forming intramedullary lesion with cortical destruction and extension into the adjacent anterior soft-tissue compartment of the distal femur. The soft-tissue component of the mass was substantially larger than its intraosseous extent. Histologic evaluation showed large blood-filled cystic structures with a thick-walled lining and septa (Figure 3C, 3D). The septa contained markedly atypical malignant tumor cells with immature osteoid production. Tumorous regions were characterized by poor-staining, polygonal cells haphazardly arranged in sheets and poorly defined short, irregular streams, which often effaced normal tissue architecture. Individual cells had fairly distinct cell borders with moderate amounts of finely granular, eosinophilic cytoplasm. Nuclei were round to oval with finely stippled chromatin; a few contained a single, prominent nucleolus. Marked anisocytosis and anisokaryosis and rare mitosis were observed. Numerous, scattered multinucleated cells were associated with the neoplastic cells in all sites (Figure 3A, 3B). The neoplastic cells often were separated by pale amorphous eosinophilic material (osteoid) with regions of mineralization.

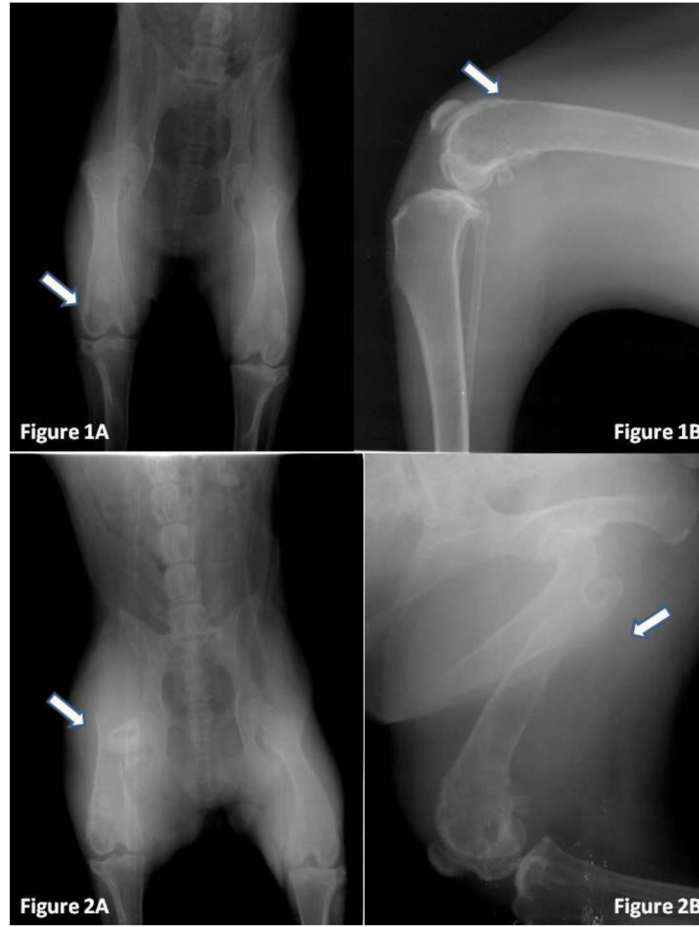


Figure 1A, 1B. Radiological assessments of the case: Osteophytes and osteoporotic areas in the distal part of femur (during the first examination).

Şekil 1A, 1B. Vakanın radyolojik değerlendirmesi: femur distalinde osteofitik ve osteoporotic alanlar (ilk muayene sırasında).

Figure 2A,2B: Lytic distal metaphyseal lesion with a pathologic fracture of the distal femur (4 months later).

Şekil 2A, 2B. Distal femurun patolojik kırığı ve litik metafizial lezyonu (4 ay sonra).

The most frequently affected site for tumors is the distal femur (Discepola et al., 2009) which is compatible with that of the current case. Characteristically, telangiectatic osteosarcoma is primarily (>90%) composed of multiple aneurysmally dilated cavities that contain blood, with viable high-grade sarcomatous cells in the peripheral rim and septations around these spaces (Murphey et al., 2003). It is important to differentiate telangiectatic osteosarcoma from hemangiosarcoma, hemangioma, aneurysmal bone cysts, giant cell tumors of bone, and metastatic carcinomas. It is distinguished most easily from hemangioma and hemangiosarcoma

by the production of osteoid, the presence of osteoblast, and lack of endothelium lining the blood-filled cysts (Slayter et al., 1994). In this case, negative immunohistochemical staining of the lining cells of the blood-filled cysts for von Willebrand factor indicated the tumor was nonangioblastic in origin (Figure 4). Telangiectatic osteosarcoma also must be differentiated from aneurysmal bone cyst. They have many common histologic features. In comparison, the mesenchymal cells in telangiectatic osteosarcoma are exceptionally proliferative and there usually is soft tissue invasion, features not seen in typical bone cysts (Brellou et al., 2004).

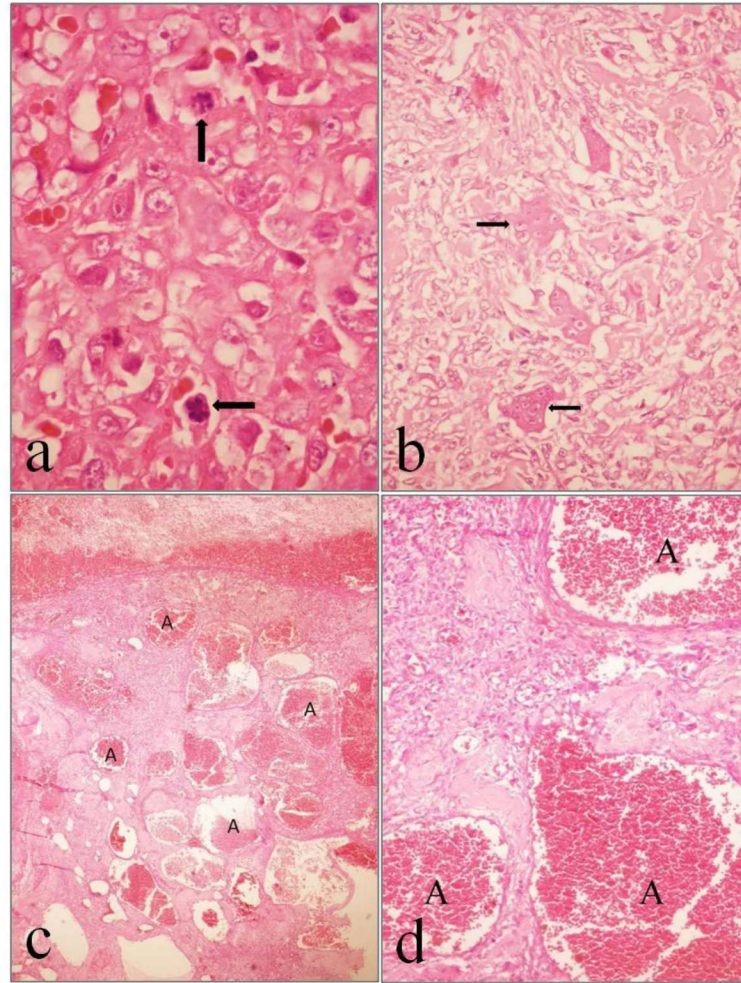


Figure 3 a, b. Undifferentiated sarcomatous cells with numerous mitosis and giant tumor cells (arrow) (H&E, a:x100, b:x40).

Şekil 3 a. Çok sayıda mitotik figür içeren kötü diferensiyel sarkomatöz hücreler (ok) **b.** tümör dev hücreleri (ok) (H&E, a:x100, b:x40).

Figure 3 c, d. Numerous small and large, blood filled spaces lined by tumor cells (not endothelial cells) (A), and small spicules of bone matrix (H&E, a:x10, b:x20).

Şekil 3 c, d. Tümör hücreleri ile döşeli (endotelial hücreler yok), kan ile dolu çok sayıda küçük ve büyük boşluklar (A) ve küçük kemik spikülleri (H&E, a:x10, b:x20).

Metastases of telangiectatic osteosarcomas generally resemble the primary tumor and have highest prevalence, especially to the lung usually through the blood stream. In one study, dogs with telangiectatic osteosarcoma had a 100 percent metastatic rate (Hammer et al., 1995). Generally, most osteosarcomas of dogs produce metastatic disease within six months of clinical onset (Dernell et al., 2007; Thompson and Pool, 2002). The patient died 3 months later

following the operation and during that period the owner did not refer for further clinical examination. In conclusion, the histologic findings of telangiectatic osteosarcoma involving distal femur in a dog were similar to those seen in other cases of telangiectatic osteosarcoma in dogs. Immunohistochemistry was a useful tool for assessing malignancy of the telangiectatic osteosarcoma and ruling out other differential diagnoses.

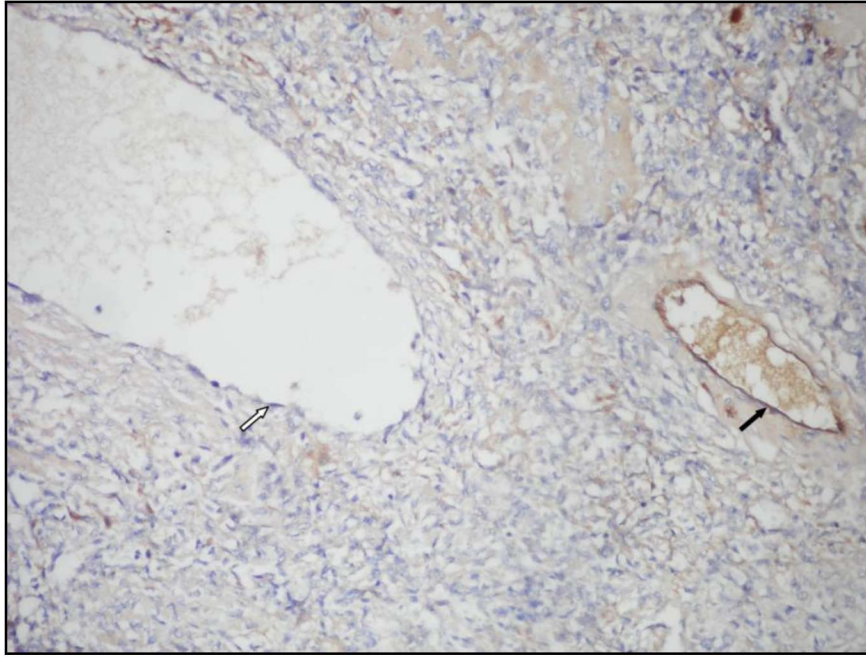


Figure 4. Immunohistochemical staining for von Willebrand factor. Tumor cells lining the cavities are negative (white arrow) and endothelial cells (black arrow) stain positive (Avidin-biotin-complex x 20).

Şekil 4. vWF için immunohistokimyasal boyama. Boşlukları döşeyen tümör hücreleri negatif (beyaz ok) ve endotel hücreleri pozitif (siyah ok) (Avidin-biotin-complex x 20).

REFERENCES

- Brellou, G., Papaioannou, N., Patsikas, M., Polizopoulou, Z., Vlemmas, I., 2004.** Vertebral telangiectatic osteosarcoma in a dog. *Veterinary Clinical Pathology* 33 (3), 159-162.
- Cavalcanti, J.N., Amstalden, E.M.I., Guerra, J.L., Magna, L.C., 2004.** Osteosarcoma in dogs: clinical-morphological study and prognostic correlation. *Brazilian Journal of Veterinary Research and Animal Science* 4, 299-305.
- Dernell, W., Ehrhart, P., Straw, R.C., Vail, D.M., 2007.** Tumors of the skeletal system. In: Withrow, S.J. (Ed), *Small Animal Clinical Oncology*. Saunders Elsevier, pp. 540-567.
- Discepolo, F., Powell, T.I., Nahal, A.N., 2009.** Best cases from the AFIB. Telangiectatic osteosarcoma: Radiologic and pathologic findings. *RadioGraphics* 29 (2), 380-383.
- Hammer, A.S., Weeren, F.R., Weisbrode, S.E., Padgett, S.L., 1995.** Prognostic factors in dogs with osteosarcomas of the flat or irregular bones. *Journal American Animal Hospital Association* 31 (4), 321-326.
- Murphey, M.D., Temple, H.T., Gannon, F.H., Jelinek, J.S., Malawer, M.M., 2003.** Telangiectatic osteosarcoma radiologic-pathologic comparison. *Radiology* 229 (2), 545-553.
- Norrdin, R.W., Powers, B.E., Torgersen, J.L., Smith, R.E., Withrow, S.J., 1989.** Characterization of osteosarcoma cells from two sibling large-breed dogs. *American Journal Veterinary Research* 50, 1971-1975.
- Ru, G., Terracini, B., Glickman, L.T., 1998.** Host related risk factors for canine osteosarcoma. *The Veterinary Journal* 156, 31-39.
- Slyter, M.V., Boosinger, T.R., Pool, R.R., Dammrich, K., Misdorp, W., Larsen, S., 1994.** Histological classification of bone and joint tumors of domestic animals. *World Health Organization 2nd series, vol.1. Armed Forces Institute of Pathology, American Registry of Pathology, Washington D.C.* 9-11.
- Thompson, K.G., Pool, R.R., 2002.** Tumors of bones. In: Meuten, D. J. (Ed), *Tumors in Domestic Animals*. Iowa State Press, pp. 245-283.