



Training Modalities in Robotic Prostate Cancer Surgery

Abdullah Erdem Canda*

Murat Keske**

Muhammed Ersagun Arslan**

Ali Fuat Atmaca*

ABSTRACT

Robotic surgery is increasingly being performed worldwide in the surgical treatments of various diseases. Radical prostatectomy provides long-term cancer control in patients with localized prostate cancer. Robotic radical prostatectomy (RARP) has increasingly become a preferred treatment of choice both by patients and urologists since its introduction in 2001. The training of this surgical approach is a very important subject. This paper was prepared following reviewing the published literature on training on RARP, an internet bases search related with robotic prostate cancer surgery training and reviewing the training programs of the centers who offer training in robotic urology. In the present paper, we summarized the training modalities in RARP including; I. Video based learning: watching edited and non-edited surgical videos, II. Attending courses, symposiums and meetings related with robotic surgery, III. Watching live robotic surgical cases in the operating room, IV. Training with simulators, V. Training with the surgical surgical robot on training materials, VI. Training with the surgical robot on live animals under anesthesia in the laboratory, VII. Patient site assisting during robotic surgical procedures, VIII. Performing robotic surgery as a console surgeon under the supervision of a experienced mentor (fellowship program), IX. Assessing outcomes of the robotic surgical procedures (learning curve) and X. Ankara Atatürk Hospital Robotic Radical Prostatectomy Training Model. Training in robotic prostate cancer surgery includes a variety of modalities. Effective and sufficient training could be obtained with the combination of the suggested training modalities.

Keywords: Training modalities, robotic surgery, prostate cancer surgery.

* Dr., Yıldırım Beyazıt Univeristy, School of Medicine, Ankara Atatürk Training and Research Hospital, Department of Urology, Ankara, Turkey

** Ankara Atatürk Training and Research Hospital, Department of Urology, Ankara, Turkey

Robotik Prostat Kanseri Cerrahisinde Eğitim Yöntemleri

ÖZ

Robotik cerrahi, tüm dünyada çeşitli hastalıkların cerrahi tedavisinde giderek artan sıklıkta uygulanmaktadır. Lokalize prostat kanseri tedavisinde radikal prostatektomi uzun süreli kanser kontrolü sağlamaktadır. İlk kez 2001 yılında uygulanmaya başlaması ile birlikte robotik radikal prostatektomi (RARP), hem hastalar hem de ürologlar tarafından prostat kanserinde tercih edilen ameliyat yöntemi haline gelmiştir. Bu modern ameliyat yönteminin eğitimi de oldukça önemli bir konudur. Bu makale, RARP ameliyat yönteminin eğitimi ile ilgili uluslararası literatür incelenerek, internet üzerinden robotik prostat kanseri cerrahisi eğitimi araştırılarak ve bu konuda eğitim veren merkezlerin eğitim programları incelenerek hazırlanmıştır. Robotik prostat kanseri cerrahisi eğitimi ile ilgili şu basamaklar özetlenmiştir; I. Ameliyatlara ait video izlemeye dayalı eğitim, II. Robotik cerrahi ile ilgili kurslara, sempozyumlara ve toplantılara katılmak, III. Ameliyathanede robotik cerrahi ameliyatlarını izlemek, IV. Simülatörler üzerinde eğitim almak, V. Çeşitli eğitim materyalleri üzerinde cerrahi eğitim ile eğitim yapmak, VI. Anestezi altındaki çeşitli hayvan modelleri üzerinde laboratuvarda cerrahi robot ile eğitim yapmak, VII. Robotik cerrahi ameliyatlarında hasta başında asistanlık yapmak, VIII. Bu konuda deneyimli bir cerrahın gözetiminde konsol başında bire bir cerrahi eğitim almak, IX. Öğrenme eğrişi döneminde cerrahın kendi sonuçlarını değerlendirmesi ve X. Ankara Atatürk Hastanesi Robotik Radikal Prostatektomi Eğitim Modeli. Robotik prostat kanseri eğitiminde birçok yöntem kullanılabilir. Bu yöntemlerin bir arada kullanılması ile etkili ve yeterli eğitim sağlanabilmektedir.

Anahtar Sözcükler: Eğitim yöntemleri, robotik cerrahi, prostat kanseri cerrahisi.

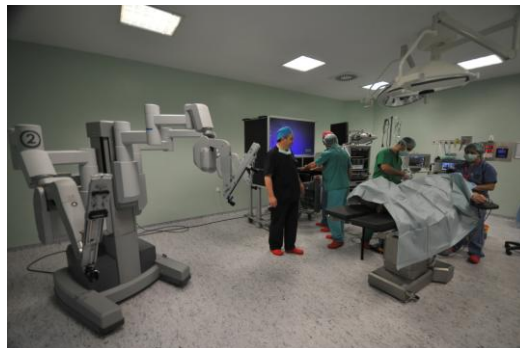INTRODUCTION

Robotic surgery is increasingly being performed worldwide in the surgical treatments of various diseases including urologic, gynecologic, colorectal, general surgery, cardiac, thoracic and otolaryngology surgical procedures.

Radical prostatectomy (RP) provides long-term cancer control in patients with localized prostate cancer (PCa) (1). Robotic radical prostatectomy (RARP) has increasingly become a preferred treatment of choice both by patients and urologists since its introduction in 2001 (2).

Using a high-technology surgical robot, particularly by well-trained surgeons enables the surgeon to perform complex surgical procedures by inserting the robotic surgical instruments into the abdominal cavity through small abdominal openings. The surgical robot has the advantage of enabling the console surgeon to perform complex procedures more easily, providing three-dimensional (3D) and magnified views, higher grades of wristed hand movements, and decreased hand tremor, while the fourth robotic arm offers additional assistance and tissue retraction which facilitates the learning curve (3).

The number of centers performing robotic surgery is increasing and training in the field of robotic surgery is a very important issue. We have been using robotic surgery at our institution since February 2009 in Ankara, Turkey by the da Vinci-S four-arm surgical robot (Intuitive Surgical, Sunnyvale, CA). We are applying robotic urology in prostate cancer, bladder cancer, kidney cancer and diseases of the upper urinary tract in our department (Picture 1) (4-7). Herein, we summarized the training modalities in RARP.



Picture 1. Appearance of the robotic surgery operating room (Ankara Atatürk Training and Research Hospital, Robotic Surgery Operating Room).

I. Video based learning: watching edited and non-edited surgical videos

Currently, with the help of the internet and websites, it is very easy to have online access to many previously uploaded surgical video contents about robotic urologic procedures. Watching the videos gives the opportunity of observing, learning and comparing the surgical techniques of various surgeons from different parts of the world. In addition, the narrations that accompany to the videos give

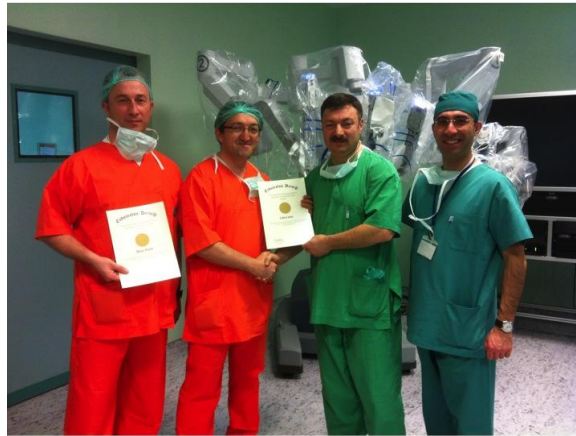further teaching opportunity. Apart from internet, the recorded videos are frequently available as a dvd that could be obtained for training which we think are very useful.

II. Attending courses, symposiums and meetings related with robotic surgery

Didactic sessions can provide the trainee an opportunity to become well acclimated with the components and the proper use of the surgical robot. A variety of robotic urology courses are organized by many international organisations such as European Association of Urology (EAU), American Urology Association, (AUA) and European Robotic Urology Society (ERUS).

Robotic surgical “mini-courses” exist in many formats in the United States. These programs typically run several days to a week and consist of didactic lectures, robotic labs with inanimate objects or cadavers, and an expert proctor to observe trainees during their initial cases. McDougall et al., have recently reported their initial experience with training in robotic surgery given to postgraduate urologists during a 5-day “mini-residency” (8). Of the 21 participants who completed their course, 95% were performing robotic surgery. Although it appears that mini-courses can provide the fundamental skills necessary to perform robotic surgery, it is likely that these surgeons still face a significant learning curve as they begin performing these types of surgeries.

In Turkey, Turkish Endourology Society has organized robotic urology courses in last few years. Our center at Ankara Atatürk Training and Research Hospital in Ankara, Turkey has been an active part of this highly specialized training in our country (Picture 2).

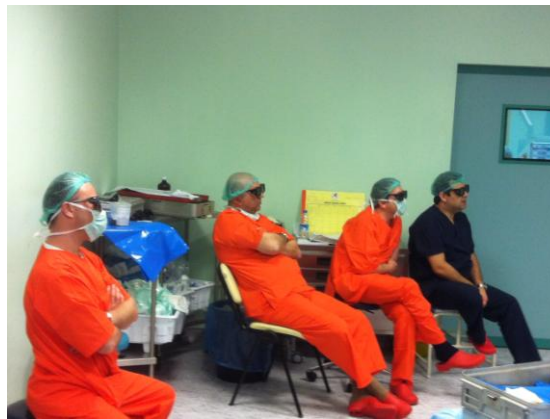

Picture 2. Course participants with certificates after the completion of a robotic radical prostatectomy course in 2013 (Ankara Atatürk Training and Research Hospital, Robotic Surgery Room).

III. Watching live robotic surgical cases in the operating room

One of the best ways of training is watching the whole robotic surgical procedure in the operating room. The trainee has the opportunity of observing patient preparation, patient positioning, anesthesiology work-up, patient draping, robot docking, assistance and the surgical procedure itself with all details. Patel et al stated that pre-recorded operative footage or live operative cases in the operating room can provide the trainee with an opportunity to directly observe the execution of the various steps involved in completing a specific robotic procedure from start to finish (9).

In our center, we have a 3D monitor that gives the opportunity of watching the robotic surgical procedures in 3D by wearing 3D eyeglasses similar to the console surgeon (Picture 3). This gives the chance of seeing every detail that is very important in robotic surgery.



Picture 3. Watching live robotic surgical cases in the operating room with 3D eyeglasses (Ankara Atatürk Training and Research Hospital, Robotic Surgery Room).

IV. Training with simulators

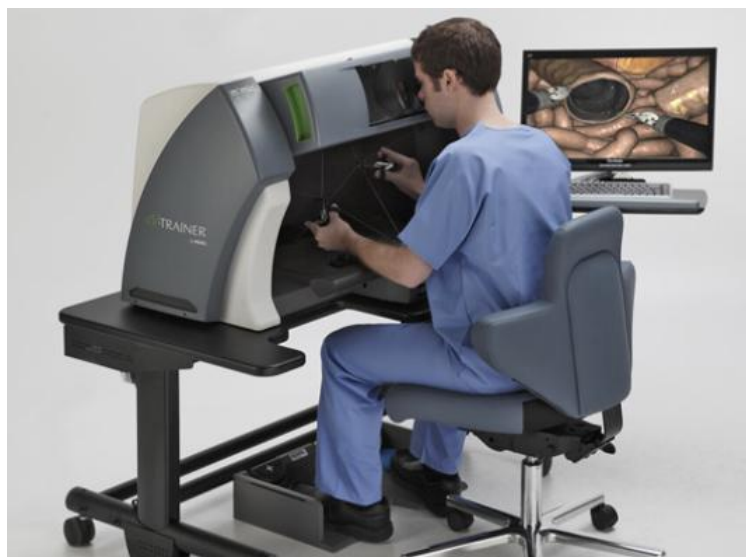Robotic surgery simulation is the safest, most practical form of training for novice surgeons to carefully and meticulously develop the crucial motor and cognitive skills demanded for performing robot-assisted surgery. Simulation training poses no risk to a live patient, so novice surgeons are able to freely practice various tasks.

The use of virtual reality (VR) surgical simulators has been shown to improve subsequent clinical performance and can shorten the learning curve associated with the acquisition of a new technological skill (10,11). Unfortunately there are only a few VR robotic simulators currently in development, most of which have not been fully validated. In addition, the cost of such VR robotic simulators may be significantly prohibitive for most centers. Software from MIMIC Technologies (Seattle, Washington) has recently been incorporated in the da Vinci Si system so that the surgeon console can be used for VR training without the need for the patient side cart or instruments (Picture 4). This teaching device, while having gone through

extensive development with expert input and having preliminary assessment of face and content validity, is yet to undergo extensive construct and predictive validity testing.

One of the major challenges of robotic surgical training is to adapt to the lack of tactile feedback during surgery. The robotic surgeon is left to rely primarily on visual clues, anatomic landmarks, and tissue architecture as a substitute for tactile feedback that an open surgeon would normally rely upon.

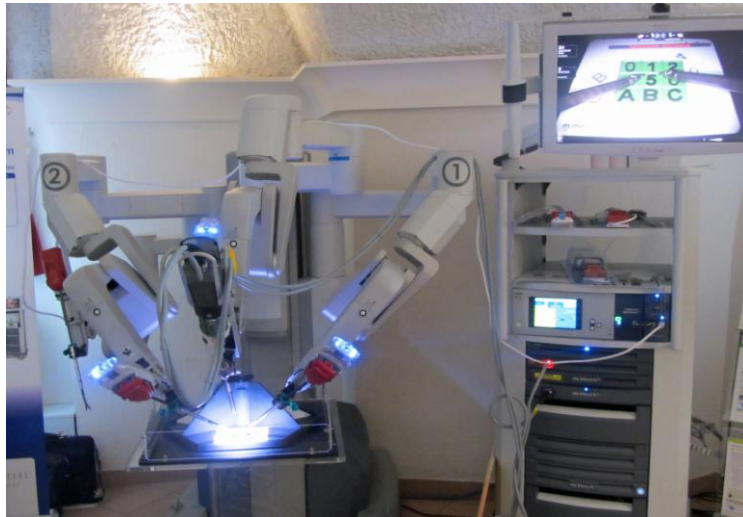Surgical simulators of varying levels of complexity have become increasingly popular over the last two decades due to the introduction of laparoscopic surgery. Even basic laparoscopic simulators, such as box trainers, have proven to be effective in improving the performance of advanced laparoscopic techniques, including intracorporeal suturing (12). Studies have also shown that individuals without robotic experience who are trained to perform robotic tasks can significantly improve the time to complete the task with training (13). More recently, computer based simulators of the da Vinci surgical system have been developed (14). The computer based simulator reported by Sun et al. provides a two-handed interface to control a model of the da Vinci robot. Computer models would be attractive tools for practicing simple surgical skills and gaining familiarity with the robotic system prior to live use. Virtual reality training simulators have the potential to provide an even more “real-life” training experience. In addition to novice trainees, virtual reality simulators could also be useful to experienced robotic surgeons in preparing for particularly difficult cases. Although many VR simulators are still undergoing development, they appear to have promise for training in the near future. A potentially significant drawback to the widespread use of sophisticated surgical simulators is cost. The high cost of these more complex simulation devices may preclude their widespread application and limit their use to large academic centers. However, surgical simulators have important impact on robotic training.



Picture 4. Simulator for robotic surgery training.

V. Training with the surgical robot on training materials

Robotic surgery training curriculum involves inanimate dry lab practice (Picture 5). Repetition of basic skills tasks such as ring-peg transfer, precision cutting or simple suturing and knot tying allows the trainee to become facile in instrument movement and articulation, camera and clutch navigation, and to become familiar with the 3-dimensional environment, all of which are requisite skills necessary to perform more complex procedural tasks. Other models that simulate specific tasks such as the urethrovesical anastomosis may also be used. Unfortunately, unlike traditional laparoscopy where all that is needed is a pelvic box trainer, laparoscopic instruments and a camera with monitor, dry lab robotic training requires access to a fully functional robot. This type of educational experience may not be feasible at all training centers. Therefore, alternative teaching strategies for this portion of the curriculum have been developed and are becoming more prevalent in training programs.



Picture 5. Dry-lab robotic surgery training.

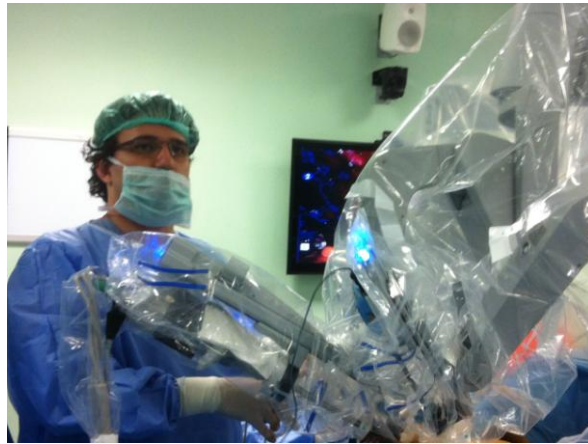VI. Training with the surgical robot on live animals under anesthesia in the laboratory

Before training on actual patients in the operation room, gaining experience on live animals gives useful information. Trainees get used to the controls, improve their hand-foot-eye coordination with the controls on the console, learn about the hemorrhage and hemostasis in real tissue. Also because of the lack of tactile feedback trainee can get used to this type of surgical approach on robotic surgery by watching the signs of the reactions of the tissue. It was reported to be useful in training before getting hands on the patient.

VII. Patient site assisting during robotic surgical procedures

Before starting to practice as a console surgeon, having adequate patient site assistant experience is very important in robotic surgery (Picture 6). Following serving as a patient site assistant in sufficient amount of cases, the trainee gains experience of the whole procedure including preparing the robot, docking and undocking, placing the trocars properly and introducing the robotic surgical instruments. Most importantly, the trainee becomes an active part of the surgery during patient site assistance that prepares him/her in terms of learning every detail of the surgical procedure to become a console surgeon soon. Many authors have suggested to start as a patient site assistance in training robotic surgery before getting hands on the console to become familiar with the robotic surgery and steps of the operations (9,15-17).

Although the necessity of starting as a bedside assistant is emphasized, the number of cases to be adequate remains without a consensus. However, published reports mostly suggest at least 10 cases of experience (18,19).

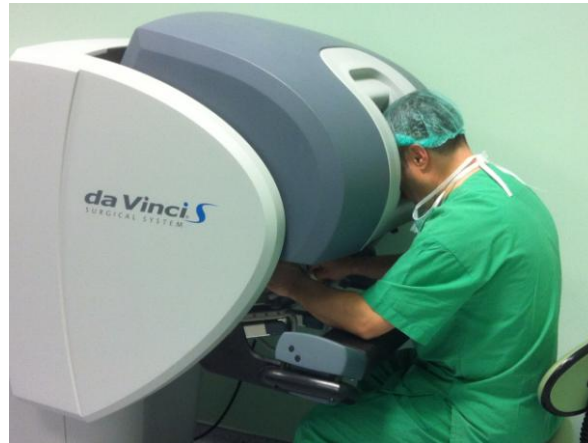

Picture 6. Patient side assisting (Ankara Atatürk Training and Research Hospital, Robotic Surgery Room).

VIII. Performing robotic surgery as a console surgeon under the supervision of a experienced mentor (fellowship program)

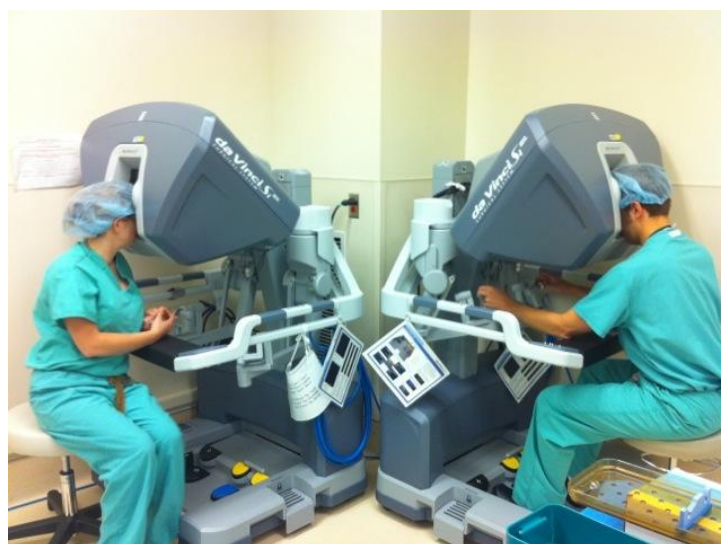After gaining experience following performing as a bedside assistant, the next step is to participate in the surgery as the console surgeon (Picture 7). Under the supervision of an expert surgeon, the trainee accomplishes the tasks required in a stepwise manner. The supervising surgeon may be at the bedside, with the trainee at the console or in a dual console taking control whenever it is needed. Meanwhile the supervisor gives feedback about the situation and intervenes if needed. When the trainee is successful in performing the specific part of the surgery and the supervising surgeon is satisfied with the work, he will be able to pass to the next level. After performing all the steps properly, if the supervisor surgeon thinks the trainee is adequate, he/she will be able to perform the whole operation by himself/herself. This step by step advancing curriculum is suggested in several studies (17, 20, 21). In

addition, most of the reports suggest recording the procedures and watching it after the procedure (22). Thus the trainee and the mentor can review the procedure and evaluate the technique that was applied which gives valuable information about the situation.



Picture 7. Console training (Ankara Atatürk Training and Research Hospital, Robotic Surgery Room).

A robotic surgeon in training learns surgery through the classic way of “supervised trial and error”. The da Vinci SI Surgical System offers a dual console used for both training and collaboration (Picture 8). During a dual console operation, each surgeon sits at his or her individual console and can see the same high definition images of the anatomy from the 3D endoscope. When the dual console is used for training, control over instruments can be easily and quickly exchanged during surgery meaning the teaching/mentoring surgeon can hand over control of the instruments to the resident/fellow at any time. This enables a see-and-repeat model of instruction designed to accelerate the learning curve (23).



Picture 8. Dual console, da Vinci Surgical System Si.

IX. Assessing outcomes of the robotic surgical procedures (learning curve)

Like all surgery techniques, robotic operations also have a learning curve. In RARP, the number of cases to overcome the learning curve is considered to be 20-250 cases (21). There are some parameters to assess the learning curve such as complications rates, operation time, positive surgical margin (PSM) rates, continence rates and erectile function. Zorn et al reported similar outcomes showing RARP is a safe and feasible even in the learning curve period (24). It is expected that intraoperative, postoperative and perioperative parameters improve as the number of the cases increase. It has been reported that it is still safe to perform RARP during learning curve with acceptable complication rates, transfusion rates, continence rates and PSM rates (in PT2 tumours) (25).

X. Ankara Ataturk Hospital Robotic Radical Prostatectomy Training Model

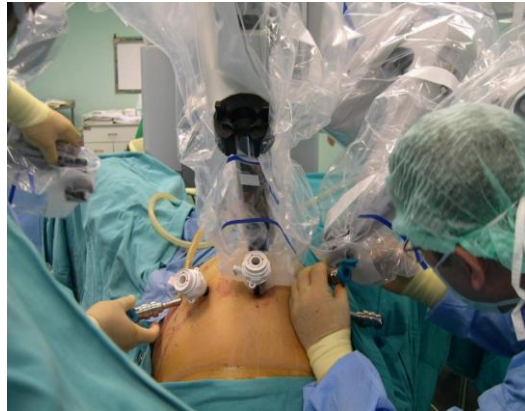We have been performing robotic urology in Ankara, Turkey since February 2009 and our team is the first that started robotic surgery in Ankara. To date, we have performed more than 600 cases of RARP.

PART I: Observation of the robotic surgical cases in the operating room

In our training model, the trainee starts with observing the live robotic urological procedures in our robotic surgery operating room. A large sized 3D monitor is available for training purposes and the trainees watch the cases by putting on 3D eyeglasses that enables them to see 3D like the operating console surgeon. This gives the opportunity of seeing every detail of the procedure with magnified vision that we think makes an important contribution for training.

PART II: Patient site assisting

Following watching many cases on the 3D monitor, the next step is to serve as a patient site assistant surgeon. This includes preparation of the patient in the operating room, patient positioning, abdominal port insertion, robot docking (Picture 9) and assisting during the procedure. We described details of how to assist in RARP with captured surgical pictures from our own cases recently (26). We suggest assisting at least 50 cases before proceeding to performing console surgery.



Picture 9. Robot docking.

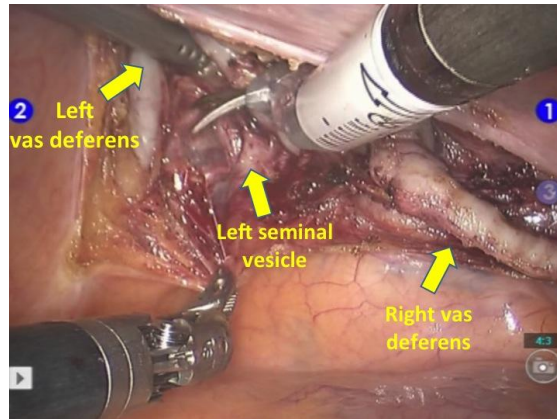
PART III: Console training under supervision in a stepwise method

We start training in a stepwise system and we have divided the whole procedure into several steps. The trainee starts with the initial step under supervision and following having sufficient experience and gaining enough confidence with that step he/she proceeds to the next one. Therefore, in a stepwise learning method the whole procedure could be learned efficiently.

By using this method, overall 8 urologists have been trained at our institution. We described details and surgical technique of performing RARP with captured surgical pictures from our own cases recently (4,27).

1st STEP: Exposing Douglas pouch, dissecting seminal vesicles & vas deferences (Picture 10)

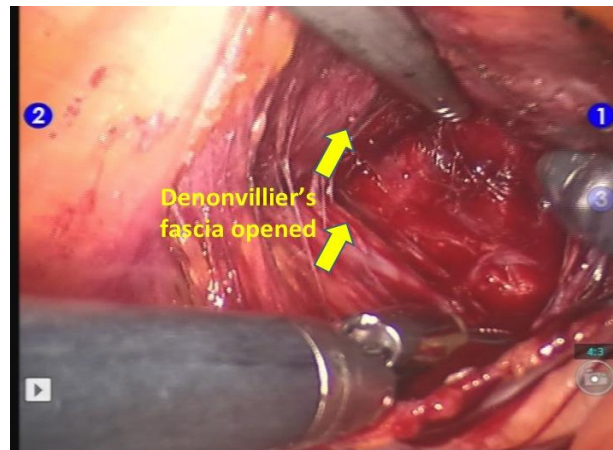
The 4th-arm with Prograsp forceps is used to retract the sigmoid colon posteriorly that creates a larger space and exposes the Douglas pouch for the surgeon. Procedure is started by making an incision on the anterior peritoneal covering of the Douglas pouch, approximately 1 cm proximal to its reflection on rectum. Both vas deferences and seminal vesicles are identified and dissected. In order to prevent thermal injury to the neurovascular bundles (NVB), cautery is not applied particularly on the lateral sides of the seminal vesicles. Both vas deferences are cut through their lateral sides. Hem-o-Lock[®] clips are applied during lateral dissection of the seminal vesicles to control bleeding rather than using cautery in order not to cause thermal injury to the NVBs.



Picture 10. Dissection of seminal vesicles and vas deferences.

2nd STEP: Identification of the Denonvillier's fascia and its opening (Picture 11)

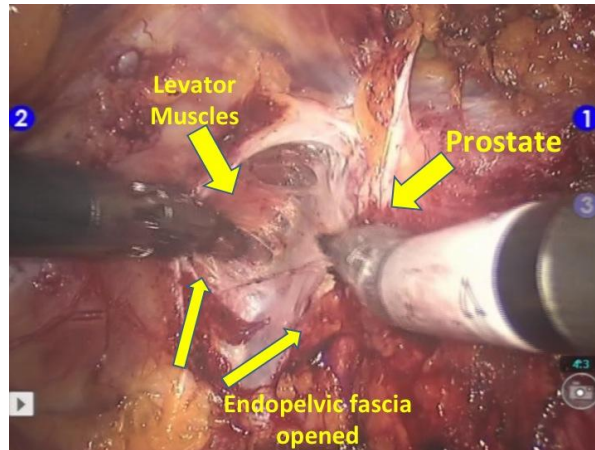
Denonvillier's fascia is identified below seminal vesicles and cut vas deferences. Console surgeon cuts the Denonvillier's fascia with monopolar curved scissors and pararectal fat tissue appears. Thereafter, it might be possible to dissect the prostate from the rectum up to its apex.



Picture 11. Denonvillier's fascia is opened.

3rd STEP: Identification and exposure of lateral pelvic fascia, levator muscles and puboprostatic ligaments (Picture 12)

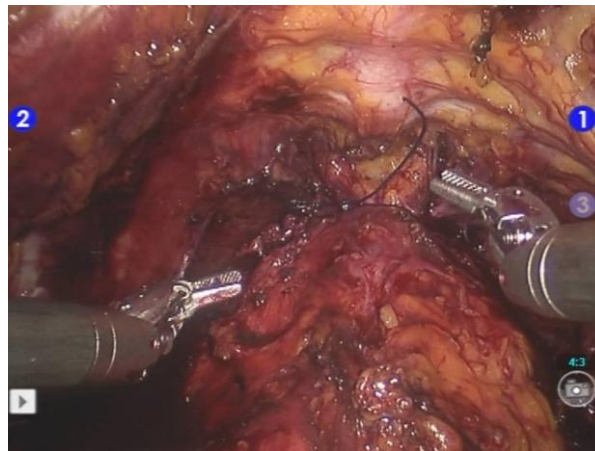
Following completion of the posterior dissection, parietal peritoneum is incised and dissected off lateral to the medial umbilical ligaments on both sides. Anterior attachments between bladder and abdominal wall are taken down by Maryland monopolar curved scissors and Retzius space is entered. After defatting of the periprostatic area, superficial dorsal vein is identified, cauterized and cut.



Picture 12. Levatorani muscle fibers are dissected off all the way along the lateral prostatic fascia.

4th STEP: Ligation of dorsal venous complex (Picture 13)

Following identification of the prostatic apex, dorsal venous complex (DVC) is identified and suture tied distal to the apex of the prostate (40 mm needle, 0 Vicrylsuture). A sliding stitch is used in order to tie the dorsal venous complex.

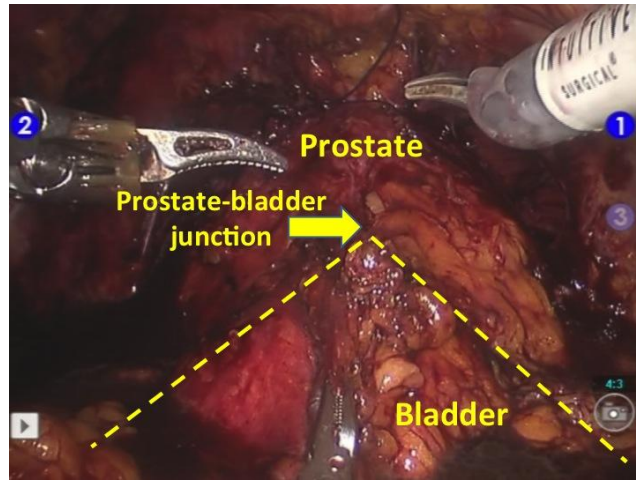


Picture 13. Ligation of dorsal venous complex.

5th STEP: Identification of the intersection of prostate and bladder (Picture 14)

Detrusor apron overlying the prostate anteriorly is identified and dissected superiorly until the entrance of urethra into the prostate, at bladder base is observed where its anterior wall was incised. In order to find the coalescence point of the urinary bladder and prostate, the console surgeon holds the anterior bladder wall with the 4th-arm and hooks it up. This forms a triangle shape between the bladder and the prostate that exactly shows the coalescence line of these two organs. Then, the

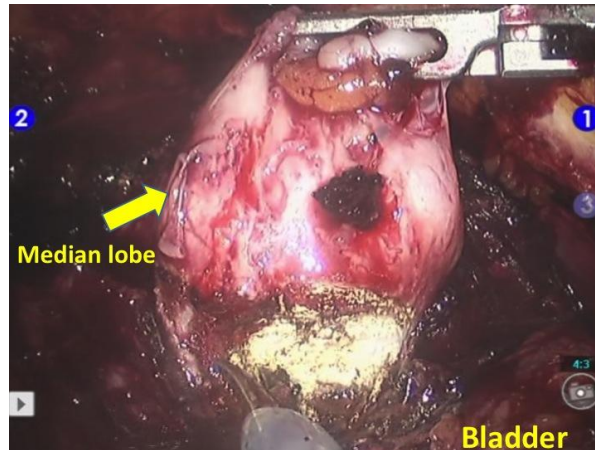
console surgeon opens the bladder starting from this coalescence point while the 4th-arm hooks up the bladder and enters the bladder easily. This manoeuvre facilitates preservation of the bladder neck.



Picture 14. 4th-arm hooks up the anterior bladder wall forming a triangle shape that exactly shows the coalescence line of these two organs.

6th STEP: Dissection of the median lobe and posterior prostatic dissection (Picture 15)

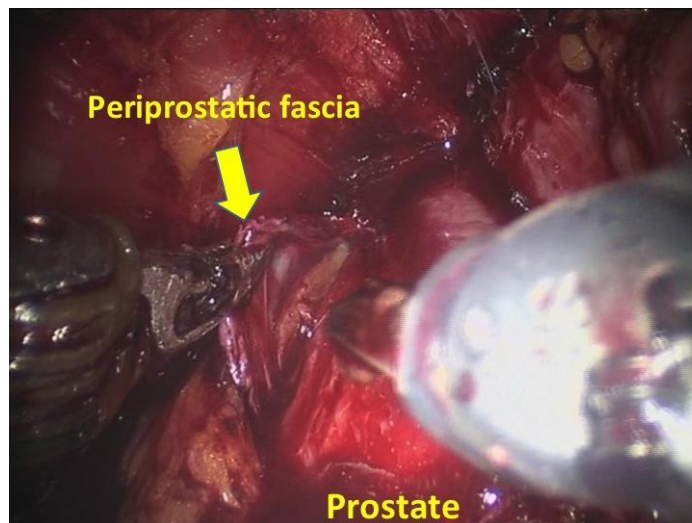
Posterior neck area was checked for the presence of median lobe and incision of the urethra at this level is completed. If a median lobe is detected, it is important to find the intersection point of the median lobe and bladder neck. In order to better expose this area, the console surgeon grasps the tip of the median lobe with the 4th-arm and holds it up that exposes the line between the bladder neck and the median lobe. In the presence of larger median lobes, a stitch could be passed through the median lobe and is hooked up with the 4th-arm. Thereafter, incision through the plane between the bladder neck and median lobe is performed. This manoeuvre with the 4th-arm is important in order to enter the correct space. The detrusor muscle connection between the bladder and the prostate is cut posteriorly and the predissected space at the very beginning of the RARP procedure through the Douglas pouch is entered.



Picture 15. Dissection of the median lobe.

7th STEP: Neurovascular bundle preservation (Picture 16)

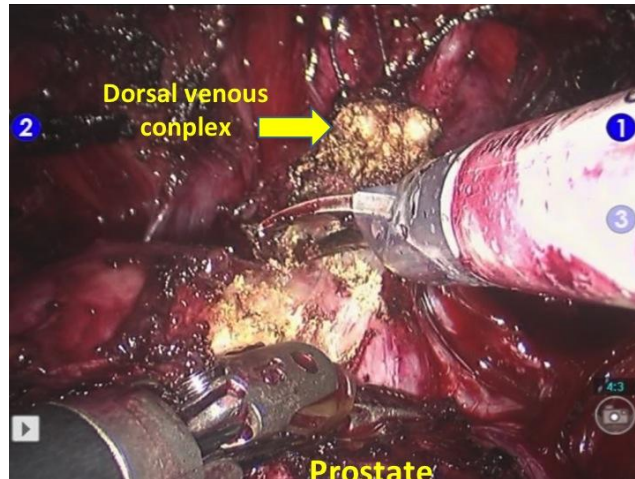
Starting from the prostatic base, periprostatic fascia is released by anterior release technique for NVB preservation. Intrafascial versus interfascial dissection is performed due to the patient and tumor characteristics.



Picture 16. High anterior release of the periprostatic fascia.

8th STEP: Division of dorsal venous complex and membranous urethra (Picture 17)

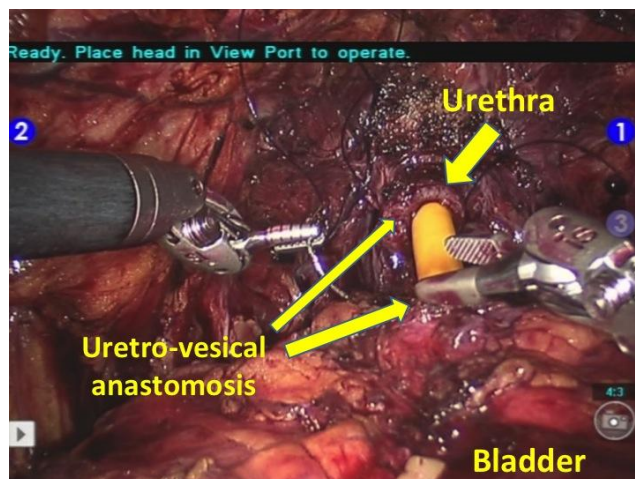
Following prostate is completely released from the surrounding structures, dorsal venous complex is cut by monopolar curved scissors. Urethra is cut as close as to the prostatic apex in order to preserve maximal urethral length without using any cautery.



Picture 17. Division of deep venous complex.

9th STEP: Performing urethro-vesical anastomosis (Picture 18)

We use absorbable 3/0 polydioxanone (PDO), 36 cm violet, double armed, round 16 mm, ½ running sutures for urethra-vesical anastomosis by using the van Velthoven technique. The same suture is used for posterior Rocco reconstruction. An 18 Frfoley urinary catheter is used for this anastomosis. Following completion of the anastomosis, bladder is distended with 100 cc sterile saline in order too see if the anastomosis is watertight. A pelvic drain in inserted after the surgery through the robotic trocar located on the right abdomen used for the 4th-arm. On the postoperative 1st-week, we perform a cystography and if no leakage is present, urethral catheter is withdrawn.



Picture 18. Urethro-vesical anastomosis.

Bilateral extended pelvic lymph node dissection is performed in patients who have an intermediate- or high-risk for pelvic lymph node (LN) metastasis according to Partin's tables with an >5% risk of LN involvement by prostate cancer.

Prostate is extracted from the abdomen after the enlargement of the supra-umbilical 12 mm sized camera port site following inclusion into the endobag. Thereafter, we grossly examined the prostate for any suspicious areas.

REFERENCES

- Roehl KA, Han M, Ramos CG, Antenor JA, Catalona WJ. Cancer progression and survival rates following anatomic radical retropubic prostatectomy in 3,478 consecutive patients: long-term results. *J Urol* 2004;172:910-914.
- Badani KK, Kaul S, Menon M. Evolution of robotic radical prostatectomy: assessment after 2766 procedures. *Cancer* 2007;110:1951-8.
- Canda AE, Balbay MD. Robotic radical cystectomy for bladder cancer: Current perspectives. *European Medical Journal Urology* 2014;1:1014-110.
- Canda AE, Atmaca AF, Akbulut Z, Asil E, Kilic M, Isgoren E, Balbay MD. Results of robotic radical prostatectomy in the hands of surgeons without previous laparoscopic radical prostatectomy experience. *Turkish Journal of Medical Sciences* 2012;42(Suppl 1):1338-1346.
- Canda AE, Atmaca AF, Altinova S, Akbulut Z, Balbay MD. Robot-assisted nerve-sparing radical cystectomy with bilateral extended pelvic lymph node dissection (PLND) and intracorporeal urinary diversion for bladder cancer: initial experience in 27 cases. *BJU Int.* 2012 Aug;110(3):434-44.
- Canda AE, Atmaca AF, Balbay MD. Robotic pyeloplasty: Step by step surgical technique. *J Adv Robot Automat* 2013;2:1-5.
- Canda AE, Atmaca AF. Robotic zero ischemia partial nephrectomy: Step by step surgical technique with tips and tricks. *Robotic surgery: Research and reviews* 2014;1:1-9.
- McDougall EM, Corica FA, Chou DS, Abdelshehid CS, Uribe CA, Stoliar G, Sala LG, Khonsari SS, Eichel L, Boker JR, Ahlering TE, Clayman RV. Short-term impact of a robot-assisted laparoscopic prostatectomy 'mini-residency' experience on postgraduate urologists' practice patterns. *Int J Med Robot.* 2006 Mar;2(1):70-4.
- Patel VR. Essential elements to the establishment and design of a successful robotic surgery programme. *Int J Med Robot.* 2006 Mar;2(1):28-35.
- Seymour NE, Gallagher AG, Roman SA, O'Brien MK, Bansal VK, Andersen DK, Satava RM. Virtual reality training improves operating room performance: results of a randomized, double-blinded study. *Ann Surg.* 2002 Oct;236(4):458-63; discussion 463-4.
- Fried GM, Feldman LS, Vassiliou MC, Fraser SA, Stanbridge D, Ghitulescu G, Andrew CG. Proving the value of simulation in laparoscopic surgery. *Ann Surg.* 2004 Sep;240(3):518-25; discussion 525-8.
- Laguna MP, Arce-Alcazar A, Mochtar CA, Van Velthoven R, Peltier A, de la Rosette JJ. Construct validity of the chicken model in the simulation of laparoscopic radical prostatectomy suture. *J Endourol.* 2006 Jan;20(1):69-73.
- Judkins TN, Oleynikov D, Stergiou N. Objective evaluation of expert and novice performance during robotic surgical training tasks. *Surg Endosc.* 2009 Mar;23(3):590-7.

- Sun LW, Van Meer F, Schmid J, Bailly Y, Thakre AA, Yeung CK. Advanced da Vinci Surgical System simulator for surgeon training and operation planning. *Int J Med Robot.* 2007 Sep;3(3):245-51.
- Chitwood WR Jr, Nifong LW, Chapman WH, Felger JE, Bailey BM, Ballint T, Mendleson KG, Kim VB, Young JA, Albrecht RA. Robotic surgical training in an academic institution. *Ann Surg.* 2001 Oct;234(4):475-84; discussion 484-6.
- Shim JH, Kim JG, Jeon HM, Park CH, Song KY. The robotic third arm as a competent analog of an assisting surgeon in radical gastrectomy: impact on short-term clinical outcomes. *J Laparoendosc Adv Surg Tech A.* 2013 May;23(5):447-51.
- Mirheydar H, Jones M, Koeneman KS, Sweet RM. Robotic surgical education: a collaborative approach to training postgraduate urologists and endourology fellows. *JSLs.* 2009 Jul-Sep;13(3):287-92.
- Rashid HH, Leung YY, Rashid MJ, Oleyourryk G, Valvo JR, Eichel L. Robotic surgical education: a systematic approach to training urology residents to perform robotic-assisted laparoscopic radical prostatectomy. *Urology.* 2006 Jul;68(1):75-9.
- Samadi D, Levinson A, Hakimi A, Shabsigh R, Benson MC. From proficiency to expert, when does the learning curve for robotic-assisted prostatectomies plateau? The Columbia University experience. *World J Urol.* 2007 Mar;25(1):105-10.
- Schroeck FR, de Sousa CA, Kalman RA, Kalia MS, Pierre SA, Haleblan GE, Sun L, Moul JW, Albala DM. Trainees do not negatively impact the institutional learning curve for robotic prostatectomy as characterized by operative time, estimated blood loss, and positive surgical margin rate. *Urology.* 2008 Apr;71(4):597-601.
- Guzzo TJ, Gonzalgo ML. Robotic surgical training of the urologic oncologist. *Urol Oncol.* 2009 Mar-Apr;27(2):214-7.
- Jamshidi R, LaMasters T, Eisenberg D, Duh QY, Curet M. Video self-assessment augments development of videoscopic suturing skill. *J Am Coll Surg.* 2009 Nov;209(5):622-5.
- Giedelman CA, Abdul-Muhsin H, Schatloff O, Palmer K, Lee L, Sanchez-Salas R, Cathelineau X, Dávila H, Cavelier L, Rueda M, Patel V. The impact of robotic surgery in urology. *Actas Urol Esp.* 2013 Nov-Dec;37(10):652-7.
- Zorn KC, Orvieto MA, Gong EM, Mikhail AA, Gofrit ON, Zagaja GP, Shalhav AL. Robotic radical prostatectomy learning curve of a fellowship-trained laparoscopic surgeon. *J Endourol.* 2007 Apr;21(4):441-7.
- Ou YC, Yang CR, Wang J, Cheng CL, Patel VR. Robotic-assisted laparoscopic radical prostatectomy: learning curve of first 100 cases. *Int J Urol.* 2010 Jul;17(7):635-40.
- Canda AE, Balbay MD. Tasks of the assistant surgeon during robotic assisted radical prostatectomy (RARP). 2nd Ankara Robotic Urology Symposium & Course Book, Canda AE (ed); (ISBN: 978-605-85925-0-6) 2013;24-27.
- Canda AE, Akbulut Z, Atmaca AF, Altinova S, Balbay MD. Surgical Technique: Robotic-assisted laparoscopic radical prostatectomy (RARP). 2nd Ankara Robotic Urology Symposium & Course Book, Canda AE (ed); (ISBN: 978-605-85925-0-6) 2013; 58-65.