

# Journal of Pediatric Sciences

## Conservative management in infectious mononucleosis related spontaneous splenic rupture

*Gülşen Ekingen, Bülent Azman, Burak Erkuş, B. Haluk Güvenç*

Journal of Pediatric Sciences 2010;2:e10

### How to cite this article:

**Ekingen G., Azman B., Erkuş B., Güvenç BH. Conservative management in infectious mononucleosis related spontaneous splenic rupture. Journal of Pediatric Sciences. 2010;2:e10**

## CASE REPORT

## Conservative management in infectious mononucleosis related spontaneous splenic rupture

*Gülşen Ekingen<sup>1</sup>, Bülent Azman<sup>1</sup>, Burak Erkuş<sup>1</sup>, B. Haluk Güvenç<sup>1</sup>*

**Abstract:**

Spontaneous splenic rupture is a rare but potential lethal complication of infectious mononucleosis. Although splenectomy is still the treatment of choice for patients with spontaneous splenic rupture, non-surgical management should be considered in carefully selected patients. We describe the case of a 16-year-old girl with infectious mononucleosis and who had splenic rupture and who was treated by non-operative approach.

**Keywords:** Infectious mononucleosis, complication, spontaneous splenic rupture  
nonoperative treatment

**Received:** 25/02/2010; **Accepted:** 31/03/2010

### Introduction

Infectious mononucleosis (IM) is a common self-limited viral illness caused by Epstein-Barr virus (EBV) and transmitted primarily through exchange of saliva [1-3]. Splenomegaly is noted clinically in half of the affected patients. Apart from a more common benign course, approximately 0.1-0.7% of the cases are reported to present with spontaneous splenic rupture [1, 3, 4]. Abdominal tenderness and tachycardia are unusual signs in uncomplicated IM and should alert the physician to the possibility of spontaneous splenic rupture, the most serious and life-threatening complication of this clinical entity. Splenectomy has long been the choice of treatment until recent trends in management of traumatic splenic rupture favored nonoperative

*Gülşen Ekingen<sup>1</sup>, Bülent Azman<sup>1</sup>,  
Burak Erkuş<sup>1</sup>, B. Haluk Güvenç<sup>1</sup>*

<sup>1</sup>Kocaeli University, Faculty of Medicine, Department of Pediatric Surgery, Kocaeli, Turkey

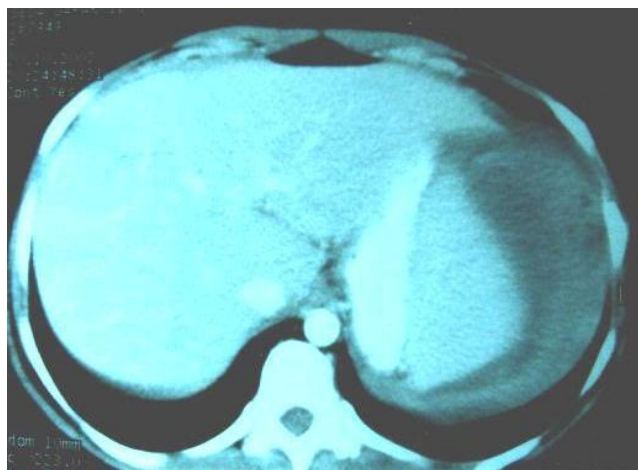
**Corresponding Author: B. Haluk Güvenç, MD**  
Hisar Intercontinental Hospital, İstanbul, Turkey  
e-mail: guvench@superonline.com

treatment in selected patients. There is, however, considerable debate over the reliable outcome of the nonoperative treatment in a diseased spleen [1]. Considering the immunological importance of spleen in pediatric patients, necessity of this

conservative approach is vital, especially for pre-adolescent children and young adults who are primarily prone to become infected with EBV [3-5]. The present study adds one more case treated by nonoperative management to those already described in the literature.

### Case Report

A 16-year-old girl presented with acute onset of severe abdominal tenderness and pain in her left shoulder. She had recently developed fever to 40°C, nausea, and vomiting after 10 days history of flu-like symptoms. There was no history of trauma. Physical examination on admission revealed pharyngitis, bilateral cervical lymphadenopathy, splenomegaly with abdominal tenderness and voluntary guarding in the left upper quadrant. Abdominal computed tomography (CT) scan showed subcapsular splenic hematoma with free fluid resembling hemoperitoneum around the spleen, in the left paracolic space and the pelvis (Fig 1).



**Figure 1:** CT scan shows subcapsular hematoma and free perisplenic fluid

She was slightly hypotensive with a blood pressure of 100/65 mmHg, and tachycardic with a heart rate of 115 beats per minute. The patient was admitted to the pediatric intensive care unit

for observation. Laboratory evaluation on admission revealed a hemoglobin level of 9.7 g/dl, and a white blood cell count of 19.307/ $\mu$ L with 30% atypical lymphocytes. The diagnosis was spontaneous splenic rupture due to infectious mononucleosis, which was confirmed by positive Monospot test and Epstein-Barr virus immunoglobulins G and M titers results. The patient was treated initially with one unit of packed red blood cells due to hemodynamic instability. Her vital signs and laboratory tests returned to normal limits after transfusion, obviating any further surgical intervention.

She was additionally administered an antipneumococcal vaccine. The patient remained hemodynamically stable but developed mild left pleural effusion, which showed spontaneous resolution during subsequent chest radiographs for the remainder of her hospital stay. She was discharged after 10 days to remain in bed rest at home. CT scan follow-up at three weeks disclosed residual architectural distortion of the spleen and a resolving subcapsular hematoma with complete resolution of the pleural effusion. She was allowed to attend her school but was cautioned against living an active life with sports activities for at least three months.

### Discussion

Approximately 50% of preadolescents and young adults are infected with the EBV, resulting an illness known as the infectious mononucleosis (IM). The determination of heterophyl antibodies and the existence of atypical lymphocytes in blood are cornerstones in the diagnosis [2, 3]. IM mostly develops a subclinical progress, presenting with a triad of fever, pharyngitis and lymphadenomegaly [1- 4]. The clinical picture may additionally present

with hemolytic anemia, thrombocytopenia, encephalitis, Guillian Barre syndrome and hepatitis [1, 6]. Various complications related to pulmonary, cardiovascular, gastrointestinal, and neurological and immune system may develop in up to 5% of the effected cases [1, 4]. IM is reported as the most common infectious disease to result in spontaneous splenic rupture, a rare but potentially lethal complication [7].

The reported incidence of IM related spontaneous splenic rupture is 0.1-0.7%, besides the fact that splenomegaly is present in half of the effected patients [1, 3, 4]. An extensive search in the English literature reveals the presence of at least 74 patients with spontaneous rupture of the spleen and serologically proven IM, since King's [6] initial published report in 1941. The inclusion criteria are defined by Rutkow as: 1) no history of recent abdominal trauma, 2) hematological and serological confirmation of diagnosis of IM, 3) presence of multi-systemic disease, and 4) splenic histopathology consistent with IM [8]. Contemporary approach disregards the need for splenic histopathology because of the possibility of nonoperative treatment [3-5]. Rutkow has declared only 18 cases as "true" reports in his review of world literature, covering 107 reported cases until 1976 [8]. A recent report by Stephenson declares the presence of at least 23 reports of successful nonoperative management [5].

Splenic involvement usually occurs in 10 to 28 days after onset of clinical symptoms. In our case, subcapsular hematoma was observed ten days after the onset of disease. Previous surgical experience has contributed much in understanding the setting of the pathological process. The spleen may be enlarged to up to

three times its normal size and becomes soft, hyperemic and fleshy during the early stage of the disease. Capsular infiltration with lymphocytes and atypical lymphoid cells makes it thin and friable with an increased tendency to rupture [1, 2, 5, 7]. It is postulated that either an acute increase in portal venous pressure from a valsalva maneuver or an alternative sudden compression of the spleen from contraction of diaphragm or abdominal wall, occurring during vigorous coughing, vomiting or defecation may be responsible of rupture process [1, 4, 8]. Possible splenic rupture should be considered if the patient complains of left upper quadrant tenderness accompanying established instability in vital signs [5, 8, 9]. Almost half of the patients may also complain from pain referred to the left shoulder as in our case [5].

Splenectomy is proposed for patients who are hemodynamically instable [3, 7, 9-11]. The prognosis is favorable with prompt diagnosis and correct treatment. Surgeons, who advocate total splenectomy, prefer to do so due to possibility of sudden death in the early stage disease and the risk associated with blood transfusion [2, 7, 10, 11]. Another major concern is the risk of delayed or recurrent rupture of the diseased spleen [1]. Prolonged hospitalization and activity restriction are also regarded as disadvantages of non-surgical treatment [2, 10, 11]. Even though it is still unclear how accurately radiologic healing equates with physiologic healing, authors recommend an initial US study within 2 weeks after discharge, repeated at 3 and 6 months or until normal splenic architecture is documented.

Recent numerous reports document successful non-operative management of subcapsular hematoma with a favorable outcome in hemodynamically stable patients with IM [4, 5,

9, 10]. Stephenson suggests nonoperative management as appropriate to undertake in the hemodynamically stable patient who requires less than 4 units of blood for resuscitation [5]. Schwarz et al demonstrated successful evacuation of the hematoma using a pigtail catheter inserted under ultrasonographic guidance. This procedure aided the patient's recovery without compromising the splenic parenchyma [4]. Conservative approach is especially advocated in the pediatric age because of significant risk of post-splenectomy sepsis. The incidence of post-splenectomy sepsis is given as 0.58 to 0.86% bearing a mortality rate of 50 to 80% [3]. Nonoperative management additionally saves the patient from risks related to laparotomy such as iatrogenic injuries, pancreatitis, pulmonary embolism, pneumonia, brid ileus and higher rates of wound infection. Our case developed a mild pleural effusion, which resolved spontaneously. The advent of endovascular interventional modalities has recently introduced splenic artery embolization with successful results, as an additional alternative conservative approach [12, 13]. We have treated numerous trauma cases of spleen and liver laceration with selective arterial embolization when indicated. A nonoperative approach was preferred as the choice of treatment in our patient, since she was hemodynamically stabilized following single pack of blood transfusion and her symptoms subsided, the need for splenic artery embolization was regarded unnecessary.

We advocate conservative approach whenever appropriate to avoid complications of splenectomy and the risk of post-splenectomy sepsis in selected cases. It is best to follow the patients in a pediatric surgical ward in an ICU setting. The duration of activity limitation after

discharge is dependent on the symptoms of the underlying disease and findings seen on radiologic evaluation.

### References

1. Asgari MM, Begos DG. Spontaneous splenic rupture in infectious mononucleosis: a review. *Yale J Biol Med* 1997; 70: 175 -182
2. Bailey RE. Diagnosis and treatment of infectious mononucleosis. *Am Fam Physician* 1994; 49: 879-988.
3. Rothwell S, McAuley D. Spontaneous splenic rupture in infectious mononucleosis. *Emergency Med (Fremantle)*. 2001; 13: 364-36
4. Schwarz M, Zaidenstein L, Freud E et al. Spontaneous splenic rupture in infectious mononucleosis: conservative management with gradual percutaneous drainage of a subcapsular hematoma. *Pediatr Surg Int* 1999; 15: 139-140.
5. Stephenson JT, DuBois JJ. Nonoperative management of spontaneous splenic rupture in infectious mononucleosis: A case report and review of the literature. *Pediatrics* 2007; 120: e432-e435.
6. King R. Spontaneous rupture of the spleen in infectious mononucleosis. *N Engl J Med* 1941; 224: 1058-1060
7. Kuzman I, Kirac P, Kuzman T, et al. Spontaneous rupture of the spleen in infectious mononucleosis: case report and review of the literature *Acta Med Croatica* 2003; 57: 141-143
8. Rutkow IM. Rupture of the spleen in infectious mononucleosis: a critical review. *Arch Surg* 1978; 113: 718-720

9. Birkinshaw R, Saab M, Gray A. Spontaneous splenic rupture: an unusual cause of hypovolemia. *J Accid Emerg Med* 1996; 13: 289-291.
10. Gordon MK, Rietveld JA, Frizelle FA. The management of splenic rupture in infectious mononucleosis. *Aust NZJ Surg* 1995; 65: 247-250
11. Safran D, Bloom GP. Spontaneous splenic rupture following infectious mononucleosis. *Am Surg.* 1990;56: 601-5.
12. Brichkov I, Cummings L, Fazylov R, Horovitz JH. Nonoperative management of spontaneous splenic rupture in infectious mononucleosis: the role for emerging diagnostic and treatment modalities. *Am Surg.* 2006; 72: 401-4
13. Sweat JA, Dort JM, Smith RS. Splenic embolization for splenic laceration in a patient with mononucleosis. *Am Surg.* 2008; 74: 149-51