

Journal of Pediatric Sciences

Two children with non-iatrogenic traumatic isolated tracheal ruptures

*Maruf Sanli, Ersin Arslan, Ahmet Feridun Isik,
Bulent Tuncozgun, Levent Elbeyli*

Journal of Pediatric Sciences 2010;2(2):e20

How to cite this article:

Sanli M., Arslan E., Isik A.F., Tuncozgun B., Elbeyli L. Two children with non-iatrogenic traumatic isolated tracheal ruptures. Journal of Pediatric Sciences. 2010;2(2):e20

CASE REPORT

Two children with non-iatrogenic traumatic isolated tracheal ruptures

Maruf Sanli¹, Ersin Arslan¹, Ahmet Feridun Isik¹,
Bulent Tuncozgun¹, Levent Elbeyli¹

Abstract:

Aims: By presenting two cases of isolated tracheal rupture, we aimed to discuss the alternative management approaches in this pathology.

Case Report: We had two cases of tracheal rupture. One of the cases had a penetrating trauma caused by a dog bite and a blunt trauma by a bicycle accident was the reason of the tracheal rupture in our second case. We obtained a favorable result by choosing a surgical repair in our patient with a penetrating trauma. The second case was treated conservatively.

Conclusion: The cases with a tracheal rupture should be evaluated on an individual basis. The treatment options are surgery or a conservative approach depending on the patient's condition.

Keywords: trauma, tracheal rupture, child

Received: 06/05/2010; **Accepted:** 07/06/2010

Introduction

Tracheal ruptures (TR) are caused by blunt trauma, penetrating trauma and iatrogenic injuries. TR following a blunt trauma is seen in less than %1 of all adult cases [1]. This percentage is even lower in children [2]. Despite being rare in occurrence, tracheal ruptures are dramatic injuries when seen in children; they can be life-threatening and can lead to death. Delays in their diagnosis and treatment result in acute or delayed complications [3,4]. Choices of treatment might change based on the type, the localization and the size of the injury concerned, as well as the presence of co-morbid pathologies [3]. In our department, we had two cases of

Maruf Sanli¹, Ersin Arslan¹, Ahmet Feridun Isik¹,
Bulent Tuncozgun¹, Levent Elbeyli¹

¹Gaziantep University, Medical School, Thoracic
Surgery Department

Corresponding Author:
Maruf Sanli, MD

¹Gaziantep University, Medical School, Thoracic
Surgery Department, 27310-Şehitkamil / Gaziantep /
Turkey

Tel: +905057618601

Fax: +903423606729

e-mail: sanli@gantep.edu.tr

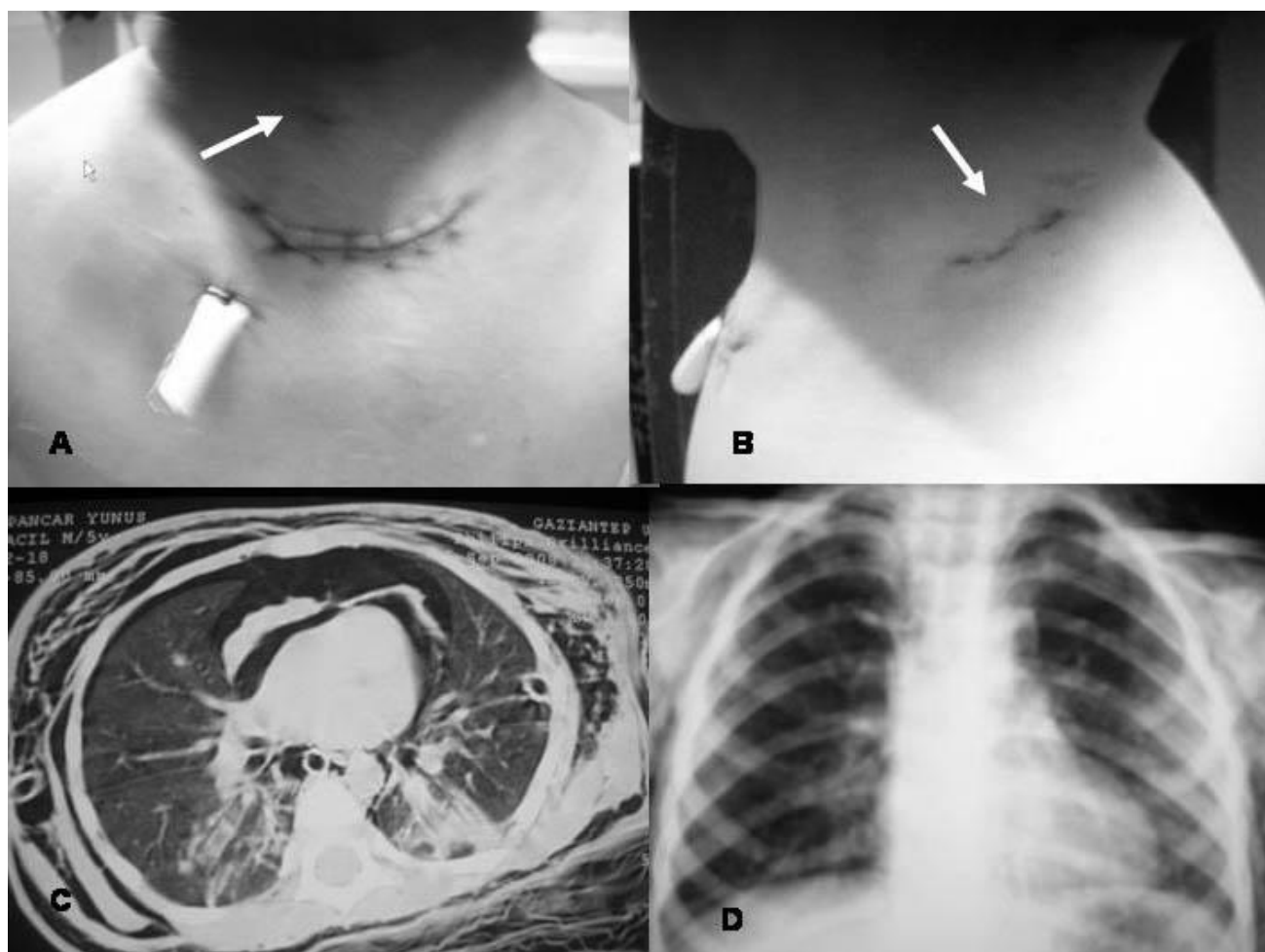


Figure 1. The marks of a dog-bite can be identified on the anterior and lateral aspects of the neck respectively (A, B). Thoracic CT revealed mediastinal emphysema together with bilateral chest tubes (C). No problems were identified in the control visit at postoperative 3 months (D).

tracheal rupture; one was due to a penetrating trauma caused by dog bite and the other was due to a blunt one caused by a fall from a bicycle. By presenting these two cases of isolated tracheal ruptures, we aimed at discussing the available treatment alternatives together with their results.

Case 1:

A 5-year-old boy was referred to our department from another center after being bitten by a dog. The patient arrived six hours after the accident; he had already been intubated, bilateral tube thoracostomy had been placed and he had a transverse incision of 2 cm encompassing the

skin and subcutaneous tissues located approximately 1.5 cm above the jugulum. On the upper half of his body, he had widespread subdermal emphysema that included the eyelids; there were marks of the teeth of the dog on his neck. (Figure 1A, 1B).

Upon admission, his pulse rate was 139/min and his blood pressure was 119/65 mmHg. When blood gases were measured, pO₂ was 142.1 mmHg, pCO₂ was 31.3 mmHg, pH was 7.39, SO₂ was %98.1 and BE was -5.0. Computerized tomography (CT) of the thorax was reported as widespread subcutaneous emphysema, collapsed

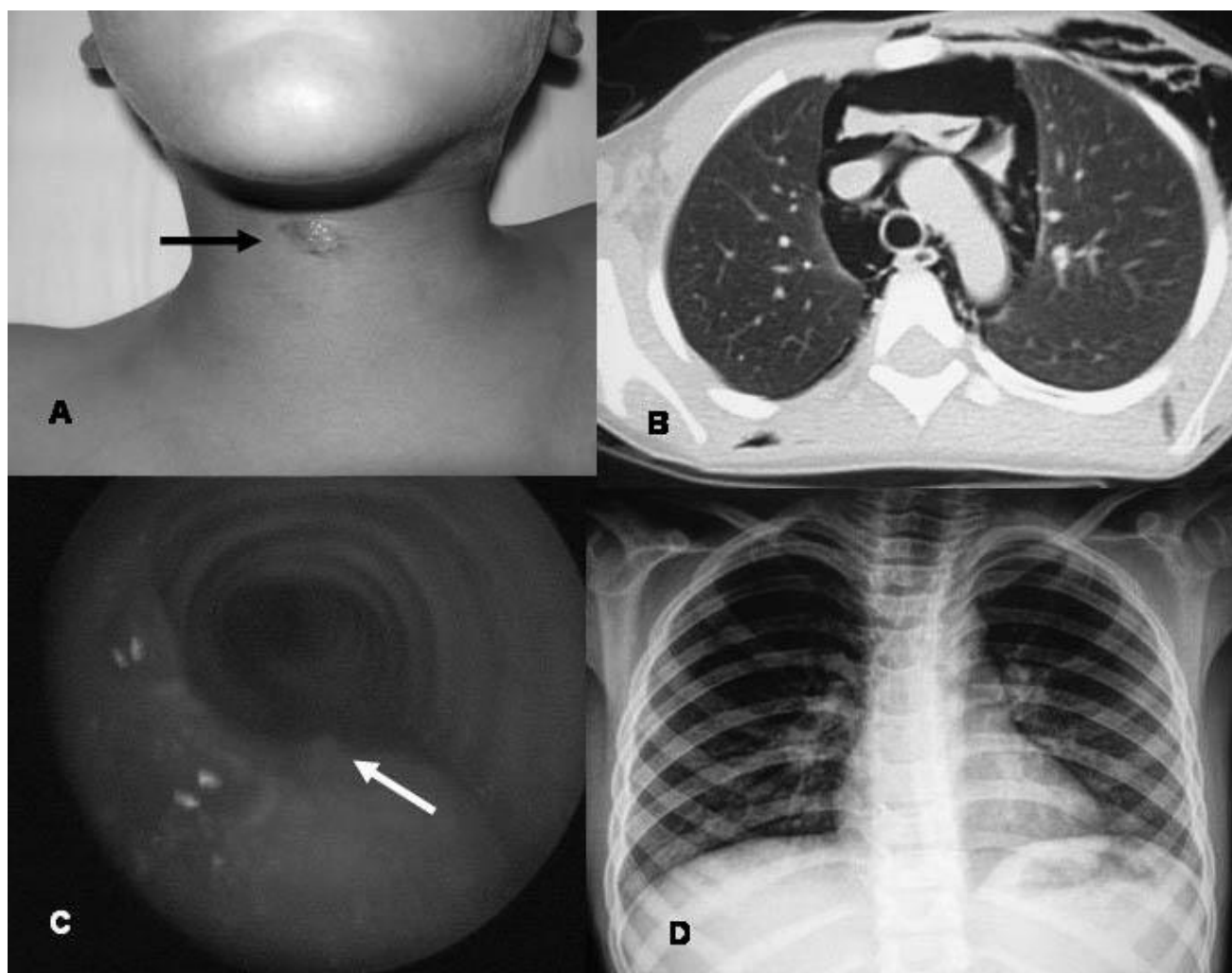


Figure 2: Ecchymosis on the neck caused by a bicycle accident (A) widespread subcutaneous emphysema and pneumomediastinum were observed on thoracic CT (B). The case was observed to be free of problems during bronchoscopic (C) and radiological (D) controls.

fields in lungs, pneumomediastinum and the presence of tube thoracostomies in both hemithoraces (Figure 1C).

The patient was transferred to the operation room. Rigid bronchoscopy was performed under general anesthesia. A 0° pediatric telescope was introduced through the bronchoscope, the bleeding field on the trachea was observed as 3 cartilage rings away from the vocal cords and the transverse cut was between 5-12 o'clock.

A decision was made to perform surgery. The incision previously performed above the

jugulum was enlarged from both sides to come up with a collar incision. Cervical trachea was explored. A transverse cut of 1cm was identified on the right side of the trachea located between 8-12 o'clock. By preserving the recurrent nerve, the cut was primarily repaired with 2 interrupted 3/0 absorbable sutures (Vicryl, Ethicon). A plastic drain was placed underneath the pretracheal fascia. Air leakage check was performed. Anastomosis line was not covered with any other structure. Bronchoscopy was performed for anastomosis control during the intraoperative period. Anastomosis field was

devoid of any problems. As the lungs had expanded bilaterally, chest tubes were removed the day after the surgery. The patient was discharged in good health on the 4th postoperative day. The patient had an uneventful course during the three months of follow-up (Figure 1D). In his bronchoscopic evaluation at 3 months, the anastomotic region was patent.

Case 2:

A 5-year-old boy, who had fallen from the bicycle 24-hours prior to admitting to our clinic, was examined in the emergency room. In his preliminary evaluation, he had a 2 cm echimotic area on the anterior side of the neck and subcutaneous emphysema extending up to the eyelids bilaterally (Figure 2A). At the time of admission, his pulse rate was 128/min, his blood pressure was 124/68 mmHg. In the measurement of blood gases, pO₂ was 109.4 mmHg, pCO₂ was 32.7 mmHg, pH was 7.43, SO₂ was %98.1 and finally BE was -2.0. In the cervical and thoracic computerized tomography examinations, widespread subcutaneous emphysema and pneumomediastinum were observed (Figure 2B). The patient was transferred to the operation room. Rigid bronchoscopy was performed under general anesthesia. With a 0° pediatric telescope introduced via the bronchoscope, the area of the cut was identified as 4 cartilaginous rings away from the vocal cords, on the membranous wall of the trachea; it was approximately 2 cm in length, was longitudinal and did not include all the layers of the trachea. The decision was that of a conservative treatment.

Wide-spectrum antibiotherapy and analgesics were administered. Daily body temperature checks complete blood count, erythrocyte sedimentation rate measurements were made and subcutaneous emphysema was also checked daily. On the sixth day of his hospitalization, the patient was free of fever and his emphysema had improved; therefore he was discharged. The patient came for a control visit ten days later.

Subcutaneous emphysema had disappeared completely and in the control rigid bronchoscopy, the defect on the membranous wall was found to have healed nearly to the full (Figures 2C, 2D).

Discussion

A tracheobronchial injury should be suspected in every patient experiencing high-energy thoracic trauma. Even “smaller forces” can result in ruptures in the membranous portion of the trachea as it is its weakest region [5]. In the blunt trauma caused by a fall from a bicycle, the rupture was on the membranous portion having a longitudinal projection. In both of our cases, the ruptures were at the level of the cervical trachea. The symptoms and signs of tracheal rupture generally present themselves as difficulty in breathing, subcutaneous emphysema, hemoptysis, pneumomediastinum, pneumothorax and hemothorax [3]. In patients with TR, coexisting pathologies might create difficulties in diagnosis. In TR, increased pressure as caused by the pneumomediastinum can result in pneumothorax by detaching the mediastinal pleura. In our first case, the presence of subcutaneous emphysema might have worsened the appearance of the patient; with the consideration that the pathology might originate from the lungs, the physician at the initial admission site might have attempted an unnecessary tube thoracostomy. The day following the hospitalization of the patient in our clinic; the absence of any air drainage and the total expansion of both lungs during the radiological evaluation resulted in the removal of the chest tubes. Clinical suspicion is important in the diagnosis together with clinical and radiological evaluation. In suspected cases, early bronchoscopic evaluation results in high levels of efficiency [1,3]. Bronchoscopy provides us exact information about the localization and projection of the rupture while identifying the treatment approach. In the first case, the presence of a dog bite, the identification of the

teeth marks upon physical examination and in the second case the presence of an echimotic region on the neck secondary to the trauma and the widespread subcutaneous emphysema aroused the suspicion for TR. The suspicion for tracheal rupture was confirmed with the bronchoscopy performed in the operation room. Surgical approach is cited as the treatment of choice in the literature focusing on tracheobronchial injuries [3, 4]. Although Gabor et al. [3] stated that conservative approach can be possible by maintaining an appropriate cuff position in injuries of smaller than 2 cm not including all layers of the tracheobronchial wall, most of their cases were treated surgically.

In TR surgery, the location of the injury is important in the selection of the approach. While collar incision is preferred for cervical tracheal injuries, right posterolateral incision from the 4th or the 5th intercostal spaces is preferred for injuries of the distal trachea, carina and both main bronchi [3, 4]. In our first case, there was a prior cervical skin-subcutaneous incision performed with the aim of alleviating the subcutaneous emphysema caused by the tracheal injury. We enlarged this incision on both sides in our attempt to reach the site of the injury. In surgery, primary end-to-end anastomosis should be preferred [3]. However, based on the size and the shape of the injury, plastic procedures could also be attempted. The principles of successful bronchoplastic techniques can be delineated as clean transection lines, minimal handling of the mucosa, avoidance of devascularization, and precise placement of sutures [6]. We obtained favorable results by choosing plastic repair in our first case. During the repair, we used absorbable suture material as recommended by Grillo [7].

There are reports stating that conservative approach can result in success in the treatment of TR. Carbognani and colleagues [8] commented that in TR, conservative treatment should be attempted on stable patients with small (lesser

than 2 cm in length) and uncomplicated ruptures, while Jougon et al [9] said that it can be used for ruptures smaller than 4 cm. Gomez-Caro and colleagues [10] had a series of 33 patients with tracheobronchial ruptures; they concluded that membranous ruptures could more often be treated conservatively, whereas cartilagenous ruptures, if together with major symptoms, should be treated surgically. In our second case, the location of the rupture and its size and the fact that the clinical condition of the patient remained stable despite 24 hours have elapsed after the accident, resulted in us approaching the patient conservatively. During such an approach, any deterioration to be observed in the respiration or the clinical condition of the patient should not exclude surgery. During his treatment, our patient was followed-up closely and the decision to continue with non-operative treatment was revisited every day. There was no clinical or radiological worsening in his condition, and the patient was discharged on day 6 in good health.

Delays in the diagnoses and treatment of TR cases and complicating additional injuries increase the mortality and the morbidity. In our case, we attempted in a timely manner, so no morbidity or mortality developed.

In conclusion, in trauma patients presenting with subcutaneous emphysema during the initial admission to the hospital, TR should be kept in mind while evaluating the patient clinically and radiographically. The level of the injury should be given consideration to and a detailed evaluation should be performed to identify the need for tube thoracostomy. In cases not having any clinical findings, high clinical suspicion makes early diagnosis possible. In suspected cases, bronchoscopic evaluation under conditions allowing for emergency surgery is essential in diagnosis. Mortalities can be prevented by early diagnosis and early treatment maneuvers. Delays in diagnosis and beginning of a mediastinitis can deteriorate the clinical

situation. The cases should be evaluated on individual basis for best treatment options while trying to choose between conservative treatments versus surgery.

References

1. Baumgartner F, Sheppard B, de Virgilio C, Esrig B, Harrier D, Nelson RJ, et al. Tracheal and main bronchial disruptions after blunt chest trauma: Presentation and management. *Ann Thorac Surg* 1990; 50: 569-574.
2. Gaebler C, Mueller M, Schramm W, Eckersberger F, Vecsei V. Tracheobronchial ruptures in children. *Am J Emerg Med* 1996; 14: 279-284.
3. Gabor S, Renner H, Pinter H, Sankin O, Maier A, Tomaselli F, et al. Indications for surgery in tracheobronchial ruptures. *Eur J Cardiothorac Surg* 2001; 20: 399-404.
4. Hood RM. Injury to the trachea and major bronchi. In: Hood RM, Boyd AD, Culliford AT, eds. *Thoracic trauma*. Philadelphia: W.B. Saunders Company; 1989. p. 254-266.
5. Kuhne CA, Kaiser GM, Flohe S, Beiderlinden M, Kuehl H, Stavrou GA, et al. Nonoperative management of tracheobronchial injuries in severely injured patients. *Surg Today*. 2005; 35: 518-523.
6. Prabhakaran K, Patankar JZ. Bronchoplasty for bronchial stenosis in a neonate: a case report. *J Pediatr Surg* 2004; 39: e6-8.
7. Grillo HC, Zannini P, Michelassi F. Complications of tracheal reconstruction. *J Thorac Cardiovasc Surg* 1986; 91: 322-328.
8. Carbognani P, Bobbio A, Cattelani L, Internullo E, Caporale D, Rusca M. Management of postintubation membranous tracheal rupture. *Ann Thorac Surg*. 2004; 77: 406-409.
9. Jougon J, Ballester M, Choukroun E, Dubrez J, Reboul G, Velly JF. Conservative treatment for postintubation tracheobronchial rupture. *Ann Thorac Surg*. 2000; 69: 216-220.
10. Gómez-Caro A, Ausín P, Moradiellos FJ, Díaz-Hellín V, Larrú E, Pérez JA, et al. Role of conservative medical management of tracheobronchial injuries. *J Trauma*. 2006; 61: 1426-1434.