

Journal of Pediatric Sciences

Pycnodysostosis: Clinical and Radiological Features in Two Egyptian Families

Ebtesam Mohamed Abdalla, Khaled Matrawy, Yasser Shwel

Journal of Pediatric Sciences 2012;4(2):e124

How to cite this article:

Abdalla EM, Matrawy K, Shwel Y. Pycnodysostosis: Clinical and radiological features in two Egyptian families. Journal of Pediatric Sciences. 2012;4(1):e124.

CASE REPORTS

Pycnodysostosis: Clinical and Radiological Features in Two Egyptian Families

Ebtesam Mohamed Abdalla¹, Khaled Matrawy², Yasser Shwel³

¹ Department of Human Genetics, Medical Research Institute, Alexandria University; ² Department of Radiology, Medical Research Institute, Alexandria University; ³ Department of Ear, Nose and Throat, Alexandria School of Medicine, Egypt

Abstract:

Background and Aims: Pycnodysostosis is a rare hereditary disorder, first described in 1962 by Maroteaux and Lamy. It is an autosomal recessive osteochondrodysplasia, characterized by short stature, osteosclerosis, acro-osteolysis, frequent fractures and skull deformities. Less than 200 patients have been reported worldwide since the first description of the phenotype in 1962, out of which only a few cases were reported from Egypt. The purpose of the article was to review the clinical and radiographic characteristics of pycnodysostosis based on some new Egyptian cases.

Case Report: We present two Egyptian families with cases presenting very early in life. The patients showed distinctive clinical features and, in spite of the lack of history of frequent bone fractures, they were investigated through complete skeletal survey and CT skull. The detection of dense bones and certain characteristic radiological findings finally led to the diagnosis of pycnodysostosis. The article also reports some unusual findings including conductive hearing loss, radiological findings akin to Erlenmeyer-flask deformity and lack of marked bone fragility.

Conclusion: We report here three pediatric cases affected with pycnodysostosis belonging to two Egyptian families. We describe the clinical findings, radiographic features and differential diagnosis of the studied cases. Our study strengthens the role of the radiological examination in reaching the definite diagnosis of pycnodysostosis.

Keywords: pycnodysostosis

Accepted: 08/27/2011 Published: 01/01/2012

Corresponding author. Abdalla EM, 165 El-Horreya Avenue El- Hadra Postal code 21561 - Alexandria Phone : (+203) 4285455 - 4282373- 4288233 Fax : (+203) 4283719, drebtesamabdalla@yahoo.com

Introduction: Pycnodysostosis is an uncommon autosomal recessive skeletal dysplasia with a quite distinctive clinical phenotype. The similarity in appearance of patients with pycnodysostosis regardless of age, sex, and race is striking.[1] All affected cases are characterized by short stature, osteosclerosis, acro-osteolysis of the distal phalanges, bone fragility, clavicular dysplasia, dental anomalies, obtuse angle of mandible and skull deformities

with delayed closure of fontanels and wide sutures.[2-4] The name 'pycnodysostosis' is a term coined by Maroteaux and Lamy in 1962 [5] to describe the constellation of these clinical features. It derives from the Greek (pycnos = thick or dense, dys = defective, and ostitis= bone). The disorder is also known as Toulouse-Lautrec syndrome, named for the famous French artist who was thought to be afflicted with pycnodysostosis.[6] This syndrome has been seen in

many races and nationalities, with a single medical report from Egypt.[7] The gene encoding the phenotype was mapped to human chromosome 1q21 by genetic linkage analysis,[8] and the responsible gene was later identified by a positional cloning strategy, as cathepsin K (CTSK).[9] To date, tens of different mutations, spread throughout the gene, have been reported in several unrelated pycnodysostosis families.[10] CTSK gene encodes a polypeptide of 329 amino acids, a cysteine protease that is critical for bone remodeling and resorption by osteoclasts.[11,12] Thus, cathepsin K was an excellent candidate gene for pycnodysostosis because of its genomic localization and biological properties.

Case Presentation

We present three dysmorphic cases attending the Human Genetics Department, Medical Research Institute, University of Alexandria who presented clinical and radiographic features typical of pycnodysostosis. The patients belonged to two Egyptian families; a Moslem and a Christian one. The two families presented to our clinic complaining that their children suffer from snoring, recurrent respiratory infections and slow attainment of growth. On examination, the three cases showed distinctive clinical features and, in spite of the lack of history of frequent bone fractures, they were investigated through complete skeletal survey and CT skull. The detection of dense bones and certain characteristic radiological findings finally led to the diagnosis of pycnodysostosis.

Family 1

A consanguineous couple (first-cousins) presented to our clinic complaining of short stature, episodes of sleep apnea, recurrent respiratory infections and persistent rhinorrhea in their 5-year-old daughter (Case 1). The patient was the second child of these parents who had another healthy child. Their first-born child was a male who suffered frequent respiratory infections, feeding difficulties and failure to thrive till he died at the age of 10 months. The parents claimed that this infant had facial features similar to his sister, i.e. severe micrognathia, outstanding nose and prominent eyes. The family history was otherwise unremarkable. Both parents were of normal stature. The patient was born after an uneventful pregnancy. Delivery was at term in good conditions, birth weight 3,000 g. Although the patient suffered some motor delay, her intellectual milestones were normal, and she was of normal intelligence. She had fractured her left leg at the age of four for which closed reduction was effective. Clinical findings. The patient had prominent eyes, chubby

cheeks, small mouth, microretrognathia, outstanding nose, apparently large head with marked frontal and parietal bossing and very wide open anterior and posterior fontanels (Figure 1). She also had very narrow external auditory meatus. Mal-aligned teeth and very narrow steep palate were seen (Figure 2). Examination of the hands showed normal creases, short stubby fingers with lax wrinkled overlying skin and severely hypoplastic distal phalanges with spoon shaped nails (Figure 3-A). Her toes were also short with widely-spaced big toes or 'sandal gap' (Figure 3B). Two café-au-lait spots were found on the front aspect of right thigh and left leg. The patient height was below the third percentile while the weight and circumference of the head were at 25th percentile. She had no pallor or hepatosplenomegaly.

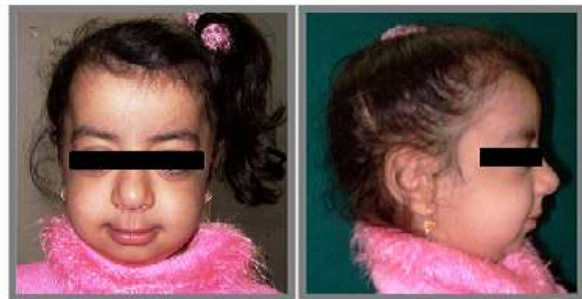

Figure 1. Photographs of case 1 showing prominent eyes, frontal and parietal bossing, outstanding nose, and a small receding chin.

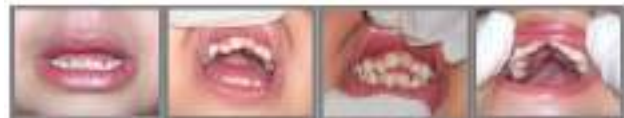

Figure 2. Photographs of case 1 mouth showing crowded teeth and narrow steep palate.

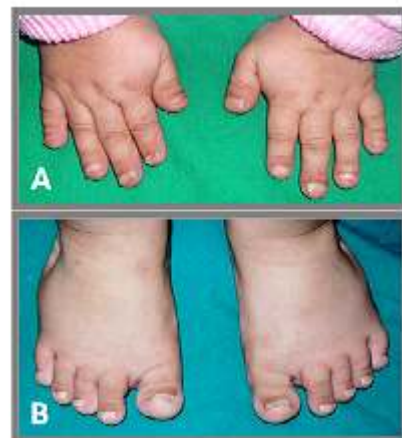

Figure 3. Case 1 hands and feet showing [A] short stubby fingers with short broad nails and wrinkled overlying skin & [B] broad feet, short toes, bulky broad big toes and sandal gap deformity.

Extensive laboratory procedures including a complete blood count and study of the renal functions and liver functions were within normal limits except for a mild microcytic hypochromic anemia. Growth hormone was assayed after stimulation and the result was within the normal range. Psychometric testing was performed and revealed an average I.Q. (96 Stanford Binet) while the audiogram showed mild conductive hearing loss. Polysomnography study revealed moderate obstructive sleep apnea and adenoidectomy was recommended. Radiologic findings (Figure 4-7). Radiographic examination demonstrated generalized increased bone density, metaphyseal flaring, thickened cortices, narrow medullary canals although the medullary canal could still be distinguished in the long bones. The roentgenogram of the skull showed open fontanel, wide separation of the sutures, sclerosis involving the base of the skull, hypoplasia of the facial bones as well as non-pneumatization and hypoplastic formation of the paranasal sinuses. The flat angle of the mandible was the outstanding feature (Figure 4-B). Three-dimensional volume rendering images demonstrated detailed anatomic and pathologic features of the skull and facial bones which are typical of pycnodysostosis (Figure 5). The middle phalanges were short and wide. The terminal phalanges were severely hypoplastic (Figure 6). The superior and inferior endplates of the vertebrae were sclerotic and the lateral view revealed anterior notching of vertebrae (Figure 7). Coxa valga was noted and the distal femoral metaphysis was broad bilaterally.

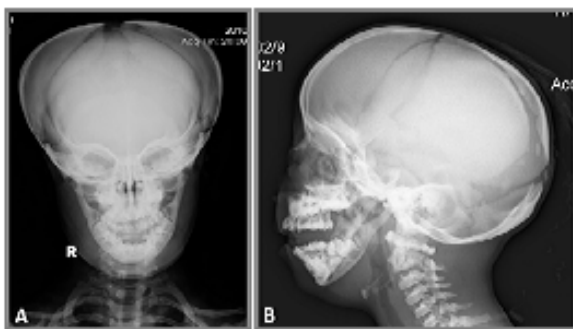

Figure 4. Case 1 skull X-ray A-P (A) and lateral (B) views. The skull is large and brachycephalic with an open anterior fontanel and separation of the cranial sutures, a wormian bone pattern is apparent in parietal bone, hypoplasia of the facial bones as well as non-pneumatization and hypoplastic formation of the paranasal sinuses. The mandibular angle is obtuse, approaching 180 degrees.

Although the presenting complaint was recurrent respiratory infections and persistent rhinorrhea, the entire clinical and radiographic picture led to the correct diagnosis of pycnodysostosis. It is obvious that the diagnosis can be made only when the examiner is familiar

with the distinctive features of this syndrome. The presence of characteristic skeletal anomalies seen in the skull, the mandible and the terminal phalanges, along with the dense bones, confirmed the diagnosis.

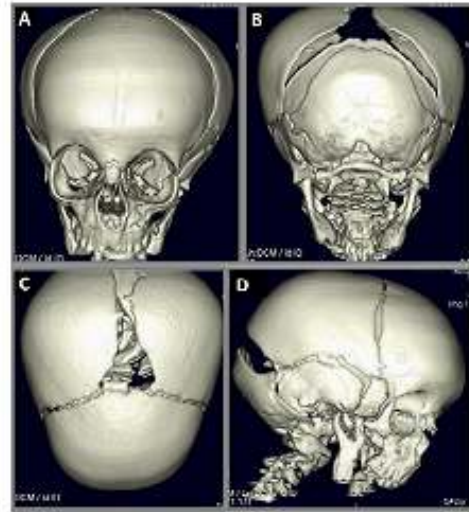


Figure 5. Three-dimensional volume rendering images of the skull of case 1 revealed (A) a large and brachycephalic skull, (B,C) open anterior fontanel and wide separation of the cranial sutures & (D) hypoplasia of the facial bones.

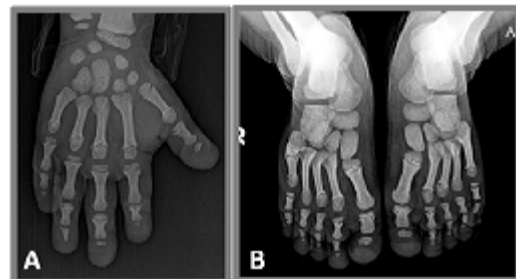


Figure 6. Radiographs of case 1 hand and (A) and foot (B) radiography of showing a variable degree of partial aplasia of the distal phalanges.

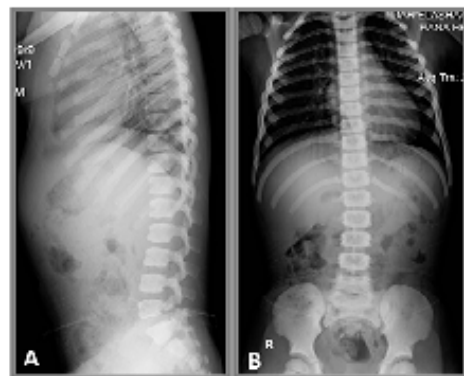


Figure 7. Case 1 spine X-rays - lateral (A) and anteroposterior (B) views - showing anterior notching of spines, spondylolisthesis L5-S1 level and sclerosis of superior and inferior end-plates of the vertebrae.

Family 2

Two male sibs; seven and four year old (case 2 & 3), were referred for evaluation of short stature and recurrent respiratory infections, snoring and an abnormal nasal tone. The patients were products of normal pregnancy and delivery. They were born with average weight at full term and their neonatal history was uneventful. Their parents were first cousins. Other siblings and parents were normal. There was no history of patients' disorder among their relatives. Both had normal developmental milestone. Parents denied any history of fractures.

Clinical findings: Physical examination of the two brothers revealed a proportionate short stature, normal intelligence and the same dysmorphic features. They both had mid-face hypoplasia with very wide proptosed eyes, prominent nose, micrognathia, frontal and bilateral parietal bossing and a very wide anterior fontanel (Figure 8). Examination of the mouth revealed a narrow high arched grooved palate and malpositioned teeth. All fingers were very short with hypoplastic terminal phalanges, wrinkled overlying skin and broad short flattened nails. The toes were also short with broad widely-spaced big toes (Figure 9).

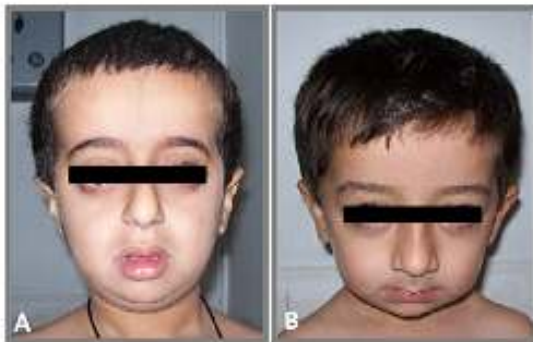

Figure 8. Photographs of case 2 [A] & case 3 [B] showing marked bilateral parietal bossing, prominent nose and micrognathia.

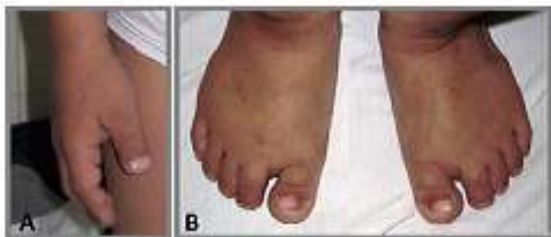

Figure 9. Case 2 right hand & feet showing: [A] brachydactyly and short thumb with a short broad flat nail & [B] short broad big toes, sandal gap deformity and short toes with very short nails.

Their heights were less than the third percentile, while the head circumferences were at the 50th percentile. There was no significant pallor or organomegaly. Growth hormone

was assayed after stimulation and the result was normal. Audiometry showed mild bilateral conductive hearing loss. The elder brother (7 years old) did well at school; had no learning difficulties. Radiologic findings (Figure 10,11): The radiologic features were similar in both sibs. The entire skeleton showed diffuse osteosclerosis and widening of the cortices of the long bones with sparing of medullary cavities. Skull X-rays showed widely separated cranial sutures, widely open fontanels, non-pneumatization of paranasal sinuses and an obtuse mandibular angle approaching 180 degrees (Figure 10). Lateral roentgenogram of the thoracic and lumbar spine showed anterior notching of the bodies of the vertebrae. The terminal phalanges of the hands and the feet were extremely hypoplastic. Radiographs of hips and lower limbs showed coxa valga and widening of the distal part of the femur, more or less similar to the Erlenmeyer-flask deformity (Figure 11).

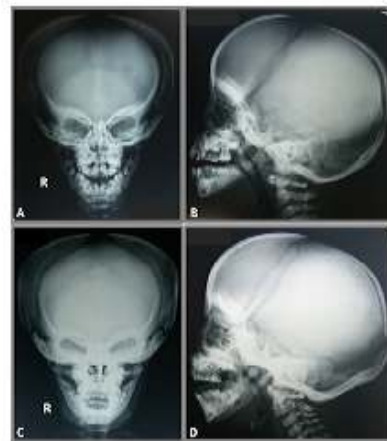

Figure 10. Radiographs of case 2 [A & B] and case 3 [C & D] skulls. Both skulls are large and brachyccephalic with open fontanels and wide separation of the cranial sutures, hypoplasia of the facial bones and absence of facial sinuses. The mandibular angle is obtuse, approaching 180 degrees. Postero-anterior skull radiography [A & C] revealing generalized osteosclerosis of the skeleton, more pronounced in the periorbital region ("maccoon mask" sign).

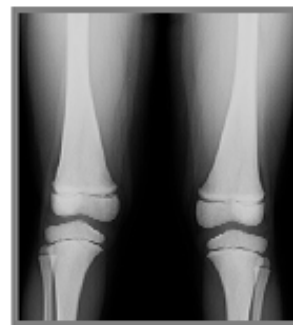

Figure 11. X-ray of the lower limbs of case 3 showing widening of the distal part of the femur; more or less similar to the Erlenmeyer-flask deformity. The medullary canals of the long bones are poorly formed but are nevertheless radiologically distinct.

While being examined and investigated for short stature, the two siblings were found to have dense bones and certain other interesting clinical features. On the basis of these characteristic clinical and radiographic features, a diagnosis of pycnodysostosis was done. Although not available in Egypt, we offered both families the option for CTSK gene mutation testing for confirmation of diagnosis, however they declined testing.

Differential diagnosis: Pycnodysostosis should be distinguished from other bone disorders [13] such as Melnick-Needles syndrome, osteopetrosis and cleidocranial dysostosis, all of which have one or more features in common. The differentiation should be primarily directed to Melnick-Needles syndrome which has a strong resemblance to pycnodysostosis both clinically and radiographically. It shares many of the clinical and some of the radiologic characteristics of pycnodysostosis (peculiar facies, malaligned teeth, delayed closure of fontanels, sclerosis of skull base, underdeveloped paranasal sinuses and acroosteolysis). However, the mode of inheritance (X-linked dominant, lethal in males) and the presence of the characteristic S-shaped appearance of tibiae, increased height of the vertebral bodies and ribbon-like ribs besides the other radiographic features of Melnick-Needles syndrome form the basis of differentiation from pycnodysostosis. Pycnodysostosis and cleidocranial dysostosis have much in common as to clinical and radiographic data. Pycnodysostosis presents a number of features characteristic of cleidocranial dysostosis, such as short stature, open cranial sutures and fontanels, a flat mandibular angle with dental abnormality and generalized osteosclerosis. However, in cleidocranial dysostosis, the bones are not that dense and there is total or partial absence of one or both clavicles; a bone not typically affected in pycnodysostosis. Cleidocranial dysostosis is transmitted by autosomal dominant inheritance whereas pycnodysostosis is an autosomal recessive disorder. Pycnodysostosis and osteopetrosis also have common features clinically and roentgenologically. The recessive type of osteopetrosis is a fatal disease in which the clinical picture is dominated by anemia, hepatosplenomegaly, very dense bones and signs of compression of the cranial nerves. Lack of anaemia and preservation of medullary canal in pycnodysostosis helps in distinguishing it from osteopetrosis.

Discussion

Pycnodysostosis is an inherited disorder of the bone remodeling [14] caused by mutations in the gene that codes the enzyme cathepsin K.[9] The characteristic

features of pycnodysostosis are the heredity nature, short stature, open cranial sutures and fontanels, hypoplastic mandible with loss of mandibular angle, frontal and parietal bossing, hypoplasia of terminal phalanges, dental anomalies and increased bone density.[1,15,16] All these findings were seen in our patients, with the widely open anterior fontanel being a prominent feature. Parental consanguinity which is recognized as a cause of this rare autosomal recessive disorder was found in the two studied families. The diagnosis of pycnodysostosis is primarily based on clinical features and radiographs; however a CTSK gene mutation analysis is the confirmatory test. Various novel mutations of cathepsin K gene in patients with pycnodysostosis have been reported in literature.[10,17] Routine laboratory investigations usually give results within normal limits. Life expectancy for a pycnodysostosis patient is normal. There is no specific treatment as of date for this disorder and treatment is supportive. Since bone fractures are a primary threat to those affected by pycnodysostosis, it is important that care is taken to prevent or minimize tendencies for a fracture to occur. Our patients showed all the characteristic clinical and radiologic features typical of pycnodysostosis except for frequent bone fractures. Bone fractures usually lead to the diagnosis of this disease and several researchers reported that bone fragility was noted in almost all cases.[1,2,18] Nevertheless, none of our three cases referred history of multiple bone fractures. Except for the distressing fractures these patients are subject to, the disease carries a good prognosis; patients with pycnodysostosis usually have normal intelligence, sexual development and life span.[18] However, pycnodysostosis could be a potentially life-threatening genetic disease due to respiratory problems in early infancy.[5] Therefore, according to the clinical history described by parents of case 1 regarding their deceased son, we assumed that he was similarly affected with the disease. Defective growth hormone secretion has been previously reported in patients with pycnodysostosis with improved linear growth after growth hormone treatment.[19] For that reason, growth hormone assay after provocation was performed for the three cases but the results were normal. Another disease feature, verified in the three studied cases, is the presence of conductive hearing loss. Although an infrequent characteristic of the disease, it has been previously reported in literature.[20] In conclusion, this study strengthens the role of the radiological examination in reaching the definite diagnosis of pycnodysostosis. We also suggest for routine examination of hearing capabilities in cases of pycnodysostosis.

Abbreviation: CTSK, Cathepsin K.

Consent: Written informed consents were obtained from the patients' parents for publication of this case report and accompanying images. A copy of the written consent is available for review by the journal's Editor-in-Chief.

Competing interests: The authors declare that they have no competing interests.

Authors' contributions: AEM performed the clinical genetic examination, analyzed and interpreted the patients' data regarding the diagnosis, and was a major contributor in writing the manuscript. MK performed and analyzed the radiological investigations, described the skeletal abnormalities and established the differential diagnosis. SYG carried out the oto-rhinological examination and interpreted the audiograms of the three patients, and performed the adenoidectomy surgery for case 1 & 2. All authors read and approved the final manuscript.

Acknowledgements: The authors wish to thank Dr. Lubna El-Desouqy (assistant lecturer, Department of Human Genetics, MRI, Alexandria University) and Dr. Heba Gharraf (assistant lecturer, Department of Chest Diseases, Alexandria School of Medicine) for their valuable help.

REFERENCES

- Fleming KW, Barest G, Sakai O. Dental and facial bone abnormalities in pycnodysostosis: CT findings. *Am J Neuroradiol.* 2007, 28:132-134.
- Elmore SM. Pycnodysostosis. *J Bone & Joint Surg.* 1967, 49:153-162.
- Clark AR. Two cases of pycnodysostosis (malady of Toulouse Lautrec). *Postgrad Med J.* 1969, 45:528.
- Edelson JG, Obad S, Geiger R, On A, Artul HJ. Pycnodysostosis: orthopaedic aspects with a description of 14 new cases. *Clin Orthop.* 1992, 280:263-276.
- Maroteaux P, Lamy M. La Pycnodysostose. *Presse Med.* 1962, 70:999-1002.
- Frey J. What dwarfed Toulouse-Lautrec? *Nature Genet.* 1995, 10:128-130.
- Soliman AT, Ramadan MA, Sherif A, Aziz Bedair ES, Rizk MM. Pycnodysostosis: clinical, radiologic, and endocrine evaluation and linear growth after growth hormone therapy. *Metabolism.* 2001, 50:905-911.
- Gleb BD, Edelson JB, Desnick RJ. Linkage of pycnodysostosis to chromosome 1q21 by homozygosity mapping. *Nature Genet.* 1995, 10:235-237.
- Gelb BD, Shi GP, Chapman HA, Desnick RJ. Pycnodysostosis, a lysosomal disease caused by cathepsin K deficiency. *Science.* 1996, 273:1236-1238.
- Donnarumma M, Regis S, Tappino B, Rosano C, Assereto S, Corsolini F, et al. Molecular analysis and characterization of nine novel CTSK mutations in twelve patients affected by pycnodysostosis. *Mutation in brief # 961.* Online. *Hum Mutat.* 2007, 28:524.
- Tezuka K, Tezuka Y, Maejima A, Sato T, Nemoto K, Kamioka H, et al. Molecular cloning of a possible cysteine proteinase predominantly expressed in osteoclasts. *J Biol Chem.* 1994, 269:1106-1109.
- Schilling AF, Mülhausen C, Lehmann W, Santer R, Schinke T, Rueger JM, et al. High bone mineral density in pycnodysostotic patients with a novel mutation in the propeptide of cathepsin K. *Osteoporosis Int.* 2007, 18:659-669.
- Soares LF, Souza IPR, Cardoso AS, Pomarico L. Pycnodysostosis: Oral findings and differential diagnosis. *J Indian Soc Pedod Prevent Dent.* 2008, Supplement S23-S25.
- Chavassieux P, Seeman E, Delmas PD. Insights into material and structural basis of bone fragility from diseases associated with fractures: how determinants of the biomechanical properties of bone are compromised by disease. *Endocr Rev.* 2007, 28:151-164.
- Helfrich MH. Osteoclast diseases and dental abnormalities. *Arch Oral Biol.* 2005, 50:115-122.
- Alves-Pereira D, Berini-Aytés L, Gay-Escoda C. Pycnodysostosis. A report of 3 clinical cases. *Med Oral Patol Oral Cir Bucal.* 2008, 13:E633-635.
- Fujita Y, Nakata K, Yasui N, Matsui Y, Kataoka E, Hiroshima K, Shiba RI, Ochi T. Novel mutations of the cathepsin K gene in patients with pycnodysostosis and their characterization. *J Clin Endocrinol Metab.* 2000, 85:425-431.
- Jones CM, Rennie JS, Blinkhorn AS. Pycnodysostosis. A review of reported dental abnormalities and a report of the dental findings in two cases. *Br Dent J.* 1988, 164:218-220.
- Soliman AT, Rajab A, AlSalmi I, Darwish A, Asfour M. Defective growth hormone secretion in children with pycnodysostosis and improved linear growth after growth hormone treatment. *Arch Dis Child.* 1996, 75: 242-244.
- Mujawar Q, Naganoor R, Patil H, Thobbi AN, Ukkali S, Malagi N. Pycnodysostosis with unusual findings: a case report. *Cases Journal.* 2009, 2:6544