

Journal of Pediatric Sciences

Unilateral Peripheral Facial Palsy Associated with Epstein - Barr virus Infection in a Child

Baris Malbora, Ugur Isik, Gokhan Aydemir, Senol Polat, Banu Kucukkirim Cibikci

Journal of Pediatric Sciences 2012;4(1):e122

How to cite this article:

Malbora B, Isik U, Aydemir G, Polat S, Kucukkirim-Cibikci B. Unilateral peripheral palsu associated with Epstein Barr virus infection in a child. Journal of Pediatric Sciences. 2012;4(1):e122

CASE REPORT

Unilateral Peripheral Facial Palsy Associated with Epstein - Barr virus Infection in a Child

Baris Malbora¹, Ugur Isik², Gokhan Aydemir¹, Senol Polat³, Banu Kucukkirim Cibikci²

¹Gulhane Military Medical Academy, Department of Pediatrics, Istanbul, Turkey, ²Acibadem University, Kozyatagi Hospital, Department of Pediatrics, Istanbul, Turkey, ³Acibadem University, Kozyatagi Hospital, Department of Otorhinolaryngology, Istanbul, Turkey

Abstract:

In pediatric patients, facial nerve palsy (FNP) is uncommon. The most common causes are infections. A 3 year-8 month-old boy presented to our hospital with left FNP and severe lymphadenopathy. When seen for the first time at our hospital, the patient had fever and left FNP, bilateral submandibular lymphadenopathy, left parotid gland enlargement, purulent tonsillopharyngeal exudate, acute otitis media, and splenomegaly. EBV PCR showed 1298 copy/mL. Acyclovir addition to steroid was initiated. Despite all these therapies a marked recovery at FNP was not observed so myringotomy was done and a ventilation tube was inserted. Further intratympanic steroid injection was done. A complete recovery is established in our patient at the 8th week of treatment. Although it is well known that FNP is generally a disease with good prognosis, in the ones due to infectious causes such as EBV, the recovery period may be prolonged despite appropriate medical and surgical treatment.

Keywords: Ebstein-Barr virus; Infectious mononucleosis; peripheral facial paralysis.

Accepted: 02/09/2012w Published: 03/01/2012

Corresponding author: Baris Malbora, MD, Cami Mahallesi, Bilgin Sokak, Safranbolu Evleri, E-Blok No:4, 34940, Tuzla, Istanbul, Turkey, Phone: +90 5336413841, Fax: +90 216 3487880, E-mail: barismalbora@gmail.com

Introduction

In pediatric patients, facial nerve palsy (FNP) is uncommon. The most common causes are infections [1]. However, in English literature, the relationship between FNP and Epstein-Barr virus (EBV) has only been rarely reported. The common clinical features of EBV infections include fever, lymphadenopathy, exudative tonsillopharyngitis and splenomegaly. However, in early childhood, most primary infections with EBV are subclinical or associated with a mild sore throat or an upper respiratory tract infection [1]. Additionally, infectious mononucleosis has been associated with neurologic complications [2]. We present here the case report of a child admitted to our hospital with acute exudative tonsillitis, peritonsillitis, left FNP (House

Brackmann, grade IV), ipsilateral acute otitis media, and intraparotid lymphadenitis, associated with EBV infection.

Case Report

A 3 year-8 month-old boy presented to our hospital with left FNP and severe lymphadenopathy. His parents noticed the onset of ‘masses’ in both sides of the neck and facial asymmetry with crying, hours before the admission. When seen for the first time at our hospital left FNP (Figure 1), bilateral submandibular lymphadenopathy (larger on left side), left parotid gland enlargement, purulent tonsillopharyngeal exudate, acute otitis media on the left, and splenomegaly.

The complete blood count showed white blood cell count of $10.3 \times 10^9/L$. Peripheral blood smear revealed lymphocytes with wide cytoplasm and intra-cytoplasmic

and intra-nuclear vacuoles (Downey cells). Neck ultrasonography showed lymph nodes within parotid glands bilaterally.

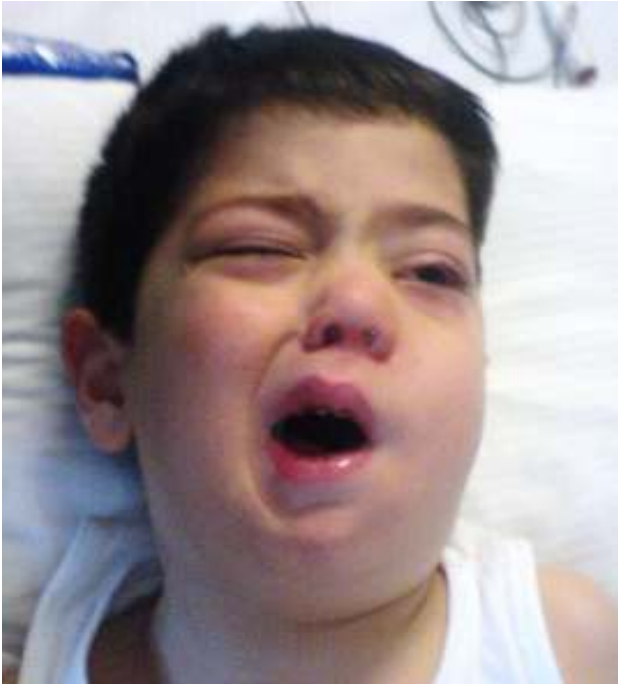

Figure 1. Left-sided facial paralysis of House-Brackmann, grade IV (Printed with permission of the patient's parents).

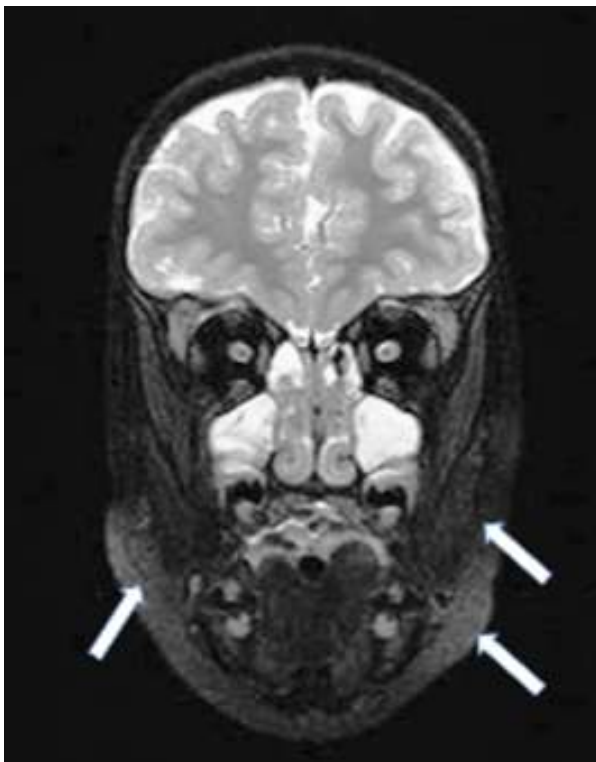


Figure 2. Cranial and cervical magnetic resonance imaging revealed multiple lymph nodes in bilateral submandibular and intraparotid areas.

On the cranial and cervical magnetic resonance imaging, infected adenotonsillary tissue that obstructed the airway almost totally and multiple lymph nodes with greatest size of 21 mm, in submandibular and parotid tissues were detected (Figure 2). No cranial abnormalities were noted. Ampicillin-sulbactam, metronidazole, and acyclovir treatment were started intravenously, in addition to oral prednisolone with a dose of 1 mg/kg/day. Throat culture showed no microorganisms. The serologic tests for EBV revealed viral capsid antigen IgM positive, IgG negative and EBV PCR showed 1298 copy/mL. Antibacterial antibiotics were stopped. At the 2nd day of admission a left myringotomy was performed and 1 mL of muco-purulent material was collected. Culture of the middle ear fluid showed no microorganisms. Two days later, myringotomy wound had recovered but the collection in the middle ear and FNP persisted so a ventilation tube was placed to the left ear with concomitant intratympanic steroid injection. The dose of steroid doubled at the fourth day of the treatment because a marked recovery of the FNP was not detected. Acyclovir treatment was continued for one week. As the patient had a slow improvement of his FNP, an EMG was ordered 2 weeks after the beginning of his symptoms and it showed moderate loss of motor unit potentials (MUP's) at the left frontalis muscle, and severe loss of MUP's at left orbicularis oculi and left orbicularis oris muscles. The patient was tapered off of oral prednisolone treatment with a slow recovery of his FNP. A complete recovery is established in our patient at the 8th week of treatment.

Discussion

Acquired FNP is an uncommon problem. Its incidence in children is even lower [3]. The etiologies of FNP in children can be classified as infectious, traumatic, malignancy-associated, hypertension-associated, and idiopathic. Among studies of FNP seen, infectious causes account for more than one third of cases [4,5]. Children with acquired FNP often have a history of preceding viral infection [6].

Infectious mononucleosis has been associated with neurologic complications. The pathogenesis of FNP with EBV infection has not been clarified. As a possible mechanism, direct viral invasion to the neurons and allergic response to EBV by the central nervous system have been suggested [1]. This case is presented due to the rare association of EBV with FNP. Treatment of FNP is both medical and surgical. Because of the high incidence of viral infection that is seen with FNP, antiviral treatment in combination with oral steroids has been considered as a possible treatment. In a recent randomized placebo controlled trial in adults comparing placebo to prednisone with or without an antiviral medication, a 40% shorter time

to recovery was seen among patients taking oral steroids. Acyclovir has been successfully used in the treatment of EBV infection [7]. In patients with FNP secondary to otitis media, myringotomy with or without tube insertion should be performed [8]. We administered wide spectrum antibiotics and acyclovir addition to steroid prior to viral serology and microbiologic cultures were taken. Clinical response was not observed so the steroid dose was increased. Despite all these therapies a marked recovery at FNP was not determined so myringotomy was done and a ventilation tube was inserted. Further intratympanic steroid injection was done.

Conclusion

Prognosis and median time to recovery from FNP vary based on the etiology of the disease [9]. A complete recovery is established in our patient at the 8th week of treatment. As a result, although FNP is well known disease generally with a good prognosis, in the ones due to infectious causes such as EBV the recovery period may be delayed despite appropriate medical and surgical treatment.

References

- 1- Terada K, Niizuma T, Kosaka Y, et al. Bilateral facial nerve palsy associated with Epstein-Barr virus infection with a review of the literature. *Scand J Infect Dis* 2004;36:75-7.
- 2- Oncel C. A rare clinical presentation of Epstein-Barr virus. *Braz J Infect Dis* 2010;14:211-2.
- 3- Rowlands S, Hooper R, Hughes R, and Burney P. The epidemiology and treatment of Bell's palsy in the UK. *Eur J Neurol* 2002; 9: 63-7.
- 4- Evans AK, Licameli G, Brietzke S, Whittemore K, Kenna M. Pediatric facial nerve paralysis: patients, management and outcomes. *Int J Pediatr Otorhinolaryngol* 2005;69:1521-8.
- 5- Grundfast KM, Guarisco JL, Thomsen JR, Koch B. Diverse etiologies of facial paralysis in children. *Int J Pediatr Otorhinolaryngol* 1990;19:223-39.
- 6- Chen WX, Wong V. Prognosis of Bell's palsy in children-analysis of 29 cases. *Brain Dev* 2005;27:504-8.
- 7- Rafailidis PI, Mavros MN, Kapaskelis A, Falagas ME. Antiviral treatment for severe EBV infections in apparently immunocompetent patients. *J Clin Virol* 2010;49:151-7.
- 8- Gaio E, Marioni G, de Filippis C, et al. Facial nerve paralysis secondary to acute otitis media in infants and children. *J Paediatr Child Health* 2004;40:483-6.
- 9- Lorch M, Teach SJ. Facial nerve palsy: Etiology and approach to diagnosis and treatment margarita. *Pediatr Emer Care* 2010; 26: 763-72.