

Journal of Pediatric Sciences

SPECIAL ISSUE

'Gastroenterology in Pediatrics: Current knowledge about some common disorders'

Editor

Makbule Eren¹, Hasan Özen²

¹Eskisehir Osmangazi University, Faculty of Medicine, Department of Pediatric Gastroenterology and Hepatology, Eskisehir, Turkey. ²Hacettepe University, Faculty of Medicine, Department of Pediatrics, Section of Gastroenterology, Hepatology and Nutrition, Ankara, Turkey

Gastrointestinal bleeding in children

Gulin Hizal, Hasan Ozen

How to cite this article:

**Hizal G, Ozen H. Gastrointestinal bleeding in children.
Journal of Pediatric Sciences 2011;3(4):e100**

Gastrointestinal bleeding in children

Gulin Hizal, Hasan Ozen

Abstract:

Gastrointestinal bleeding may be a serious problem in children because the total blood volume of a child is relatively small and blood losses from gastrointestinal tract can easily deteriorate the child. It is an uncommon but not a rare condition, and differential diagnosis is based on the age of the patient, the localization and characteristics of bleeding with accompanying symptoms. This article reviews the spectrum of gastrointestinal bleeding in children, including the etiology, diagnostic evaluation and management.

Key words: Gastrointestinal bleeding, childhood

Received: 28/03/2011; **Accepted:** 29/03/2011

A. Upper gastrointestinal bleeding

Upper gastrointestinal (UGI) bleeding is defined as the bleeding in gastrointestinal tract proximal to the ligament of Treitz. The clinical presentation of UGI bleeding is either hematemesis or melena. Hematemesis refers to vomiting bright red blood or coffee ground material which is secondary to the coagulative effect of gastric acid on blood. Melena is black, tarry stool that contains digested blood. In general, most UGI bleeding in children is benign and stops without intervention [1].

Epidemiology

There is little information about the incidence of UGI bleeding in children. It has been shown recently that the indications of upper endoscopy in children due to gastrointestinal bleeding account for 4.8% of overall endoscopy indications [2]. In the intensive care unit the incidence of UGI bleeding among children is relatively higher, ranging from 6% to 25% [3-4]. Fortunately, life threatening bleeding is rarely seen.

Etiology

The etiology of UGI bleeding in children usually varies with age. Table 1 lists the common causes of UGI bleeding according to age groups.

Gulin Hizal, Hasan Ozen

Department of Pediatrics, Division of Gastroenterology, Hepatology and Nutrition, Hacettepe University Ihsan Dogramaci Children's Hospital, Ankara, TURKEY.

Corresponding author:

Hasan Ozen, MD

Address: Department of Pediatrics, Division of Gastroenterology, Hepatology and Nutrition, Hacettepe University Ihsan Dogramaci Children's Hospital, Ankara, TURKEY.

Tel: +90 312 305 1993

Fax: +90 312 305 4157

E mail: haozen@hacettepe.edu.tr

Newborn

Hematemesis can be the sign of swallowed maternal blood in the first few days of life.

The Apt-Downey test which is based on the resistance of fetal hemoglobin to 1% sodium hydroxide can differentiate between maternal and fetal blood [5]. Hemorrhagic disease of the newborn secondary to vitamin K deficiency may

Table 1. Common causes of upper gastrointestinal bleeding in children according to age [1].

Newborn	Swallowed maternal blood Vitamin K deficiency Stress gastritis or ulcer Reflux esophagitis Coagulopathy Vascular malformations Cow's milk protein sensitivity
Infant	Stress gastritis or ulcer Esophagitis Mallory-Weiss tear Vascular malformation Gastrointestinal duplications Gastric/esophageal varices Duodenal/gastric webs Bowel obstruction
Children-adolescent	Mallory-Weiss tear Peptic ulcer Gastric/esophageal varices Caustic ingestion Vasculitis (Henoch Schönlein purpura) Crohn disease Bowel obstruction Dieulafoy lesion Hemobilia

also be the cause of hematemesis in the neonate. It is usually corrected with intramuscular or intravenous administration of vitamin K; otherwise evaluation to assess bleeding disorders should be held. Cow's milk or soy protein allergy can also present as hematemesis although bloody or mucoid stool is more frequent presentation [6]. Severe UGI bleeding may occur in critically ill neonates. The susceptibility of neonatal intestinal mucosa to injury such as ischemia results in stress gastritis or ulcers which can cause significant bleeding [7].

Infant

UGI bleeding due to stress gastritis and ulceration can be seen in critically ill infants [8]. Esophagitis due to gastroesophageal reflux disease can also cause UGI bleeding in this age group. Blood loss

is usually not significant in these conditions and is accompanied by irritability, refusal of feeding and regurgitation [1]. Vascular anomalies are uncommon cause of bleeding in infancy. Among these, hemangiomas are the most common vascular anomaly but they are rarely found in gastrointestinal tract and are usually associated with skin lesions [9]. The gastrointestinal bleeding due to hemangiomas can be significant, even requiring transfusions. Mechanical obstruction of the UGI tract and anatomical abnormalities such as duplication cysts should also be considered as the cause of UGI bleeding in infants.

Children and adolescents

Vomiting is common in children, especially due to infections. The consequence of forceful vomiting is Mallory-Weiss tear, which constitutes the most common cause of minor UGI bleeding in children. Use of nonsteroidal anti-inflammatory drugs resulting in gastric mucosal injury can cause UGI bleeding [10]. *Helicobacter pylori* infection may also result in peptic ulceration with bleeding when the ulcer erodes into the lateral wall of a vessel [11].

Upper gastrointestinal bleeding may be the initial presentation of esophageal varices and variceal bleeding is the most common cause of severe UGI hemorrhage (Figure 1). The thin-walled superficial vessels of the distal esophagus are likely to bleed under high pressure and turbulent flow. The lifelong risk of variceal bleeding is about 50% and once bleeding occurs, the risk of rebleeding is 40% [12].

Vasculitis (Henoch-Schönlein purpura), Crohn disease with UGI involvement, vascular anomalies of UGI and Munchausen syndrome by proxy are other causes of bleeding in this age group.

Approach to UGI bleeding

The evaluation of a child with gastrointestinal bleeding should begin with a brief history of the patient and a rapid assessment of physical condition. In severe gastrointestinal bleeding, patient can be hemodynamically unstable and immediate precautions to correct volume depletion and anemia should be necessary. Once

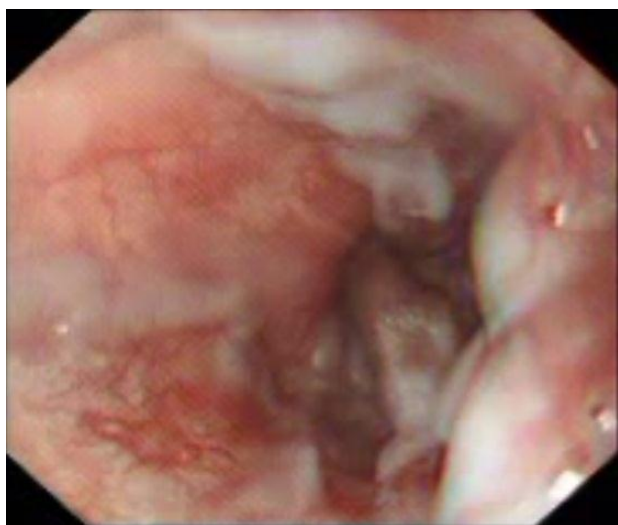

Figure 1. Esophageal varices of a 2 year-old child with biliary atresia

the child is hemodynamically stable, further evaluation can proceed. A detailed history including the duration, chronicity and recurrence of bleeding along with accompanying gastrointestinal symptoms, such as nausea, vomiting, abdominal pain and characteristic of defecation should be obtained. Use of medications such as nonsteroidal anti-inflammatory drugs that may cause mucosal injury should be questioned. The presence of an infection that causes vomiting and Mallory-Weiss tear should be investigated. The medical history of a patient with chronic disease, such as chronic liver disease with esophageal varices, is also important to determine the etiology of UGI bleeding.

In physical examination, the upper respiratory tract should be carefully examined for a bleeding lesion. Tenderness in epigastric region may be a sign of gastric or duodenal pathologies. Splenomegaly, ascites, abdominal distention may reveal a chronic liver disease resulting in esophageal varices. Skin findings, such as spider angiomas, jaundice, hemangioma, telangiectasia or purpura can also be helpful to diagnose the cause of UGI bleeding.

Initial laboratory tests include a complete blood count, prothrombin time (or international normalized ratio – INR), partial thromboplastin time and tests to assess liver function. A

nasogastric tube aspirate should be obtained during evaluation of the patient. A fresh bloody aspirate indicates active bleeding usually gastric or esophageal origin, whereas a clear aspirate does not eliminate a duodenal bleeding source.

Diagnostic studies

Radiographic studies have a limited role in UGI bleeding. An x-ray can reveal a foreign body, bowel perforation or obstruction. An abdominal ultrasonography may give information about the portal blood flow. Scintigraphy is rarely used in UGI bleeding. Angiography is helpful in diagnosis of massive UGI bleeding. Bleeding must be at least 0.5-1 ml/min to be detected by angiography [13]. It also has therapeutic advantages.

Esophagogastroduodenoscopy (EGD) is the method of choice to evaluate UGI bleeding in children. Endoscopy is generally recommended for children with acute severe hemorrhage requiring blood transfusion or with unexplained low-grade persistent or recurrent bleeding [14]. EGD can determine the source of bleeding in 90% of the cases [15]. It is especially useful in diagnosis of mucosal lesions such as gastritis, esophagitis, peptic ulcers and Mallory-Weiss tears. There are several reports regarding the endoscopic findings in UGI bleeding. Cox et al reported that the most common findings which cause bleeding were duodenal ulcer (20%), gastric ulcer (18%), esophagitis (15%), gastritis (13%), and varices (10%) [16]. Another report from China stated that duodenal ulcers dominate the cause of acute UGI bleeding [17]. EGD is contraindicated if the patient is clinically unstable, such as in shock, hypovolemia or profound anemia [15].

Treatment

The goals of treatment of the child with UGI bleeding are restoring intravascular volume and correcting anemia, locating the site of bleeding and stop and prevent recurrence of bleeding [18]. Once the patient is stable, medical and endoscopic treatment can begin.

Acid suppression is an important aspect of treatment. For mucosal bleeding, such as peptic

ulcer disease, histamine 2 (H₂) receptor antagonists or proton pump inhibitors can be used. Early empiric use of acid-suppressive medications in children with UGI bleeding is appropriate because of the predominance of acid-peptic diseases as a cause of bleeding [6]. If detected, *H. pylori* infection should be treated with antibiotics. Octreotide is a somatostatin analog which decreases splanchnic blood flow and also inhibits gastric acid secretion. It has been widely used in patients with upper gastrointestinal bleeding due to esophageal varices [19], and also shown to be effective in children with mucosal bleeding, such as bleeding from a peptic ulcer [20]. It can be administered as 1-2 mcg/kg iv bolus (maximum 50 mcg) followed by 1 mcg/kg per hour [11]. Vasopressin, a vasoactive agent which also decreases splanchnic blood flow, has been used in management of gastrointestinal bleeding but it may have severe side effects as renal failure due to decreased peripheral blood flow, thus it is no longer recommended as monotherapy [21]. Terlipressin, synthetic analog of vasopressin, is also used in management of variceal bleeding and shown to be as effective as octreotide with no significant difference regarding adverse effects [22], but there is limited data for the use of terlipressin in children with gastrointestinal bleeding.

Endoscopic therapy

A variety of endoscopic techniques are available for treatment of UGI bleeding. These include injection, coagulation/thermal therapy, laser therapy, and application of hemostatic devices or ligation devices [14]. There is little experience with most of these techniques in children with nonvariceal UGI bleeding. Among these techniques injection therapy is preferable in pediatric population. Nonvariceal injection therapy is usually performed by injection of a sclerosing agent at 3 or 4 sites around an exposed bleeding vessel. The solutions include epinephrine with normal saline, epinephrine with hypertonic saline or epinephrine followed by polidocanol (epinephrine concentration 1:10,000) [23]. The combination of injection therapy with electrocoagulation may reduce risk of bleeding and the need for transfusion more effectively than injection therapy alone [24].

Endoscopic treatment of variceal bleeding includes injection sclerotherapy or variceal banding. Injection sclerotherapy has been used in children with variceal bleeding for many years. Varices can be eradicated in approximately 90% of patients in multiple sessions with sclerotherapy [25]. Complications of sclerotherapy are esophageal strictures, ulcers and rarely esophageal perforation [26]. Variceal banding is a relatively recent application for eradication of esophageal varices. Eighty percent of varices can be ablated with endoscopic variceal banding in a median of three sessions, which is less than the required sessions to eradicate varices with sclerotherapy. Banding is also better tolerated in children with less complication [27].

Surgery

Surgical consultation should be obtained before any intervention when the risk of bleeding is high. The commonest pediatric indications for surgery are duodenal ulcer with arterial bleeding, bowel perforation, and gastroesophageal varices [14]. The need for surgery for peptic ulcer disease has decreased dramatically since the introduction of H₂ receptor antagonists, proton-pump inhibitors, and *H. pylori* therapy [28]. In patients with bleeding varices transjugular intrahepatic portosystemic shunt (TIPSS) procedure is also an alternative procedure, especially for the candidates of liver transplantation.

B. Lower gastrointestinal bleeding

Lower gastrointestinal (LGI) bleeding is defined as bleeding originating from the intestine distal to the ligament of Treitz. Hematochezia is the passage of bright red blood from rectum, either isolated or mixed with stool. It usually indicates that the origin of bleeding is colon. Massive upper gastrointestinal bleeding may also present with hematochezia due to the cathartic effect of blood through the intestine. Because many substances can mimic blood in stool, it is important to test stool to ensure that there is actually blood. Melena usually indicates bleeding above the ileocecal valve. Occult gastrointestinal bleeding is detected by testing the stool for blood, especially when the patient is investigated for iron deficiency anemia. Symptoms may be only pallor or fatigue in the case of occult bleeding.

Epidemiology

Rectal bleeding is a common complaint encountered by pediatricians. Teach et al reported that rectal bleeding constitutes 0.3% of all visits to a pediatric emergency department. Only 4% of them had life threatening conditions [29].

Etiology

As in UGI bleeding, the etiology of LGI bleeding can also vary with age. Table 2 shows the common causes of LGI according to age.

Newborn

The most important diagnosis to be excluded in a neonate with rectal bleeding is necrotizing enterocolitis (NEC). It results from loss of intestinal mucosal barrier due to ischemic damage, thus allowing the invasion of bacteria to the intestinal wall and blood stream [30]. The risk factors associated with NEC are prematurity, low birth weight, timing of initiation, composition and rate of enteral feeding, bacterial infection and intestinal ischemia [31]. The clinical presentation is systemic instability, hypothermia, apnea, lethargy with feeding intolerance, abdominal distention and bloody stools. Enterocolitis develops in 20-38% of the patients with Hirschsprung disease and can present with LGI bleeding [32].

Allergic proctocolitis usually occurs in neonates or early infancy secondary to cow's milk or soy protein hypersensitivity. It should be considered in otherwise healthy infants with blood in their stools. Cow's milk protein allergy may also occur in exclusively breastfed infants due to sensitization through breast milk containing cow's milk proteins [33].

Malrotation with midgut volvulus is most commonly seen in neonatal period. Vomiting, abdominal pain and distention, suggestive of bowel obstruction are the major symptoms. Melena can be associated with mucosal injury secondary to impaired blood flow of the intestine [34].

Infant

Anal fissure is probably the most common cause of rectal bleeding in infants and young children. It

Table 2. Common causes of lower gastrointestinal bleeding in children according to age.

Newborn	Necrotizing enterocolitis Infectious colitis Malrotation with volvulus Allergic proctocolitis Hirschsprung disease enterocolitis
Infant	Anal fissure Infectious colitis Allergic proctocolitis Intussusception Meckel's diverticulum Lymphonodular hyperplasia Malrotation with volvulus Hirschsprung disease enterocolitis Intestinal duplication
Preschool age children (2-5 years)	Anal fissure Infectious colitis Polyps Meckel's diverticulum Henoch-Schönlein purpura Hemolytic uremic syndrome Lymphonodular hyperplasia Angiodysplasia
School age children and adolescents (>5 years)	Anal fissure Infectious colitis Polyp Henoch-Schönlein purpura Inflammatory bowel disease Hemorrhoids Angiodysplasia

results from a superficial tear of the squamous lining of the anal canal and usually caused by constipation [35]. Streaks of bright red blood on the surface of stool or spots of red blood in the diaper and painful defecation are suggestive of anal fissure. It should be kept in mind that painless anal fissure can be a sign of Crohn disease.

Any infectious colitis with bacterial, viral or parasitic agents may result in LGI bleeding in any age group. Pseudomembranous enterocolitis with

Clostridium difficile toxin is usually seen during the use of antibiotics or 3-4 weeks after the cease of treatment.

Intussusception is most commonly seen before 2 years of age. It is often idiopathic or associated with lymphoid hyperplasia of the terminal ileum. Older children with intussusception should be investigated to exclude a mass lesion, such as a polyp, intestinal duplication or Meckel's diverticulum [14]. Intussusception should be considered in a previously healthy infant with episodes of colicky abdominal pain, vomiting and bloody and mucoid, so called "currant jelly stool". The presence of LGI bleeding indicates venous congestion and ischemia in the invaginated bowel segment.

Meckel's diverticulum results from incomplete obliteration of the omphalomesenteric duct. Nearly 50% of diverticula contain heterotropic gastric mucosa, and bleeding occurs due to ulceration of adjacent ileal mucosa [36]. The typical presentation of Meckel's diverticulum is painless, self-limited recurrent bleeding in an otherwise healthy child. Life-threatening massive hemorrhage can also be seen.

Preschool age children (2-5 years)

Polyps of the colon can be the cause of LGI bleeding in preschool age and older children. They usually present with isolated, recurrent and painless hematochezia and are the most frequent cause of significant LGI bleeding beyond 2 years of age [37]. Ninety five percent of polyps in children are juvenile polyps. They are hamartomatous polyps located usually in the left side of the colon with no or very low malignant potential (Figure 2). On the other hand juvenile polyposis syndrome, this is characterized by 5 or more juvenile polyps throughout the gastrointestinal tract, has an increased risk of adenomatous degeneration and malignancy [38]. Other hamartomatous polyps are found in Peutz-Jeghers, Cronkhite-Canada and Cowden syndromes. Adenomatous polyps are much less frequent in children but have clinical significance because of their malignant potential (Figure 3). They are found in familial polyposis coli, Gardner syndrome and Turcot syndrome.

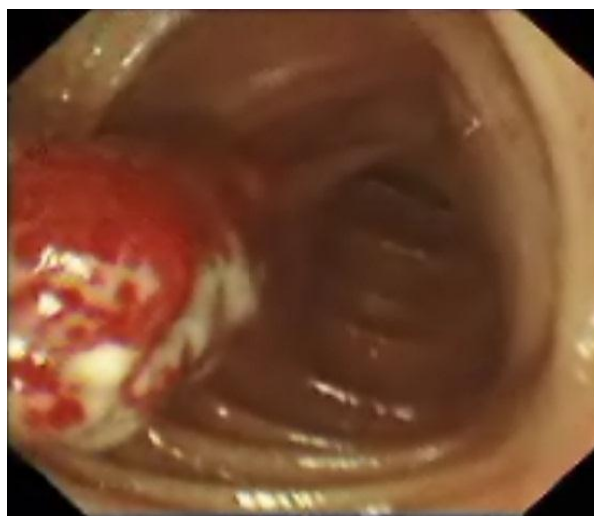


Figure 2. A juvenile hamartomatous polyp of a 14 year-old girl with rectal bleeding. The polyp was successfully removed by endoscopic polypectomy

Vasculitis, particularly Henoch-Schönlein purpura (HSP) can cause both UGI and LGI bleeding in this age group. HSP involves skin, gastrointestinal tract, joints and kidney. Gastrointestinal manifestations, including colicky abdominal pain, vomiting and bloody stools, occur in 45-75% of the cases and in 12-19% of the patients gastrointestinal symptoms precede other manifestations of HSP [39].

School age children and adolescents

Apart from the other etiologies of LGI bleeding which are common in younger children, inflammatory bowel disease is an important cause of bleeding in this age group. Approximately 25% of all new cases of inflammatory bowel diseases are diagnosed in pediatric population, and 25% of Crohn disease and 90-95% of ulcerative colitis present with rectal bleeding and/or bloody diarrhea [34].

Vascular abnormalities such as hemorrhoids, angiodysplasia, telangiectasia and hemangioma are rare causes of LGI bleeding in children of any age group.

Solitary rectal ulcer syndrome is a chronic ulcerative disease of rectum which is rarely seen in children. Symptoms include rectal bleeding,

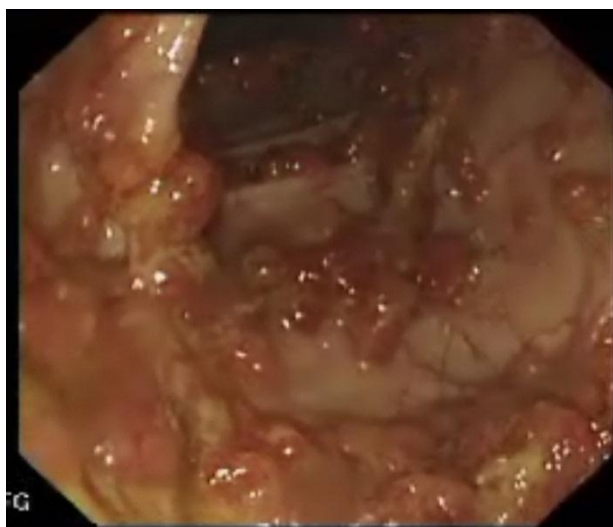

Figure 3. Multiple adenomatous polyps throughout the colon of a 10 year-old child with familial adenomatous polyposis syndrome. The patient underwent colectomy.

passage of mucus and straining on defecation, tenesmus, perineal and abdominal pain, sensation of incomplete defecation and rectal prolapse [40].

Approach to LGI bleeding

As with UGI bleeding, medical history and physical examination may be helpful for differential diagnosis. Characteristics of bleeding may help to localize the site of bleeding, so it should be carefully analyzed. Hematochezia on the outer side of the stool or found in diaper as bright red spots imply the bleeding from a rectal or anal origin. Currant jelly stools indicate vascular congestion as seen with intussusception or midgut volvulus. Bloody diarrhea usually reflects colitis. In case of melena, the site of bleeding is usually proximal to ileocecal valve. In general the darker the stool, the more proximal the site of bleeding is.

The relationship of diet with the onset of bleeding is important, as in enterocolitis due to cow's milk protein allergy. The history of travel, consumption of contaminated food or presence of other family members with acute diarrhea should remind infectious colitis. The use of antibiotics should be questioned. A family history of polyposis or inflammatory bowel disease should also be considered.

A careful examination of anus and perianal region is important, especially to diagnose an anal fissure. A skin tag in anal region or fistula may suggest Crohn disease. Digital rectal examination may reveal a rectal polyp. In case of intussusception a sausage-shaped abdominal mass can be palpated. Eczema may be associated with allergic proctocolitis. Cutaneous hemangioma or telangiectasia may suggest a similar gastrointestinal lesion. In case of Peutz-Jeghers syndrome cutaneous, oral or perioral hyperpigmentation can be found.

Initial laboratory evaluation includes a complete blood count, clotting parameters and routine chemistry. Stool evaluation for culture and Clostridium difficile toxin may be necessary in case of bloody diarrhea. A Wright stain of the stool demonstrating numerous eosinophils is highly suggestive of allergic colitis.

Diagnostic studies

Supine and upright abdominal radiographs should be performed to look for air-fluid levels, dilated bowel loops or pneumoperitoneum if there is a suspect of intestinal obstruction. Barium enema is not indicated in the initial evaluation of the patient with melena or hematochezia, but it may be necessary to confirm and also to treat intussusception. Ultrasound examination of the abdomen is helpful in acute disorders with obstruction. Intussusception can also be diagnosed with ultrasound. A radionuclide scan using technetium-99m (99mTc pertechnetate) may identify the heterotropic gastric tissue in a Meckel's diverticulum. The sensitivity of scintigraphic detection of a Meckel's diverticular bleeding site is approximately 85% and 95% [41]. 99mTc pertechnetate red blood cell scan obtained by labeling of patient's red blood cells with 99mTc pertechnetate and reinjection of them to blood stream, allows to locate the site of bleeding when the bleeding rate is 0.5 ml/min or higher [42]. Angiography can detect active bleeding at a rate of 0.5-1 ml/min and it also allows to stop bleeding by transcatheter embolization [43].

Colonoscopy is the preferred diagnostic modality for rectal bleeding. Rectosigmoidoscopy can be sufficient in infants with allergic colitis or in older

children for detection of anal fissures, hemorrhoids, polyps, colitis or inflammatory bowel diseases. If rectosigmoidoscopy fails to identify the cause of LGI bleeding, complete colonoscopy is indicated. Colonoscopy also allows obtaining biopsies, polypectomy and coagulation of bleeding site.

Wireless capsule endoscopy is the imaging method of choice in adults with obscure gastrointestinal bleeding. It has been used since 2003 in children over 10 years of age particularly to confirm the suspected Crohn disease or to identify obscure gastrointestinal bleeding [44]. It is usually a safe and tolerable procedure in adults, but a recent review about capsule endoscopy in children revealed 5.2% capsule retention in patients with known inflammatory bowel disease [45].

Treatment

Treatment should be directed at the underlying cause. Allergic colitis of infancy responds to dietary restriction immediately. Infectious colitis can be treated with proper antibiotics, and anti-inflammatory medication is used for inflammatory diseases. Surgery is most often indicated for malrotation with midgut volvulus, nonreducible intussusception, necrotizing enterocolitis or Meckel's diverticulum. Polyps are usually treated with endoscopic polypectomy. Hemorrhoids, which are mostly due to portal hypertension in children, should be treated in symptomatic patients and injection sclerotherapy can be satisfactory [46]. Several endoscopic modalities like bipolar electrocoagulation, argon plasma coagulation, and injection sclerotherapy are readily used for bleeding from angiodysplasia and other vascular anomalies in adults [43], however there is limited data in the literature about the use of these modalities in children.

REFERENCES

1. Gilger MA. Upper Gastrointestinal Bleeding. In: Walker WA, ed. *Pediatric Gastrointestinal Disease*. Philadelphia: Elsevier Churchill Livingstone; 2005:258-80.
2. Franciosi JP, Fiorino K, Ruchelli E, Shults J, Spergel J, Liacouras CA, et al. Changing indications for upper endoscopy in children during a 20-year period. *J Pediatr Gastroenterol Nutr* 2010;51:443-7.
3. Chaibou M, Tucci M, Dugas MA, Farrell CA, Proulx F, Lacroix J. Clinically significant upper gastrointestinal bleeding acquired in a pediatric intensive care unit: a prospective study. *Pediatrics* 1998;102:933-8.
4. Cochran EB, Phelps SJ, Tolley EA, Stidham GL. Prevalence of, and risk factors for, upper gastrointestinal tract bleeding in critically ill pediatric patients. *Crit Care Med* 1992;20:1519-23.
5. Apt L, Downey WS, Jr. Melena neonatorum: the swallowed blood syndrome; a simple test for the differentiation of adult and fetal hemoglobin in bloody stools. *J Pediatr* 1955;47:6-12.
6. Chawla S, Seth D, Mahajan P, Kamat D. Upper gastrointestinal bleeding in children. *Clin Pediatr (Phila)* 2007;46:16-21.
7. Kuusela AL, Maki M, Ruuska T, Laippala P. Stress-induced gastric findings in critically ill newborn infants: frequency and risk factors. *Intensive Care Med* 2000;26:1501-6.
8. Reveiz L, Guerrero-Lozano R, Camacho A, Yara L, Mosquera PA. Stress ulcer, gastritis, and gastrointestinal bleeding prophylaxis in critically ill pediatric patients: a systematic review. *Pediatr Crit Care Med* 2010;11:124-32.
9. Dubois J, Rypens F, Garel L, Yazbeck S, Therasse E, Soulez G. Pediatric gastrointestinal vascular anomalies: imaging and therapeutic issues. *Pediatr Radiol* 2007;37:566-74.
10. Grimaldi-Bensouda L, Abenhaim L, Michaud L, Mouterde O, Jonville-Bera AP, Giraudeau B, et al. Clinical features and risk factors for upper gastrointestinal bleeding in children: a case-crossover study. *Eur J Clin Pharmacol* 2010;66:831-7.
11. Boyle JT. Gastrointestinal bleeding in infants and children. *Pediatr Rev* 2008;29:39-52.

12. McKiernan PJ. Use of beta-blockers for primary prophylaxis of variceal bleeding. *J Pediatr Gastroenterol Nutr* 2000;31:93-4.
13. Racadio JM, Agha AK, Johnson ND, Warner BW. Imaging and radiological interventional techniques for gastrointestinal bleeding in children. *Semin Pediatr Surg* 1999;8:181-92.
14. Fox VL. Gastrointestinal bleeding in infancy and childhood. *Gastroenterol Clin North Am* 2000;29:37-66.
15. Gilger MA. Upper Gastrointestinal Bleeding In: Walker WA, ed. *Pediatric Gastrointestinal Disease*. Philadelphia: Elsevier Churchill Livingstone; 2005:258-80.
16. Cox K, Ament ME. Upper gastrointestinal bleeding in children and adolescents. *Pediatrics* 1979;63:408-13.
17. Houben CH, Chiu PW, Lau JY, Lee KH, Ng EK, Tam YH, et al. Duodenal ulcers dominate acute upper gastrointestinal tract bleeding in childhood: a 10-year experience from Hong Kong. *J Dig Dis* 2008;9:199-203.
18. Arora NK, Ganguly S, Mathur P, Ahuja A, Patwari A. Upper gastrointestinal bleeding: etiology and management. *Indian J Pediatr* 2002;69:155-68.
19. Corley DA, Cello JP, Adkisson W, Ko WF, Kerlikowske K. Octreotide for acute esophageal variceal bleeding: a meta-analysis. *Gastroenterology* 2001;120:946-54.
20. Eroglu Y, Emerick KM, Whitingon PF, Alonso EM. Octreotide therapy for control of acute gastrointestinal bleeding in children. *J Pediatr Gastroenterol Nutr* 2004;38:41-7.
21. Yan BM, Lee SS. Emergency management of bleeding esophageal varices: drugs, bands or sleep? *Can J Gastroenterol* 2006;20:165-70.
22. Abid S, Jafri W, Hamid S, Salih M, Azam Z, Mumtaz K, et al. Terlipressin vs. octreotide in bleeding esophageal varices as an adjuvant therapy with endoscopic band ligation: a randomized double-blind placebo-controlled trial. *Am J Gastroenterol* 2009;104:617-23.
23. Kay MH, Wyllie R. Therapeutic endoscopy for nonvariceal gastrointestinal bleeding. *J Pediatr Gastroenterol Nutr* 2007;45:157-71.
24. Calvet X, Vergara M, Brullet E, Gisbert JP, Campo R. Addition of a second endoscopic treatment following epinephrine injection improves outcome in high-risk bleeding ulcers. *Gastroenterology* 2004;126:441-50.
25. Zargar SA, Yattoo GN, Javid G, Khan BA, Shah AH, Shah NA, et al. Fifteen-year follow up of endoscopic injection sclerotherapy in children with extrahepatic portal venous obstruction. *J Gastroenterol Hepatol* 2004;19:139-45.
26. Abd El-Hamid N, Taylor RM, Marinello D, Mufti GJ, Patel R, Mieli-Vergani G, et al. Aetiology and management of extrahepatic portal vein obstruction in children: King's College Hospital experience. *J Pediatr Gastroenterol Nutr* 2008;47:630-4.
27. Pokharna RK, Kumar S, Khatri PC, Chahar CK. Endoscopic variceal ligation using multiband ligator. *Indian Pediatr* 2005;42:131-4.
28. Azarow K, Kim P, Shandling B, Ein S. A 45-year experience with surgical treatment of peptic ulcer disease in children. *J Pediatr Surg* 1996;31:750-3.
29. Teach SJ, Fleisher GR. Rectal bleeding in the pediatric emergency department. *Ann Emerg Med* 1994;23:1252-8.
30. Caplan MS, Jilling T. New concepts in necrotizing enterocolitis. *Curr Opin Pediatr* 2001;13:111-5.
31. Guner YS, Chokshi N, Petrosyan M, Upperman JS, Ford HR, Grikscheit TC. Necrotizing enterocolitis--bench to bedside: novel and emerging strategies. *Semin Pediatr Surg* 2008;17:255-65.
32. Murphy F, Puri P. New insights into the pathogenesis of Hirschsprung's associated enterocolitis. *Pediatr Surg Int* 2005;21:773-9.
33. Kneepkens CM, Meijer Y. Clinical practice. Diagnosis and treatment of cow's milk allergy. *Eur J Pediatr* 2009;168:891-6.
34. Turck D, Michaud L. Lower Gastrointestinal Bleeding. In: Walker WA, ed. *Pediatric Gastrointestinal Disease*. Philadelphia: Elsevier Churchill Livingstone; 2005:266-80.
35. Leung AK, Wong AL. Lower gastrointestinal bleeding in children. *Pediatr Emerg Care* 2002;18:319-23.

36. Brown RL, Azizkhan RG. Gastrointestinal bleeding in infants and children: Meckel's diverticulum and intestinal duplication. *Semin Pediatr Surg* 1999;8:202-9.
37. Durno CA. Colonic polyps in children and adolescents. *Can J Gastroenterol* 2007;21:233-9.
38. Schreiberman IR, Baker M, Amos C, McGarrity TJ. The hamartomatous polyposis syndromes: a clinical and molecular review. *Am J Gastroenterol* 2005;100:476-90.
39. Ebert EC. Gastrointestinal manifestations of Henoch-Schonlein Purpura. *Dig Dis Sci* 2008;53:2011-9.
40. Keshtgar AS. Solitary rectal ulcer syndrome in children. *Eur J Gastroenterol Hepatol* 2008;20:89-92.
41. Kiratli PO, Aksoy T, Bozkurt MF, Orhan D. Detection of ectopic gastric mucosa using ^{99m}Tc pertechnetate: review of the literature. *Ann Nucl Med* 2009;23:97-105.
42. Warrington JC, Charron M. Pediatric gastrointestinal nuclear medicine. *Semin Nucl Med* 2007;37:269-85.
43. Barnert J, Messmann H. Diagnosis and management of lower gastrointestinal bleeding. *Nat Rev Gastroenterol Hepatol* 2009;6:637-46.
44. de' Angelis GL, Fornaroli F, de' Angelis N, Magiteri B, Bizzarri B. Wireless capsule endoscopy for pediatric small-bowel diseases. *Am J Gastroenterol* 2007;102:1749-57.
45. Atay O, Mahajan L, Kay M, Mohr F, Kaplan B, Wyllie R. Risk of capsule endoscope retention in pediatric patients: a large single-center experience and review of the literature. *J Pediatr Gastroenterol Nutr* 2009;49:196-201.
46. Heaton ND, Davenport M, Howard ER. Symptomatic hemorrhoids and anorectal varices in children with portal hypertension. *J Pediatr Surg* 1992;27:833-5.