

Journal of Pediatric Sciences

MALROTATION IN SILVER-RUSSELL SYNDROME: a case report.

Basant Kumar, Vijay D Upadhyaya, Rohan Malik

Journal of Pediatric Sciences 2012;4(2):e133

How to cite this article:

**Kumar B, Upadhyaya VD, Malik R. Malrotation in Silver-Russell syndrome: a case report.
Journal of Pediatric Sciences. 2012;4(2):e133.**

C A S E R E P O R T

MALROTATION IN SILVER-RUSSELL SYNDROME: a case report

Basant Kumar, Vijay D Upadhyaya, Rohan Malik

Department of Pediatric Surgery, Department of Pediatric Gastroenterology, Sanjay Gandhi Post Graduate
Institute of Medical Sciences, Raibareli Road, Lucknow, India

Abstract:

Silver-Russell syndrome (SRS) is a rare, heterogeneous, genetic disorder; characterize by intrauterine and postnatal growth retardation, normal occipital-frontal circumference, body asymmetry and distinctive facial features. 90% of parents of children with SRS complain feeding problems but specific gastro-intestinal diseases have not been recognized as major features. We report a 6 years male child with SRS having malrotation of gut; needs surgery.

Keywords: Silver-Russell syndrome; Malrotation; Gastrointestinal problems.

Accepted: 04/14/2012 Published: 06/01/2012

Corresponding author. Dr. Basant Kumar, Assistant Professor, Department of Pediatric Surgery, Sanjay Gandhi Post Graduate Institute of Medical Sciences, Raibareli Road, Lucknow, U.P. INDIA Phone – 91-8004904839, drbkpg75@rediff.com, drbasant189@gmail.com

Introduction

Silver-Russell syndrome (SRS) is a rare, heterogeneous genetic disorder and is characterized by intrauterine growth restriction, poor postnatal growth, relative macrocephaly, triangular face, asymmetry and feeding difficulties [1]. SRS is the first human disorder associated with epigenetic mutations affecting two different chromosomes [2]. Hypomethylation of the imprinting control region (ICR) 1 on chromosome 11p15 and maternal uniparental disomy (mUPD) for chromosome 7; are found in up to 60% and around 5-10% of patients with SRS, respectively [1].

Blissett *et al* [3]. reported that over 90% of parents of children with SRS had a feeding problem. Common feeding problems are poor appetite, fussiness, slow feeding and problems associated with oral-motor dysfunction[3]. Although, there are a number of published reports describing gastro-intestinal problems associated with SRS, specific gastro-intestinal diseases have not been recognized as major features. Anderson *et al* [4] reported that 77% of patients of SRS had gastro-intestinal symptoms. Major specific symptoms includes gastro-esophageal reflux disease (34%), esophagitis (25%), food aversion (32%) and failure to thrive (63%).⁴ We report a patient with SRS having malrotation of gut; needs surgery. We could not find any literature regarding malrotation in a child with SRS.

CASE REPORT: A 6 year male child; weight 8.6 kg; height 89.4 cm; was referred to us with complaint of recurrent episode of abdominal distension and bilious / non-bilious vomiting from 8 month of age. Child was born normally at term at home and continued to gain weight and height very slowly as compared to other siblings. Motor, language and social developments were normal for age. Child had recurrent episodes of respiratory infections with tachypnea, wheezing and fever which resolved in 2-3 days of medication. Also, the child had recurrent episode of abdominal distension with bilious / non-bilious vomiting followed by diarrhea lasting for 1-2 days. Previously, the child had 1-2 episodes like these per month but now the frequency was increased. History of ATT for 10 months was present. He also had history of one episode of ASOM and recurrent tooth and gum infections. Family history was normal and child was immunized for age. On examination, he was lean and thin, had short stature, broad forehead with normal head circumference, triangular facies, microdontia, crowding of lower teeth, caries in teeth and bilateral clinodactyly [Figure 1].

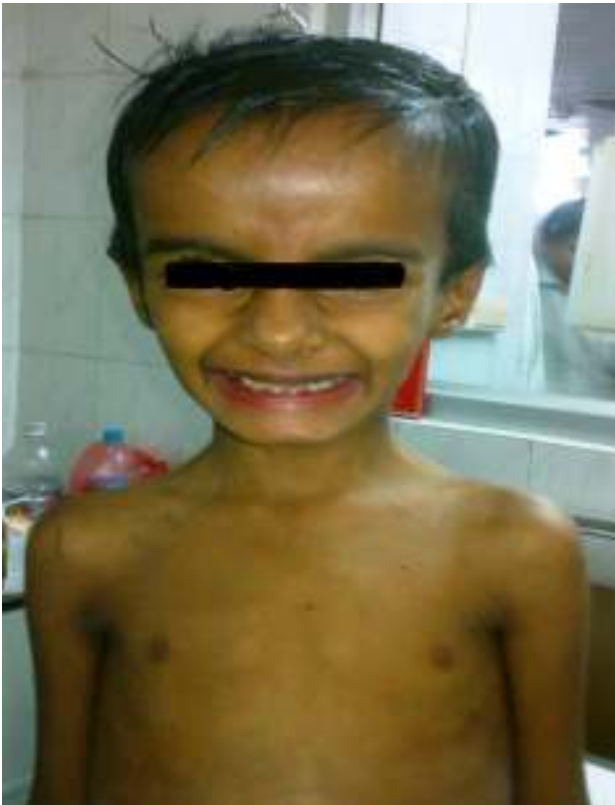

FIGURE – 1: Phenotypic appearance of child. (Classical Facial Features)

Body asymmetry and café-au-lait macules were not found. Abdomen was soft, non-tender but upper abdomen was full with visible bowel loop. Rest examinations were normal. Ultrasound and Barium study were suggestive of malrotation. Stomach and duodenum (D1) were dilated and had retained dye after 2 hour of dye ingestion [Figure 2]. Bone age was delayed (X-ray wrist showing only 2 carpals) [Figure 3].

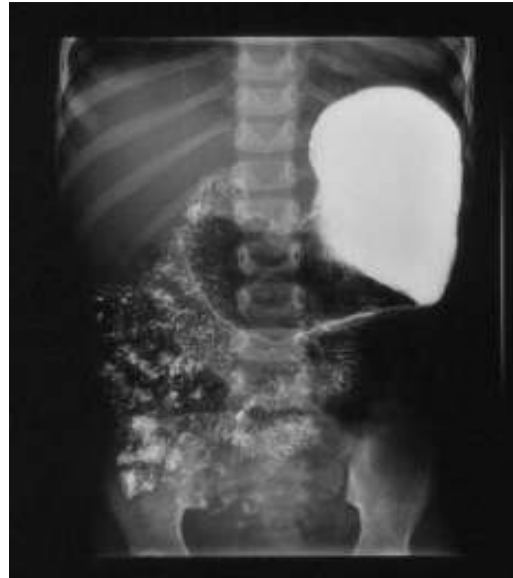

FIGURE – 2: Upper GI barium study showing dilated stomach with retained dye after 2 hours of study.

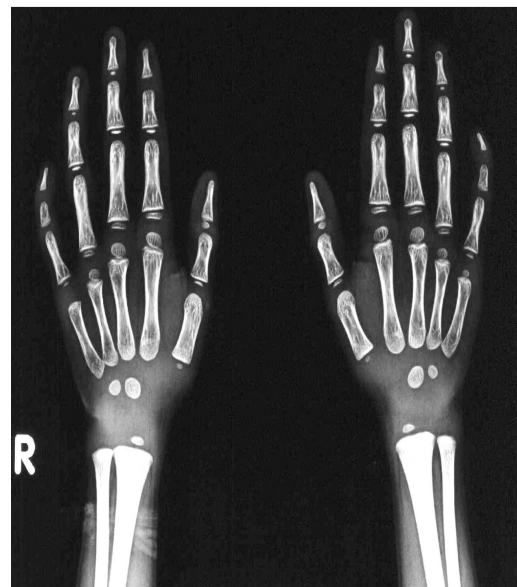


FIGURE – 3: X-ray wrist showing only two carpal bones.

Upper GI endoscopy was normal. All hematological investigations were within normal limits. Genetic evaluation was not done. Child was operated under GA and operative findings include dilated stomach and duodenum (D1 & D2) with Ladd's bands compressing 2nd-3rd part of duodenum. Ileo-caecal region was lying at umbilical region. Superior mesenteric artery was present posterior to duodenum and there were multiple enlarged mesenteric lymph nodes. Ladd's procedure with appendectomy was performed. Post-operative period was uneventful and he was discharged on 10th post-op day.

DISCUSSION: Incidence of SRS ranges from 1 in 3,000 to 1 in 1,00,000 and worldwide more than 500 cases have been reported with equal male to female ratio [5]. The clinical spectrum of SRS ranges from severely affected patient to individuals with very mild features. Several clinical scoring systems for the diagnosis of SRS have been proposed, although none are well established [1]. Only scoring system proposed by Netchine *et al* [6] includes feeding difficulties, which is a major feature of this condition.

Price *et al* [7] described five key features (birth weight \leq -2SD from the mean, poor postnatal growth \leq -2SD from the mean, preservation of occipital-frontal circumference, classic facial features and asymmetry) in SRS patients [1,7]. Patients with classical SRS generally had at least four of these criteria [7]. Classical facial features include a triangular shaped face, frontal bossing, downward corners of mouth, micrognathia and irregular/crowded teeth [1]. Children with SRS also have frequent episodes of hypoglycemia, accompanied by excessive sweating, clinodactyly/camptodactyly and café au lait patches [1,3]. Bone age is often delayed in early childhood but catches up by puberty [3].

Congenital anomalies are described in SRS patients. These include cleft palate, congenital heart disease, genital anomalies and limb defects [1]. One female patient having bicornuate uterus was also reported [7]. Operative interventions in SRS patients were described for hernia, undescended testes, hypospadias, cleft palate, hydronephrosis, testicular cancer, tethered cord, craniopharyngioma [7-10] etc; but, we could not find any literature regarding surgery for gastro-intestinal pathology in SRS patients.

Our case has classical feature of SRS except body asymmetry. He did not have history of hypoglycemia or excessive sweating but parents gave history of poor appetite and slow feeding. Upper GI endoscopy did not show any esophageal pathology (esophagitis) or any

evidence of esophageal reflux diseases as described in patient with SRS, but, child had malrotation, which needs surgery. It might be a "by chance" happening but it should be documented; as we could not find any such case in literature (to our knowledge).

REFERENCES

1. Wakeling EL. Silver-Russell syndrome. Arch Dis Child, Published Online First: 24 February 2011. doi:10.1136/adc.2010.190165.
2. Eggermann T, Gonzalez D, Spengler S, Arslan-Kirchner M, Binder G, Schonherr N. Broad clinical spectrum in Silver-Russell syndrome and consequences for genetic testing in growth retardation. Pediatrics 2009; 123 (5): e929-e931.
3. Blissett J, Harris G, Krik J. Feeding problems in Silver-Russell syndrome. Developmental Medicine & Child Neurology 2001; 43: 39-44.
4. Anderson J, Viskochil D, O'Gorman M, Gonzales C. Gastrointestinal complications of Russell-Silver syndrome: A pilot study. Am J Med Genet 2002; 113 (1): 15-19.
5. Saal HM, Pagon RA, Pipin MG. Re-evaluation of Russell-Silver syndrome. J Pediatr 1985; 107 (5): 733-737.
6. Netchine I, Rossignol S, Dufourg MN, Azzi S, Rousseau A, Perin L, *et al*. 11p15 imprinting center region 1 loss of methylation is a common and specific cause of typical Russell-Silver syndrome: clinical scoring system and epigenetic-phenotypic correlations. J Clin Endocrinol Metab 2007; 92: 3148-54.
7. Price SM, Stanhope R, Garrett C, Preece MA, Trembath RC. The spectrum of Silver-Russell syndrome: a clinical and molecular genetic study and new diagnostic criteria. J Med Genet 1999; 36: 837-842.
8. Tubbs RS, Wellons JC, Oakes WJ. Russell-Silver syndrome and tethered spinal cord. Childs Nerv Syst 2004; 20 (7): 473-75.
9. Weiss GR, Garnick MB. Testicular cancer in a Russell-Silver dwarf. J Urol 1981; 126 (6): 836-37.
10. Draznin MB, Stelling MW, Johanson AJ. Silver-Russell syndrome and craniopharyngioma. J Pediatr 1980; 96 (5): 887-89.