

Journal of Pediatric Sciences

Posterior Reversible Encephalopathy Syndrome in a case of Post-streptococcal Glomerulonephritis

Malay Kumar Dasgupta, Shatanik Sarkar, Chaitali Patra

Journal of Pediatric Sciences 2013;5:e192

How to cite this article:

Dasgupta MK, Sarkar S, Patra C. Posterior Reversible Encephalopathy Syndrome in a case of Post-streptococcal Glomerulonephritis. Journal of Pediatric Sciences. 2013;5:e1192

CASE REPORT

Posterior Reversible Encephalopathy Syndrome in a case of Post-streptococcal Glomerulonephritis

Malay Kumar Dasgupta, Shatanik Sarkar, Chaitali Patra

Department of Pediatric Medicine, R. G. Kar Medical College & Hospital, 1, Khudiram Bose Sarani, Kolkata – 700004, India

Abstract:

Posterior reversible encephalopathy syndrome (PRES) is a clinico-radiological syndrome, characterized by headache, altered mental status, visual disturbances, seizures and radiological features of edema of the posterior cerebral hemisphere, especially of the parieto-occipital region. It is quite rare in children. Here we report a case of post-streptococcal glomerulonephritis in a 9 years old child, who presented with convulsion & visual disturbance and ultimately diagnosed to have PRES on neuro-imaging.

Keywords: *Posterior reversible encephalopathy syndrome, visual disturbance, post-streptococcal glomerulonephritis*

Corresponding author: *Shatanik Sarkar, Block – B, Flat No. 304, DB-24, Deshbandhunagar, Baguiati, Kolkata,*

Pin – 700059, India

Telephone : +919433543732

e-mail: baselinegame@gmail.com

Introduction

The term "posterior reversible encephalopathy syndrome" (PRES) is a clinico-radiological syndrome, manifesting with headache, altered mental status, seizures, visual disturbances, and radiological findings of bilateral hyperintensity in T2 weighted images in the posterior part of cerebral hemispheres [1]. Though it occurs mainly in adults, some cases in children have also been described [2]. It is mostly associated with pre-eclampsia, autoimmune diseases, cytotoxic medication and hypertension. Here we report a similar case of a 9 years child presenting with PRES in association with post-streptococcal glomerulonephritis (PSGN).

Case report

A 9-year-old male child presented to our emergency with generalized tonic-clonic convulsion lasting for about one hour, which was treated with anticonvulsant. On history taking, we found that, there was history of diminished urine volume along with swelling of face and both legs for last 7 days. No history of alteration of urine colour was there. On examination, he had altered consciousness level with Glasgow coma scale 7/15, blood pressure was 180/120 mm Hg and there was bilateral pedal oedema without any signs of meningeal irritation. His

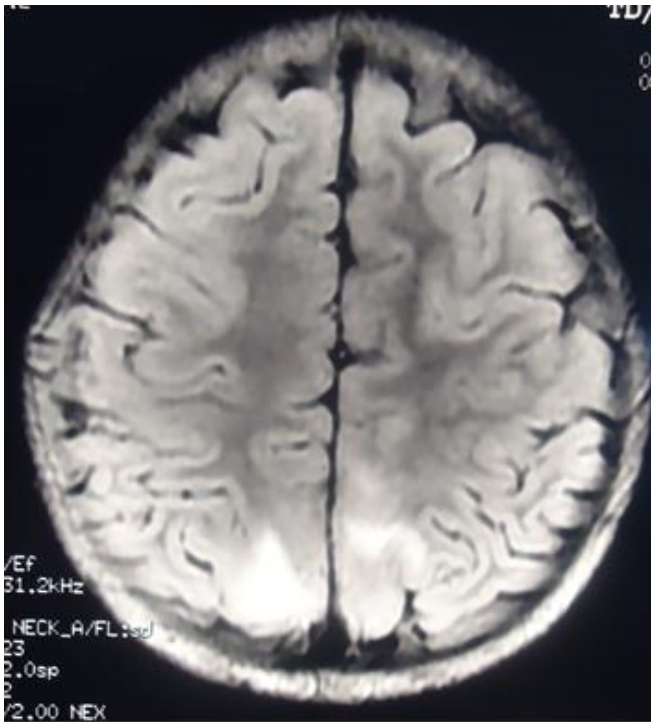


Figure 1. MRI brain showing bilateral areas of abnormal signal intensity in cortical and subcortical areas of the parieto-occipital region, which is hyperintense on T2 weighted image.

blood pressure was controlled with antihypertensive medication. Gradually, as he regained his consciousness by next day morning, he complained of diminished vision in both the eyes.

Urinalysis showed turbidity, 3+ albumin and microscopic hematuria. Urine culture was negative. Blood investigations were otherwise normal, except low albumin (3.1 g/dl), low C3 and positive Antistreptolysin O (ASO) titer (800-1200). Fundoscopic examination didn't reveal any abnormality. Ultrasonography of abdomen was also normal. He was diagnosed as a case of acute PSGN.

Magnetic resonance imaging (MRI) showed bilateral areas of abnormal signal intensity in cortical and subcortical areas of the parieto-occipital region, which displayed hypointense signal on T1 weighted image (T1WI) and hyperintense signal on T2WI [Figure 1].

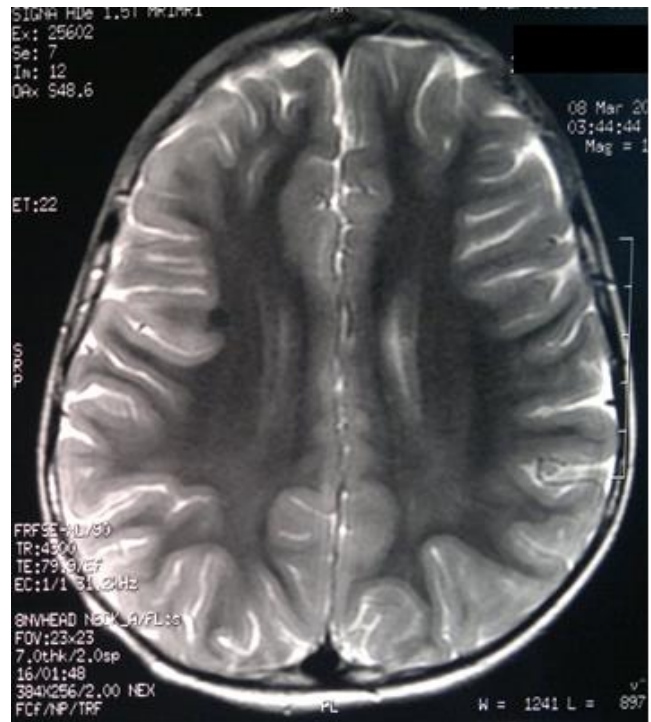

Figure 2. Repeat MRI showing normal picture with resolution of the abnormal signal intensity.

He regained his vision on 4th day with normalization of urinary abnormality. The patient was discharged on day 5 of admission with plan for regular follow-up. After 7 weeks, the C3 level was 1.2 g/L (Normal reference range: 0.9-1.8) and repeat MRI showed normal picture with resolution of the abnormal signal intensity [Figure 2].

The diagnosis of PRES was established due to the presence of hypertension, typical bilateral MRI findings and reversibility of the lesions.

Discussion

Posterior reversible encephalopathy syndrome (PRES), also known as reversible posterior leukoencephalopathy syndrome (RPLS), was initially described by Hinchey et al. in 1996. It is characterised by headache, altered mental status, seizures, and cortical blindness. Radiologically there are features of cerebral edema with hyperintense signals on T2 weighted images of MRI. PRES has been described to be

associated with hypertensive encephalopathy, pre-eclampsia, eclampsia, autoimmune diseases, minimal change nephrotic syndrome, chronic renal failure, post-transplantation, malignancies, hemolytic uremic syndrome, acute intermittent porphyria, vasculitis, hypercalcemia, oxybutynin, intravenous immunoglobulins, certain immunosuppressive, and cytotoxic drugs [3-5]. It can rarely occur in children [2].

Hypertension has often been emphasized as a common feature of PRES. Two possible mechanisms proposed in the pathophysiology of PRES are (a) vasospasm due to sudden rise of BP and (b) loss of autoregulation of brain. In the first hypothesis, it has been suggested that vasospasm contributes to ischemia and cytotoxic edema at regions of the arterial borderline zone [6]. The second, more recent hypothesis is supported by diffusion images suggesting that dilatation develops in cerebral arterioles due to autoregulatory failure. The objective of cerebral autoregulation is to keep blood flow constant, and to protect the brain during changes in BP; however, sudden and severe increases in BP can impair autoregulation, and lead to arteriolar vasodilatation and endothelial dysfunction (breakdown of blood brain barrier) leading to extravasations of plasma and red blood cells causing vasogenic edema [7].

The posterior cerebral arterial circulation is supplied by the vertebro-basilar system. There is relatively less sympathetic innervation in the posterior part of brain than other parts. This makes it susceptible to hyperperfusion and vasogenic edema in that part during acute blood pressure elevations, which may explain the predilection of majority of the lesions of PRES in the vascular territory of posterior circulation [8].

The role of neuro-imaging is to establish the initial diagnosis and to exclude the other causes of neurological dysfunction. On MRI brain, bilateral symmetrical edema in the parieto-occipital region is hyperintense on T2-weighted and hypointense on T1-weighted sequences [5]. Diffusion-weighted imaging (DWI) can differentiate this condition from other major

diseases such as infarction that are diffusion restricted [9].

PRES is a treatable and reversible cause of acute encephalopathy with blindness, as long as diagnosis is made early and appropriate treatment is ensured. Without early and prompt treatment, the syndrome may lead to permanent brain injury or neurological sequelae such as chronic epilepsy [5]. We need to be aware of this unusual neurological complication of PSGN, as early recognition may improve prognosis.

Though the association between PSGN and PRES has been reported earlier [2,10,11], acute glomerulonephritis presenting with symptoms of PRES is extremely rare in children [3,12]. In our case, the boy presented with neurological symptoms, was found to be hypertensive and subsequently diagnosed as acute glomerulonephritis (AGN). He had rapid resolution of neurological symptoms with adequate treatment of hypertension. An important characteristic of PRES is reversibility of the imaging abnormalities, as seen in our case.

Our case highlights the possibility that cortical blindness may develop as a complication of AGN in children, even after resolution of proteinuria. Prevention of the occurrence of neurological deficits in children with AGN and hypertensive encephalopathy requires careful evaluation and appropriate management of hypertension.

Conclusion

We conclude that PRES, as a possibility, should be considered in children with PSGN as a complication presenting with neurological findings, even with status epilepticus. It can be confirmed by MRI showing typical bilateral hyperintensity mainly in parieto-occipital region in T2 weighted image. By early recognition and adequate treatment, permanent neurological damage and possible death can be prevented. We need to be aware of this unusual neurological complication, as early recognition may improve prognosis.

References

1. Kwon S, Koo J, Lee S. Clinical spectrum of reversible posterior leukoencephalopathy syndrome. *Pediatr Neurol* 2001;24:361-4
2. Gupta S, Goyal VK, Talukdar B. Reversible posterior leukoencephalopathy syndrome in post streptococcal glomerulonephritis. *Indian Pediatr* 2010;47:274-6.
3. Hinchey J, Chaves C, Appignani B, Breen J, Pao L, Wang A, et al. A reversible posterior leukoencephalopathy syndrome. *N Engl J Med*. 1996;334:494–500.
4. Garg RK. Posterior leukoencephalopathy syndrome. *Postgrad Med J*. 2001;77:24–8.
5. Ergun T, Lakadamyali H, Yilmaz A. Recurrent posterior reversible encephalopathy syndrome in a hypertensive patient with end-stage renal disease. *Diagn Interv Radiol*. 2008;14:182–5.
6. Naidu K, Moodley J, Corr P, Hoffmann M. Single photon emission and cerebral computerized tomographic scan and transcranial Doppler sonographic findings in eclampsia. *Br J Obstet Gynaecol*. 1997;104:1165–72.
7. Vaughan CJ, Delanty N. Hypertensive emergencies. *Lancet*. 2000;356:411–7.
8. Jones BV, Egelhoff JC, Patterson RJ. Hypertensive encephalopathy in children. *Am J Neuroradiol* 1997;18: 101-106.
9. Covarrubias DJ, Luetmer PH, Campeau NG. Posterior reversible encephalopathy syndrome: prognostic utility of quantitative diffusion - weighted MR images. *Am J Neuroradiol*. 2002;23:1038–48.
10. Casali-Rey JI, Dávalos EG, López-Amalfara A, Julio-Muñoz D, Pagano MA. Posterior reversible encephalopathy syndrome: some case reports. *Rev Neurol*. 2003;37:224–7.
11. Ozcakar ZB, Ekim M, Fitoz S, Teber S, Hizel S, Acar B, et al. Hypertension induced reversible posterior leukoencephalopathy syndrome: a report of two cases. *Eur J Pediatr*. 2004;163:728–30.
12. Aeby A, David P, Fricx C, Jissendi P, Blecic S, Van Bogaert P. Posterior reversible encephalopathy syndrome revealing acute post-streptococcal glomerulonephritis. *J Child Neurol*. 2006;21:250–1.