

Journal of Pediatric Sciences

Subclinical left ventricle dysfunction revealed by echocardiography in a neonate with a neck hemangioma

Maria Gogou, Anastasia Keivanidou, Andreas Giannopoulos

Journal of Pediatric Sciences 2016;8:e255

How to cite this article:

Gogou M, Keivanidou A, Giannopoulos A. Subclinical left ventricle dysfunction revealed by echocardiography in a neonate with a neck hemangioma. Journal of Pediatric Sciences. 2016;8:e255

CASE REPORT

Subclinical left ventricle dysfunction revealed by echocardiography in a neonate with a neck hemangioma

Maria Gogou, Anastasia Keivanidou, Andreas Giannopoulos

2nd Department of Pediatrics, School of Medicine, Aristotle University of Thessaloniki, University General Hospital AHEPA, Thessaloniki, Greece

Abstract:

Infantile hemangiomas consist a frequent childhood tumor and have been associated with hemodynamic complications. A 2-week-old female neonate presented to our clinic due to a large neck hemangioma. Although the neonate was hemodynamically stable and no apparent clinical signs of heart failure were present, echocardiography revealed dysfunction of the left ventricle, which included dilatation and reduced ejection fraction. Heart failure therapy along with propranolol for the treatment of the hemangioma were initiated. The hemangioma showed progressive regression and heart function gradually improved. Clinicians should be aware of all possible cardiovascular complications of infantile hemangiomas and the need for thorough cardiac evaluation, including echocardiography, of infants with giant hemangiomas may be considered.

Keywords: hemangioma, heart dysfunction, heart failure, neonate

Corresponding author: Dr Maria Gogou, MD, Dimitriou Nika 44, 60 100, Katerini, Greece

Tel number: 0030 6978905873

e-mail: mariaangogou@gmail.com

Case report

Infantile hemangiomas are the most common vascular tumors of childhood. Although most lesions resolve spontaneously, a minority can cause cosmetically or functionally significant lesions [1].

We report the case of a two-week-old female neonate who presented to our outpatient clinic with a large neck hemangioma. The neonate was born to two phenotypically healthy parents and was delivered through normal labor on 38th week of an uneventful gestation. Perinatal history was reported to be normal with Apgar scores 8 at 1 minute and 9 at 5 minutes. There was no family history of hemangiomas.

On physical examination a soft violaceous mass with surface telangiectasias and peripheral pallor was located in the right supraclavicular region and was extending from the right clavicle to the middle of the right cervical lateral surface. The hemangioma was present at birth, but showed rapid growth within the two first weeks of life, attaining a size of 5,6cm x 4,4cm at the time of evaluation (Figure-1).

The neonate was hemodynamically stable with no signs and symptoms of heart failure. No murmur was audible, vital signs were within normal ranges for age (heart rate: 160/min with normal range 105-180/min, respiratory rate:

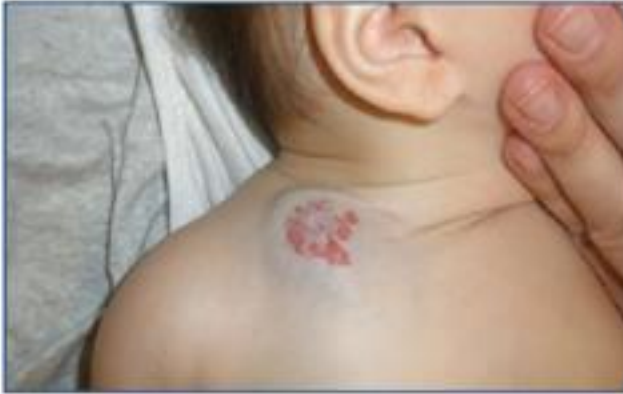

Figure 1: The hemangioma was located in the right supraclavicular region and had a size of 5,6cm x 4,4cm at the time of evaluation.

45/min with normal values <60/minute, blood pressure: 86/60mmHg-75th percentile, SpO₂:8% with normal values \geq 93%) and somatometric parameters were also within normal percentiles for gender and age (body weight: 2,61kg-75th percentile, body length: 53cm-90th percentile). Laboratory tests (complete blood count, biochemical and coagulation tests) had no pathologic findings. On the other hand, twelve-lead electrocardiography showed flattened ST segment at the lateral leads, while echocardiography revealed increased left ventricle size for age according to Detroit data about z-scores of cardiac structures, as well as decreased systolic function [2].

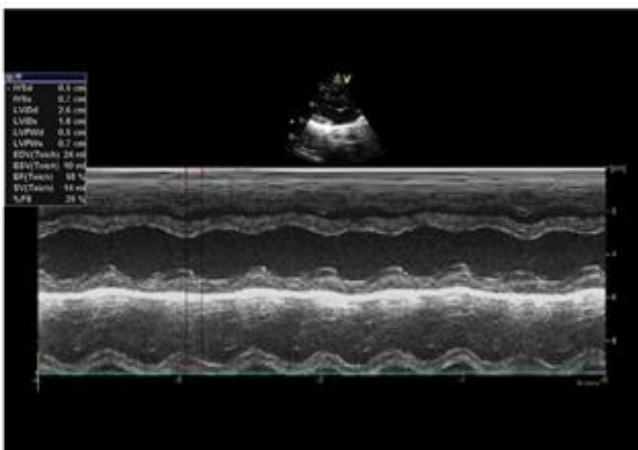


Figure 2: Left ventricle dilatation (end-diastolic diameter: 26mm) and dysfunction (ejection fraction: 58%) were detected in echocardiography study without any apparent clinical symptoms of heart failure.

Left ventricle end-diastolic diameter was 26mm, z-score=3,76, left ventricular end-systolic diameter was 18mm, z-score=3,85 and left ventricle ejection fraction was 58%, normal values in childhood 64-83%. (Figure-2) Brain and abdomen ultrasound revealed no further hemangiomas location.

We commenced per os heart failure therapy, which included digoxin (0,01mg/kg per day in 2 doses) and diuretics (furosemide: 1mg/kg per day in 2 doses and spironolactone: 1mg/kg per day in 2 doses) along with propranolol (2mg/kg per day in 2 doses). A month later left ventricle size and function had recovered and heart failure therapy progressively stopped. Therapy with propranolol continued for the treatment of the hemangioma. After 4 months of follow up the hemangioma had a size of 3,7cm x 3cm (33% and 35% regression respectively) and left ventricle size and function were within normal ranges (left ventricle end-diastolic diameter: 20mm, z-score=1,13, left ventricular end-systolic diameter: 11mm, z-score=-0,04 and ejection fraction: 80%).

Discussion

Infantile hemangiomas occur in 5-10% of infants consisting the most common childhood tumor. They are usually not present at birth and are noted within the first few weeks of life. There is typically an initial proliferative phase, with rapid tumor growth taking place in the first several months of life. This is followed by an involution phase, with slow, spontaneous resolution. A residual fibro fatty mass often persists [1]. Although they are istopathologically benign, they may be pathophysiologically malignant, as they can induce significant hemodynamic complications.

These complications can be due to either anatomical or functional impact. Marmade L, et al. presented the case of an atrial hemangioma which caused cardiac tamponade and was revealed as cardiogenic shock, but this case affected a young adult [3]. On the other hand, according to Shepherd, et al. during their rapid

proliferative state (shortly after birth and during the first months of life) hemangiomas can behave as transiently high-flow arteriovenous malformations and create a high cardiac output state. This state leads to a circulatory overload and elevates diastolic pressure in the left ventricle, thus predisposing to pulmonary hypertension. With time this overload may evolve to systolic failure with reduced levels of cardiac output [4]. According to Blei, et al. hemangiomas with such a propensity to develop a high flow element are mainly those located in the liver, as well as in the head and neck (parotid, scalp, upper arm, upper lip) [5]. Indeed, Hsiao, et al. reported a neonate with a huge congenital hemangioma of the scalp presenting as high-output heart failure and Kasabach-Merritt syndrome [6]. Moreover, a case of a female neonate with a large congenital hemangioma on the neck causing heart failure and thrombocytopenia was described by Weitz, et al., while Sidwell, et al. reported a case of an infant with neonatal hemangiomatosis and secundum atrial septal defect who developed severe heart failure [7,8].

As regards treatment, an early surgical approach is usually avoided with the use of supportive treatment for heart failure (digoxin, diuretics) combined with propranolol. It was Leaute-Labreze et al. in 2008 who first described the efficacy of β -blockers for the treatment of infantile hemangiomas and further studies subsequently documented the drug's efficacy and safety as a first-line, as well as second-line (after steroid use) therapy [9]. Different mechanisms have been proposed for this action of propranolol, including the promotion of pericyte-mediated vasoconstriction, the inhibition of vasculogenesis and catecholamine-induced angiogenesis and the disruption of hemodynamic force-induced cell survival [1].

In our patient an infantile large neck hemangioma was associated with subclinical systolic dysfunction of the left ventricle, which was revealed in an echocardiography study and included dilatation of left ventricle and reduction of ejection fraction. Heart failure treatment with

digoxin and diuretics (furosemide and spironolactone) was initiated along with propranolol and after 6 months of follow-up left ventricle had recovered and the hemangioma showed a marked regression.

However, it remains unclear whether it was the regression of the hemangioma itself or the heart failure therapy that mainly led to normalization of left ventricle function. A series of such cases could provide stronger evidence about the degree of association of left ventricle dysfunction with the size of the hemangioma.

According to Drolet, et al although routine electrocardiographic screening in children with hemangiomas has been advocated before initiation of treatment with propranolol, echocardiography is not necessary as a routine screening tool, because structural and functional heart disorders have not been associated with uncomplicated hemangiomas [10]. However, subtle subclinical heart dysfunction may be present in cases of infantile hemangiomas, even without apparent symptoms and the presence of cardiac dysfunction could consist an additional indication for early intervention along with disturbance of vital functions, lesions in centropalpebral area and high risk for permanent deformity. On this basis, increased awareness about possible heart complications in infants with hemangiomas is needed and a thorough cardiac evaluation including echocardiography may be considered in cases of infants with giant hemangiomas.

Acknowledgements: None

Conflict of Interest: The authors declare that they have no conflict of interest.

Financial support: This research received no specific grant from any funding agency, commercial or not-for-profit sectors.

Ethical standards: This article does not contain any studies with human participants or animals performed by any of the authors.

References

1. Kilcline C, Frieden IJ. Infantile hemangiomas: how common are they? A systematic review of the medical literature. *Pediatr Dermatol* 2008; 25:168-73
2. Park MK. *The Pediatric Cardiology Handbook*, 3rd ed. Mosby, Philadelphia 2003; p:53-4
3. Marmade L, Laaroussi M, Elkouache M, Khales Y, Sefiani A, Elakil R, et al. Haemangioma of the right atrium revealed by cardiogenic shock. *Arch Mal Coeur Vaiss* 2005;98:337-41
4. Shepherd D, Adams S, Wargon O, Jaffe A. Childhood wheeze while taking propranolol for treatment of infantile hemangiomas. *Pediatr Pulmonol* 2012;47:713-5
5. Blei F, Rutkowski M. Transiently arterialized hemangiomas: relevant clinical and cardiac issues. *Lymphat Res Biol*. 2003;1:317-20
6. Hsiao CH, Tsao PN, Hsieh WS, Chou HC. Huge, alarming congenital hemangioma of the scalp presenting as heart failure and Kasabach-Merritt syndrome: a case report. *Eur J Pediatr* 2007;166:619-20
7. Weitz NA, Lauren CT, Starc TJ, Kandel JJ, Bateman DA, Morel KD, et al. Congenital cutaneous hemangioma causing cardiac failure: a case report and review of the literature. *Pediatr Dermatol* 2013;30:180-90
8. Sidwell RU, Daubeney PE, Porter W, Roberts NM. Neonatal hemangiomatosis and atrial septal defect: a rare cause of right heart failure in infancy. *Pediatr Dermatol* 2004;21:66-9
9. Dotan M, Lorber A. Congestive heart failure with diffuse neonatal hemangiomatosis--case report and literature review. *Acta Paediatr* 2013;102:232-8
10. Drolet BA, Frommelt PC, Chamlin SL, Haggstrom A, Bauman NM, Chiu YE, et al. Initiation and use of propranolol for infantile hemangioma: report of a consensus conference. *Pediatrics* 2013;131:128-40