



The effect of patient's age on the outcomes of Salter pelvic osteotomy

Fatih INCI ¹ , Guven BULUT ² , Seyit Ali GUMUSTAS ² 

¹ Department of Orthopedics and Traumatology, Ankara Bilkent City Hospital, Ankara, Turkey.

² Department of Orthopedics and Traumatology, Istanbul Kartal, Dr. Lutfi Kirdar Training and Research Hospital, Istanbul, Turkey.

Corresponding Author: Fatih INCI

E-mail: fatihinci@gmail.com

Submitted: 23.12.2020

Accepted: 27.02.2021

ABSTRACT

Objective: We hypothesized that as the patient's age increases, the outcomes of Salter pelvic osteotomy (SPO) get worse. This study aims to compare the results of surgery in developmental dysplasia of the hip (DDH) with at which age SPO is performed.

Patients and Materials: Forty six hips of 36 patients with at least 1 year of regular radiological and clinical follow-up were included in this study. The patients were retrospectively divided into three groups, group I for ages between 18 months and 4 years, group II for ages between 4 and 6 years, and group III for ages over 6 years. The clinical and radiological results of the patients were compared between groups.

Results: At the time of surgery, the mean age of patients was 4.51 years (18 months-11 years). After a mean follow-up of 72.7 months; although there was no statistically significant difference between groups according to Severin's radiological criteria, it was observed that the success of the clinical outcome decreased and the avascular necrosis (AVN) rates increased in children who were operated after the age of 6 years.

Conclusions: Although, SPO was an effective treatment option for patients with DDH after the age of walking, it might cause a decrease in the success of clinical outcomes and an increase in AVN after 6 years of age.

Keywords: Developmental hip dysplasia, Surgical treatment, Avascular necrosis, Patient age, Salter pelvic osteotomy

1. INTRODUCTION

The ideal time for diagnosis and treatment of developmental dysplasia of the hip (DDH) is the neonatal period. Early diagnosis is very important for the success of treatment [1]. Guidelines for detection and improved screening techniques have aided in early diagnosis, significantly reducing the number of patients requiring closed or open procedures [2,3].

While open or closed reduction may be sufficient in the early period of DDH treatment, pelvic and/or femoral osteotomies may be necessary for addition to the reduction in the treatment of DDH after the age of walking. Salter pelvic osteotomy (SPO) is an effective surgical treatment option in patients with DDH

after the age of walking and although it is recommended to be performed between 18 months and 6 years [4], there is no definite upper age limit [5].

In this study, we evaluated the effect of age, which the patients had been operated on, with the radiological and clinical results in the treatment of DDH. These patients were surgically treated with SPO with or without femoral shortening. This study aims to compare the results of surgery in DDH with the age at which SPO was performed.

How to cite this article: Inci F, Bulut G, Gumustas SA. The effect of patient's age on the outcomes of Salter pelvic osteotomy. *Marmara Med J* 2021; 34(2):175-179. doi: 10.5472/marumj.945174

2. PATIENTS and METHOD

This study was approved by the Istanbul, Kartal Dr.Lutfi Kirdar Training and Research Hospital Ethics Committee (approval number: 2020/514/173/3).

In this retrospective study, we analyzed 46 hips of 36 patients who had undergone SPO surgery (with or without femoral shortening). Patients were followed up for at least 1 year. The patients comprised 33 (91.7%) girls and 3 (8.3%) boys with a mean age of 4.51 years (range, 18 months-11 years) at the time of surgery. Bilateral DDH was present in 10 (27.8%) patients, left hip involvement was present in 11 (30.6%) and right hip involvement was present in 15 (41.6%). The demographic data of the patients are given in table I.

Table I. Demographic data of the patients.

Patient demographics	n (number of patients)
Right DDH	15
Left DDH	11
Bilateral DDH	10
Female/ Male	33 / 3
Group I (18 months-4 years)	19
Group II (4-6 years)	11
Group III (6-11 years)	10

DDH: developmental dysplasia of the hip

The surgery was performed with single-stage surgery for all the patients. No preoperative traction was applied to any patient. Patients with a definite diagnosis of the disease and no prior operation were included in the study. Considering exclusion criteria, cases with other comorbidities such as cerebral palsy, arthrogryposis, myelomeningocele were excluded from the study. Type of surgery for each patient, patient's age at the time of diagnosis, gender, level of pain, limping degree, and decreased range of motion of the hip joint were recorded on a data sheet. Patients were invited for follow-up physical examination and control radiographs of pelvic were obtained. Open reduction was performed through the anterior Smith Peterson approach in all hips [6,7]. The SPO decision for hips where open reduction could not be applied was determined by the Acetabular Index (AI) [8].

To investigate the effect of surgical age on clinical and radiological outcomes, the cases were retrospectively divided into three age groups. Nineteen (41.3%) cases between 18 months and 4 years were studied in group I (Figure 1), 16 (34.8%) cases between 4-6 years in group II (Figure 2), and 11 (23.9%) cases over 6 years in group III (Figure 3).

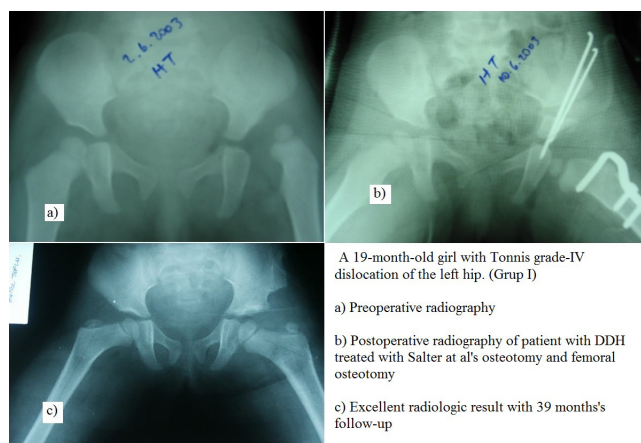


Figure 1. Radiological evolution of an 19 month-old girl patient with DDH treated with Salter osteotomy and femoral osteotomy. (Group I)

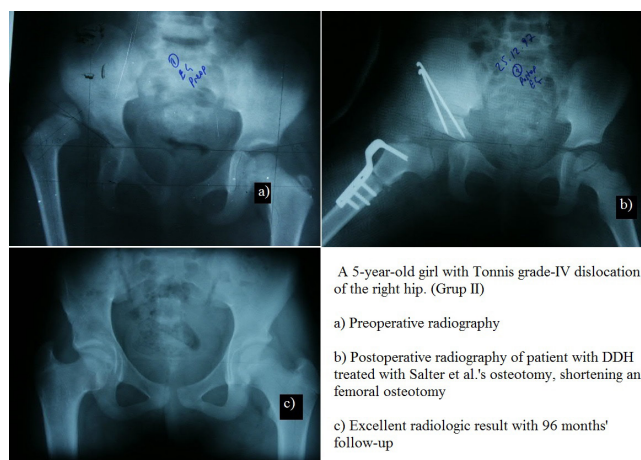


Figure 2. Radiological evolution of a 5-year-old girl patient with DDH treated with Salter osteotomy, shortening and femoral osteotomy. (Group II)

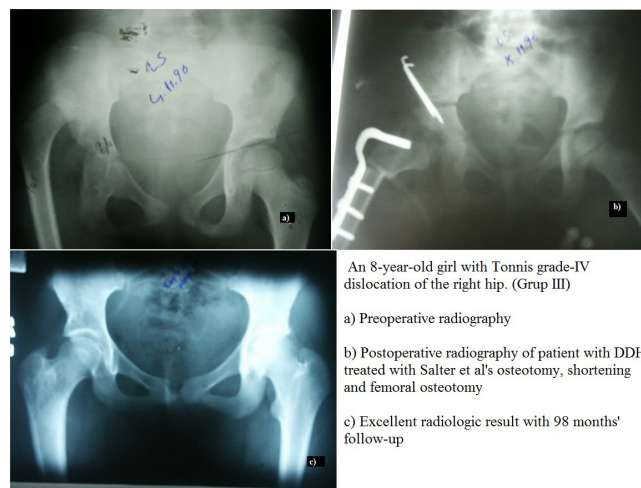


Figure 3. Radiological evolution of a 8-year-old girl patient with DDH treated with Salter osteotomy, shortening and femoral osteotomy. (Group III)

The pelvipedal plaster applied during surgery was removed after 4 weeks and active hip movements were recommended without weight-bearing on the operated hip for the first 20 days. The preoperative and postoperative pelvis radiographs were examined and the AI and centre-edge angle (CEA) which were the signs of lateral coverage and showing the long-term success of the surgery were measured. Postoperative radiological evaluation was made according to the Severin criteria [9] (Table II) and the clinical evaluation was performed according to the modified McKay criteria [10] (Table III).

Table II. Severin's radiological evaluation criteria [9].

CLASS	RESULTS
I (Very good)	Normal hip
A	CEA>19° (6-13 years) CE>25° (>14 years)
B	CE 15°-19° (6-13 years) CE 20°-25° (>14 years)
II (Good)	The head, neck or acetabulum has a mild deformity, but hip joint is concentrically reduced. CE values are the same as Class Ia and Ib. Dysplastic hip (no subluxation)
III (Moderate)	CE<20° (>14 years) CE<15° (6-13 years)
IV (Bad)	Subluxated hip
A	Moderate subluxation CE>0°
B	Severe subluxation CE<0°
V (Very bad)	The head is articulated with the secondary acetabulum at the top of the original acetabulum
VI (Redislocated)	Redislocated hip

CEA: center-edge angle

Table III. Modified McKay clinical evaluation criteria [10]

Modified McKay clinical evaluation criteria group	STABILITY-PAIN-LIMPING-TRANDELENBURG-RANGE OF MOTION-DISLOCATION
Group 1 (Excellent)	A stable and painless hip. No limping. Trandelenburg test (-). Full range of joint motion.
Group 2 (Good)	A stable and painless hip. Normal walking or slight limping. Trandelenburg test (-). There is a slight limitation in the range of motion of the joint.
Group 3 (Moderate)	A stable and painless hip. There's limping. Trandelenburg test (+). There is a moderate restriction of the range of motion of the joint
Group 4 (Bad)	An unstable, painful hip. There's limping. Trandelenburg test (+). There is no dislocation even though the range of motion of the joint is very limited.
Group 5 (Unsuccessful)	An unstable, painful or painless hip. There's limping. Trandelenburg test (+). There is dislocation.

Postoperative avascular necrosis (AVN) was diagnosed according to Salter criteria [11]. Within one year after the reduction, absence of an ossification nucleus, non-growth of an existing ossification nucleus, increase in its density and fragmentation, metaphyseal enlargement and decrease in bone density of the femoral neck, and the development of deformity in the femoral head and neck were evaluated as AVN findings [11]. The radiological findings of the hips where AVN developed were identified and classified according to the Kalamchi-MacEwan classification [12] (Table IV).

Table IV. Kalamchi-Mac Ewen AVN classification [12].

GROUP	FINDING
1	Changes in the center of ossification
2	Group 1+ Lateral physis injury
3	Group 2+Central physis injury
4	Group 3+Whole physis injury

Statistical Analysis

For the statistical analysis, IBM SPSS 25.0 (Armonk, NY: IBM Corp.) and MedCalc 15.8 (MedCalc Software Ltd, Acaciaaan Ostend Belgium) was used. The definitive statistical analysis was used for ages and the characteristics of the groups, the clinical and radiological findings obtained for the groups, and developing complications were statistically analyzed by using the Mann-Whitney, Paired Samples t-test, and Student's t-test. The values of p<0.05 were considered statistically significant.

3. RESULTS

There were no significant differences in terms of gender distribution, disease type of patients (patients with high hip dislocation, subluxation, acetabular dysplasia, or both), type of surgery, and additional operations (p>0.05). The patients were followed up for a mean of 72.7 months (range, 12-160 months).

As a result of radiological evaluation in all groups, the mean values of AI were measured as 31.6° preoperatively and 16.6° at the late postoperative period. When the AI values were measured preoperatively and at the final follow-up examination were compared, it was determined that mean AI was improved 15° in all groups and this was statistically significant (p<0.05). Mean values of femoral neck-shaft angle were 139.6° preoperatively and 130.7° at the final follow-up examination. A significant decrease as 9° was observed at the final controls in all groups (p<0.05) (Table V).

In the clinical evaluation according to modified McKay criteria, excellent and good results were obtained in 16 of 19 hips (84.2%) in group I, in 13 of 16 hips (81.3%) in group II and 6 of 11 hips (54.5%) in group III. According to age groups, more successful results were obtained at (Group I) younger ages (Table VI).

According to Severin's radiological criteria, excellent and good results were obtained in 79.1% of group I, 81.3% of group II,

and 81.8% of group III. There was no statistically significant difference between the groups ($p>0.05$) [9] (Table VI).

According to the Kalamchi-McEwan AVN classification, AVN was observed in 5 of 19 hips (26.3%) in group I, in 5 of 16 hips (31.2%) in group II and 10 of 11 hips (90.1%) in group III. A statistically significantly higher rate of AVN was determined in group III ($p<0.05$) [12] (Table VII).

Table V. Preoperative and final control mean AI and femur neck-body angle values of all patients.

Mean AI		Mean femoral neck-shaft angle	
Preoperative	Final control	Preoperative	Final control
31.6°	16.6°	139.6°	130.7°
15° correction		9° correction	
Significant improvement ($p<0.05$)		Significant decrease ($p<0.05$)	

Table VI. Clinical and radiological evaluation according to groups

	Group I (18 months-4 years)	Group II (4-6 years)	Group III (>6years)	Statistical comments
Modified McKay criteria (Excellent and good results)	84.2%	81.3%	54.5%	More successful results at younger ages
Sever's radiological criteria (Very good and good results)	79.1%	81.3%	81.8%	No statistically significant difference

Table VII. Kalamchi-McEwen classification of AVN seen in groups

	Group I	Group II	Group III	Comment
Kalamchi-McEwen (AVN rate)	5\19 (26.3%)	5\16 (31.2%)	10\11 (90.1%)	AVN increases as surgical age increases

4. DISCUSSION

This study revealed that the majority of patients with DDH who underwent SPO surgery had satisfactory results according to Severin's radiological criteria. However, this study also showed that functional outcomes and AVN rates were worse in children operated after the age of 6 when compared to younger age groups.

In this study, we found radiologically satisfactory results (excellent and good results) The success rate was 79.1% in group I, 81.3% in group II, 81.8% in group III. There was no statistically significant difference between the groups ($p>0.05$) as observed by other studies [13,14,15,].

Barrett et al., did not specify an upper age limit for SPO, but reports revealed that successful outcomes were mostly between 1.5 and 4 years of age [16]. Gulman et al.,

reported that when cases were divided into three groups as 18 months-4 years of age, 4-6 years, and over 6 years, the most successful results with SPO were obtained in the patients between 18 months-4 years age group [17]. We, clinically achieved satisfactory (excellent and good results) results in group I (84.2%), group II (81.3%), and group III (54.5%). Although, groups I and II had similar satisfactory results, group III had statistically significantly poor results. Thus, we found that the clinical results were significantly poorer in group III, which included patients older than six years as observed by other studies [5,13,16,17].

It is a general belief that the age of the patient is an effective factor in the surgical outcomes and that this success is decreasing with the increased age [5]. Although, there is a consensus about the lower limit of age for SPO, there is serious debate about the upper limit [5,6]. According to Salter, the upper limit of age is 6 years [11].

Avascular necrosis seen after SPO was reported mostly at rates between 1.2% and 63.4% [5,6,16,17]. In this study, we found the rate of AVN as 26.3% in group I, 31.1% in group II and 90.1% in group III according to age groups. We found that the ratio of AVN increased in the patients (10/11) who were older than 6 years of age. The rate of AVN reported by Gulman et al., was 63.3% which was extremely high compared to other studies and was attributed to inadequate surgical techniques and enforced indications [17].

In this study, the average correction of the CEA (9 degrees) and the AI (5 degrees) obtained by the Salter innominate osteotomy (SIO) were within the range of correction reported in most studies [8,13,17-19].

In conclusion, early diagnosis and treatment are very important in DDH. Although, SPO is an effective treatment option for patients with DDH after the age of walking, it might cause a decrease in the success of clinical outcomes and an increase in AVN after 6 years of age.

Compliance with Ethical Standards

Ethical approval: This study was approved by the Istanbul Kartal Dr.Lutfi Kirdar Training and Research Hospital Ethics Committee (approval number: 2020/514/173/3).

Financial Disclosure: The authors declared that this study has received no financial support.

Conflict of Interest: The authors have no conflicts of interest to declare.

Authors' Contributions: Concept: FI and GB, Design: FI, GB and SG, Supervision: FI, GB and SG, Data Collection and/or Processing: FI, GB Literature review: FI and GB, Writing the article: FI, GB and SG, Critical review – FI, GB and SG. All authors read and approved the final version of the article.

REFERENCES

- [1] “Weinstein SL. Natural history of congenital hip dislocation (CDH) and hip dysplasia. *Clin Orthop Relat Res* 1987;225:62-76.
- [2] “Wirth T, Stratmann L, Hinrichs F. Evolution of late presenting developmental dysplasia of the hip and associated surgical procedures after 14 years of neonatal ultrasound screening. *J Bone Joint Surg Br* 2004;86:585-9.
- [3] “Biedermann R, Eastwood DM. Universal or selective ultrasound screening for developmental dysplasia of the hip? A discussion of the key issues. *J Child Orthop* 2018;12:296-301. doi : 10.1302/1863-2548.12.180063
- [4] “Murphy R F, Kim YJ. Surgical management of pediatric developmental dysplasia of the hip. *J Am Acad of Orthop Surg* 2016; 24:615–24. doi:10.5435/jaaos-d-15-00154
- [5] “Salter RB, Dubos JP. The first fifteen years’ personal experience with innominate osteotomy in the treatment of congenital dislocation and subluxation of the hip. *Clin Orthop Relat Res* 1974; 98: 72-103. doi: 10.1097/00003.086.197401000-00009.
- [6] “Herring JA, Sucato DJ. Developmental dysplasia of the hip. In: Herring JA, ed. *Tachdjian’s Pediatric Orthopaedics*. 4th ed. Philadelphia: Saunders Elsevier, 2008:677.
- [7] “Rachbauer F, Kain MS, Leunig M. The history of the anterior approach to the hip. *Orthop Clin North Am* 2009;40:311-20.
- [8] “Kitoh H, Kaneko H, Ishiguro N. Radiographic analysis of movements of the acetabulum and the femoral head after Salter innominate osteotomy. *J Pediatr Orthop* 2009;29:879-84. doi:10.1097/bpo.0b013e3181c1e314
- [9] “Severin E. Contribution to knowledge of congenital dislocation of hip joint: late results of closed reduction and arthrographic studies of recent cases. *Acta Chir Scand* 1941; 84 (Suppl 63): 1-142.
- [10] “Mckay DW. A comparison of the innominate and the pericapsular osteotomy in the treatment of congenital dislocation of the hip. *Clin Orthop Relat Res* 1974; 98: 124-132. doi: 10.1097/00003.086.197401000-00013.
- [11] “Salter RB, Kostuik J, Dallas S. Avascular necrosis of the femoral head as a complication of treatment for congenital dislocation of the hip in young children: a clinical and experimental investigation. *Can J Surg* 1969; 12: 44-61.
- [12] “Kalamchi A, MacEwen GD. Avascular necrosis following treatment of congenital dislocation of the hip. *J Bone Joint Surg Am* 1980; 62: 876-88.
- [13] “Köroğlu C, Özdemir E, Çolak M, Şensöz E, Öztuna FV. Open reduction and Salter innominate osteotomy combined with femoral osteotomy in the treatment of developmental dysplasia of the hip: Comparison of results before and after the age of 4 years. *Acta Orthop Traumatol Turc* 2021;55:28-32. doi: 10.5152/j.aott.2021.17385.
- [14] “Abdullah ES, Razzak MY, Hussein HT, El-Adwar KL, Abdel-Razek Youssef A. Evaluation of the results of operative treatment of hip dysplasia in children after the walking age. *Alexandria J Med* 2012;48:115-22
- [15] “Erturk C, Altay MA, Yarimpapuc R, Koruk I, Isikan UE. One-stage treatment of developmental dysplasia of the hip in untreated children from two to five years old A comparative study. *Acta Orthop Belg* 2011;77:464-71.
- [16] “Barrett WP, Staheli LT, Chew DE. The effectiveness of the Salter innominate osteotomy in the treatment of congenital dislocation of the hip. *J Bone Joint Surg Am* 1986;68:79-87. doi: 10.2106/00004.623.198668010-00010.
- [17] “Gülman B, Tuncay IC, Dabak N, Karaismailoglu N. Salter’s innominate osteotomy in the treatment of congenital hip dislocation: A long term review. *J Pediatr Orthop* 1994; 14: 662-6. doi: 10.1097/01241.398.199409000-00021.
- [18] “Vengust R, Antolic V, Srakar F. Salter osteotomy for treatment of acetabular dysplasia in developmental dysplasia of the hip in patients under 10 years. *J Pediatr Orthop B* 2001;10:30-6.
- [19] “Utterback TD, MacEwen GD. Comparison of pelvic osteotomies for the surgical correction of the congenital hip. *Clin Orthop Relat Res* 1974;98:104-10. doi: 10.1097/00003.086.197401000-00010.