

MULTIPLE FRACTURES IN A SINGLE UPPER EXTREMITY: HUMERAL SHAFT, OLECRANON, DISTAL RADIUS AND FOURTH METACARPAL BONE FRACTURES IN AN ELDERLY PATIENT AFTER A FALL: A CASE REPORT

BASİT DÜŞME SONRASI YAŞLI HASTADA AYNI TARAF EKSTREMİTEDE MULTİPL KIRIK;
HUMERUS ŞAFT, OLEKRANON, DİSTAL RADIUS VE DÖRDÜNCÜ METAKARPAL KEMİK
KIRIĞI-OLGU SUNUMU

Serkan BAYRAM¹ , Lezgin MERT¹ , Mehmet EKİNCİ¹ , Turgut AKGÜL¹ , İrfan ÖZTÜRK¹ 

¹Istanbul University, Istanbul Faculty of Medicine, Department of Orthopedics and Traumatology, Istanbul, Turkey

ORCID IDs of the authors: S.B. 0000-0001-7651-1200; L.M. 0000-0003-3602-6694; M.E. 0000-0001-7337-3615; T.A. 0000-0002-0704-3797; İ.Ö. 0000-0002-3504-3479

Cite this article as: Bayram S, Mert L, Ekinci M, Akgul T, Ozturk I. Multiple fractures in a single upper extremity: humeral shaft, olecranon, distal radius and fourth metacarpal bone fractures in an elderly patient after a fall: a case report. J Ist Faculty Med 2021;84(3):443-7. doi: 10.26650/IUITFD.2020.0088

ABSTRACT

Floating limb is a complicated injury and is associated with limb deformation and increased morbidity and mortality. We report a rare case of a floating upper limb in a 77-year old woman with ipsilateral humeral shaft, olecranon, distal radial and metacarpal bone fractures after a simple fall. The patient underwent surgery for humerus shaft, olecranon, and distal radius and was treated surgically with the 4th metacarpal conservative method. At the final follow-up 3 years after surgery, the patient had no complaints, all fracture had healed completely and elbow-wrist range of motion was complete. We discuss the surgical procedures that we used for the fractures, the mechanism of injury and the functional and radiological results. Multiple bone fractures in the same limb are rare and typically associated with high-trauma. We reported a unique case of an elderly patient with osteoporosis having multiple fractures in the same extremity that occurred as a result of low-energy trauma.

Keywords: Multiple bone fractures, osteoporotic bone, floating limb

ÖZET

Yüzen ekstremitte ile sonuçlanan yaralanmalar kompleks, ciddi sakatlıklara neden olabilen ve morbidite-mortalite riski yüksek olan yaralanmalardır. Bu olguda basit bir düşme sonucu aynı tarafta humerus şaft, olekranon, radius alt uç ve dördüncü metakarpal kemik kırıkları olan, 77 yaşında bir kadın hastada nadir görülen yüzen bir üst ekstremitte olgusunu sunmayı amaçladık. Humerus şaft, olekranon ve radius alt uç kırıkları ameliyat ile metakarp kırığı konservatif metot ile tedavi edildi. Hastanın ameliyat sonrası 3. yıl takibinde, ek şikayeti olmadığı, kırıkları tamamen iyileştiği ve dirsek, el bileği hareket açıklıklarının tam olduğu saptandı. Bu olgu da kırıklar için kullandığımız cerrahi teknikleri, yaralanma mekanizmasını ve fonksiyonel ve radyolojik sonuçları sunduk. Aynı uzuvdaki çoklu kemik kırıkları nadirdir ve tipik olarak yüksek enerjili bir travma ile ilişkilidir. Bu olgumuzda literatürde çok nadir bildirilen düşük enerjili bir travma sonucu gelişen aynı taraf ekstremitte birden fazla kırığı olan osteoporozlu hastayı sunduk.

Anahtar Kelimeler: çoklu kemik kırığı, osteoporotik kemik, yüzen ekstremitte

Corresponding author/İletişim kurulacak yazar: dr.serkanbayram89@gmail.com

Submitted/Başvuru: 18.07.2020 • **Revision Requested/Revizyon Talebi:** 01.10.2020 •

Last Revision Received/Son Revizyon: 20.11.2020 • **Accepted/Kabul:** 12.12.2020 • **Published Online/Online Yayın:** 31.05.2021



Content of this journal is licensed under a Creative Commons Attribution-NonCommercial 4.0 International License.

INTRODUCTION

Humeral shaft fractures are common in elderly patients with low-energy trauma and account for 3%–5% of all fractures in adults (1). Although olecranon and distal radius fractures are most commonly observed in elderly patients, concurrent ipsilateral olecranon and distal radius fractures are extremely rare.

Concurrent ipsilateral fractures of the humeral shaft and forearm result in a so-called floating elbow. There are relatively few case reports in the literature on ipsilateral olecranon fractures associated with distal radius fractures, the so-called floating forearm injury, and these pertain to paediatric cases.

Herein, we describe the case of a 77-year-old woman who had a combination of the aforementioned injuries in the ipsilateral limb. To the best of our knowledge, this is the first case report of a combined floating elbow and floating forearm injury in the same limb in an elderly patient. Written informed consent was obtained from the patient for publication of this case report and accompanying images.

CASE REPORT

A 77-year-old woman was admitted to our emergency department following a fall from one stair step. She

complained of pain in her right upper extremity. Physical examination revealed a deformity in the arm and wrist. There was tenderness with palpation of the humeral shaft, olecranon, distal radius and fourth metacarpal bone. The neurovascular and radial nerve examinations were normal, and there was no other extremity trauma. She had hypertension and osteoporosis. The T-score detected at the lumbar vertebra was -2.7 .

Radiological assessment included antero-posterior (AP)–lateral radiograph of the right humerus, elbow, wrist and AP and lateral and oblique radiograph of hand and confirmed the diagnosis of the right humeral shaft, olecranon, distal radius and fourth metacarpal bone fractures (Figure 1). All fractures were closed. According to the AO Fracture and Dislocation Classification, the humeral shaft fracture was AO 1-2-A2, the olecranon fracture was 2-1-B1, the distal radius fracture was 2-3-A2 and the fourth metacarpal fracture was a neck fracture. Surgical treatment was planned for the humeral shaft, olecranon and distal radius fractures, and conservative treatment was planned for the fourth metacarpal fracture. The patient's right upper extremity was splinted extending from the tip of the shoulder to the fingertips.

SURGICAL TECHNIQUE

First, the patient underwent open reduction for the humeral shaft fracture with an anterolateral approach un-

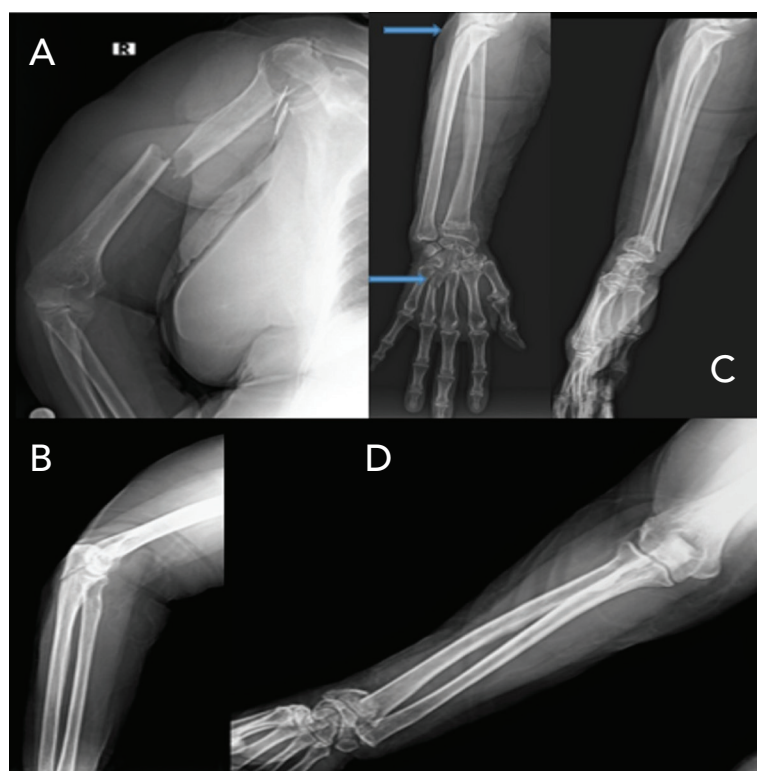


Figure 1: Humeral shaft (A), olecranon (B), distal radius (D) and fourth metacarpal bone (C) fractures in the same upper limb.

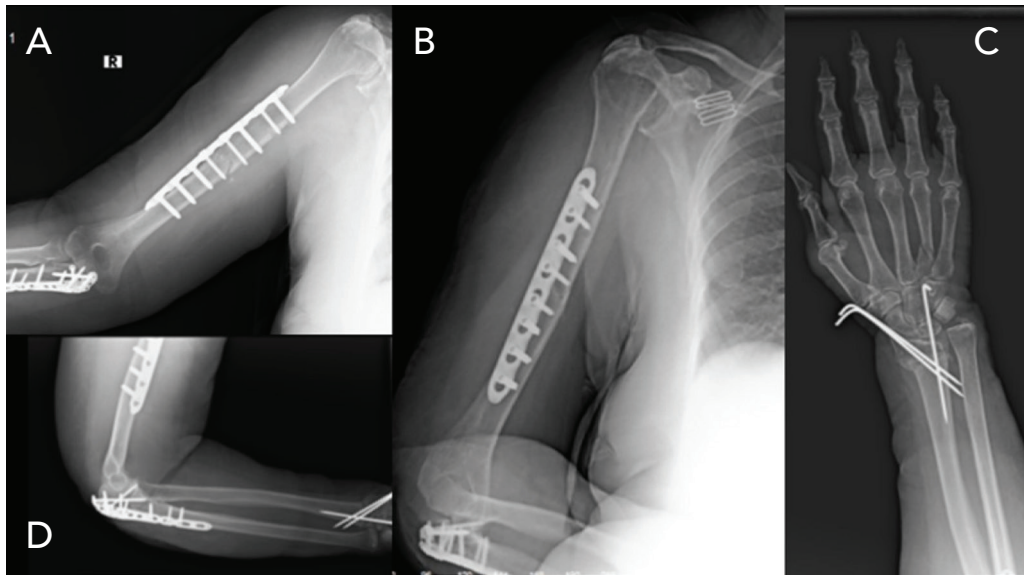


Figure 2: Humeral shaft and olecranon fractures were surgically treated using anatomical locking plates (A, B, D), and the distal radius fracture was treated via closed reduction using two percutaneous Kirschner wires (C)

der general anaesthesia, and an anatomical locking plate was applied. Thereafter, she underwent surgery for the olecranon fracture with a posterior approach, and an anatomical locking plate was applied. Finally, she underwent closed reduction for the distal radius fracture with percutaneous Kirschner (K) wire fixation. Reduction was stabilised using two K wires (Figure 2). An arm sling and a short forearm splint were used postoperatively for the metacarpal fracture. Elbow range of motion (ROM) exercises were initiated after one week of arm-sling usage.

The patient postoperatively developed radial nerve palsy symptoms with difficulty in straightening her wrist and fingers. The forearm splint was removed, and the patient began to use a radial nerve splint after two weeks and take pregabalin orally 75 mg twice a day and B-12 vitamin pills once a day.

At the 6th week postoperatively, the distal radius and the fourth metacarpal bone were healed radial nerve symptoms were not completely recovered; thus, the use of the radial nerve splint and pregabalin administration were continued. At the 3-month follow-up, radial nerve palsy symptoms were completely resolved, and the splint and medications were discontinued. The patient achieved an elbow ROM of 20°–100°.

At the final follow-up three years after surgery, the patient had no complaints regarding fracture healing (Figure 3). She had an elbow ROM of 10°–130°, wrist joint ROM of 45° of dorsiflexion and 45° of *volar flexion* and full pronation and supination (Figure 4).

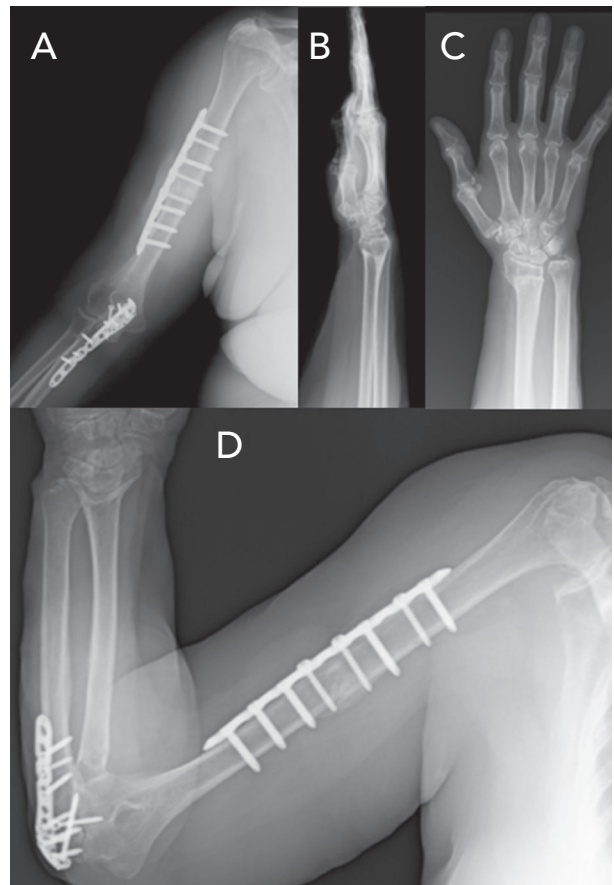


Figure 3: A, D: Humeral and olecranon, B: distal radius and C: 4th metacarpal bone fracture were successfully treated

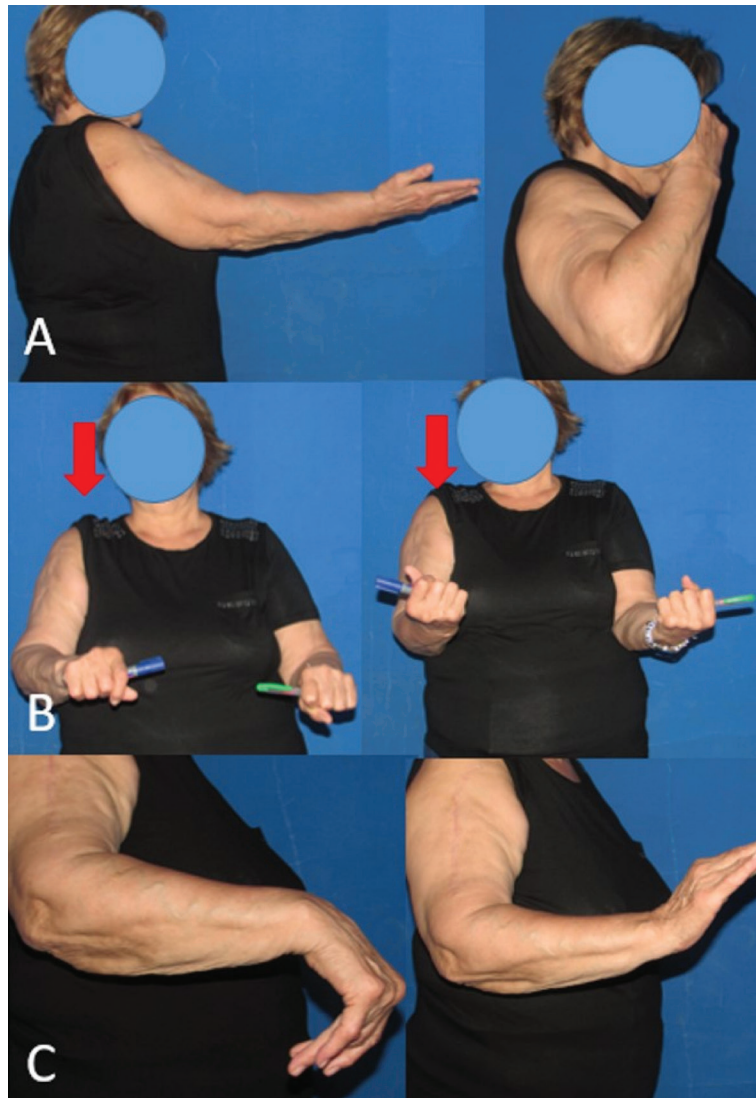


Figure 4: The patient's elbow (A), forearm rotation (B) and wrist joint (C) range of motion

DISCUSSION

'Floating elbow' is a term used to describe a combination of ipsilateral forearm and humeral fractures (2). The term 'floating forearm' describes a combination of ipsilateral proximal and distal forearm fractures (3); these injuries are extremely rare. This case, which describes a combination of an ipsilateral floating elbow and a floating forearm in an elderly patient after an injury that resulted from a fall from one stair, is very rare.

Humeral shaft, olecranon and distal radius fractures are very common injuries by themselves, but the simultaneous occurrence of these fractures after a fall from one stair step is unusual. We hypothesise that the mechanism of this injury was an outstretched arm with the forearm pronated and wrist hyperextended. This mechanism would

explain the olecranon and distal radius fractures, whereas the humeral and fourth metacarpal fractures may be explained by direct trauma from the edge of the stairs.

Multiple fractures in the concurrent limb usually require a high-energy trauma. However, in our case, these fractures resulted from a low-energy trauma most likely due to osteoporosis. Patients with multiple fractures carry a higher risk of developing neurovascular injuries, compartment syndrome and open fractures than that of patients with isolated fractures (4-6). Unfortunately, there is no consensus in the literature on the order of treatment in the upper limb in the event of multiple fractures. In our case, surgery was initiated for the most severely deformed fracture, the humeral shaft fracture. After the humeral fracture was reduced and fixed, the reduction of the olecranon and distal radius fractures was easier.

CONCLUSION

One of the important messages here is that multiple bone fractures in the same limb are can occur after a simple fall especially in elderly patients with osteoporosis. So, elderly patients should be evaluated with complete and thorough examination and obtain the appropriate x-rays to rule out the occurrence of more injuries in the same limb or other body parts. These fractures can be treated conservatively when they occur separately, however, multiple fractures in the same limb, such as a floating limb, should be treated surgically.

Informed Consent: Written consent was obtained from the participants.

Peer Review: Externally peer-reviewed.

Author Contributions: Conception/Design of Study- S.B., L.M.; Data Acquisition- S.B., L.M.; Data Analysis/Interpretation- S.B., M.E., T.A., İ.Ö.; Drafting Manuscript- S.B.; Critical Revision of Manuscript- M.E., T.A., S.B.; Final Approval and Accountability- S.B., L.M., M.E., T.A., İ.Ö.

Conflict of Interest: Authors declared no conflict of interest.

Financial Disclosure: Authors declared no financial support.

Bilgilendirilmiş Onam: Katılımcılardan bilgilendirilmiş onam alınmıştır.

Hakem Değerlendirmesi: Dış bağımsız.

Yazar Katkıları: Çalışma Konsepti/Tasarım- S.B., L.M.; Veri Toplama- S.B., L.M.; Veri Analizi/Yorumlama- S.B., M.E., T.A., İ.Ö.; Yazı Taslağı- S.B.; İçeriğin Eleştirel İncelemesi- M.E., T.A., S.B.; Son Onay ve Sorumluluk- S.B., L.M., M.E., T.A., İ.Ö.

Çıkar Çatışması: Yazarlar çıkar çatışması beyan etmemişlerdir.

Finansal Destek: Yazarlar finansal destek beyan etmemişlerdir.

REFERENCES

1. Tytherleigh-Strong G, Walls N, McQueen MM. The epidemiology of humeral shaft fractures. *J Bone Joint Surg Br* 1998;80(2):249-53. [\[CrossRef\]](#)
2. Harrington P, Sharif I, Fogarty EE, Dowling FE, Moore DP. Management of the floating elbow injury in children: simultaneous ipsilateral fractures of the elbow and forearm. *Arch Orthop Trauma Surg* 2000;120(3-4):205-8. [\[CrossRef\]](#)
3. Jupiter JB, Kour AK, Richards RR, Nathan J, Meinhard B. The floating radius in bipolar fracture-dislocation of the forearm. *J Orthop Trauma* 1994;8(2):99-106. [\[CrossRef\]](#)
4. Dhoju D, Sherestha D, Parajuli N, Dhakal G, Sherestha R. Ipsilateral supracondylar fracture and forearm bone injury in children: a retrospective review of thirty one cases. *Kathmandu Univ Med J* 2011;9(2):11-6. [\[CrossRef\]](#)
5. Abutalib RA, Khoshhal KI. Multiple concomitant injuries in one upper extremity: a case report. *Am J Case Rep* 2016;17:6-11. [\[CrossRef\]](#)
6. Mana'an Q, Bashir A, Zahoor A, Mokhdomi TA, Danish Q. The floating upper limb: multiple injuries involving ipsilateral, proximal, humeral, supracondylar, and distal radial limb. *Clin Orthop Surg* 2016;8(3):345-8. [\[CrossRef\]](#)