



Clinical outcome of superior plate fixation for midshaft clavicular fractures

Metin UZUN

Department Orthopedics and Travmatology, Specialist Sports Medicine-Foot and Ankle Surgery, Mehmet Ali Aydınlar Acıbadem University, İstanbul, Turkey

Received: 06.06.2021

Accepted/Published Online: 14.10.2021

Final Version: 18.03.2022

Abstract

The middle clavicle fractures in both anatomy and position upon evaluation are considered displaced or unstable especially for those with high expectations for recreational activity. Although surgical treatment is recommended as the standard treatment modality for middle displaced fractures, there is no consensus about the type of operative treatment. 25 patients that diagnosed with middle clavicle fractures, who underwent surgery for displaced clavicle fractures. Surgical treatment was done with clavicle anatomic locked plate at all cases. The mean follow-up period was 24 months (range, 12–40 months). Bony union was achieved at a mean follow-up of 8 weeks (range 6-10 weeks). The mean Constant score was 97 (range, 92-100). There were no complications. The anatomical superior plate application were provides anatomical healing without shortening; allow the early movement by increasing the stability.

Keywords: middle clavicle, fracture, surgery, anatomic healing, early activity, sports medicine

1. Introduction

Clavicle fractures are most common in the middle 1/3 region (1). Middle age men are more affected and the most common mechanism of injury is a car accident or falling directly on it. Most of these fractures are displaced due to muscle action and weight of the arm (1).

Previously, conservative treatment with arm sling and figure-of-8 bandage was at the forefront; Recently, Surgery has become more popular due to the complications that occur due to conservative treatment as a painful nonunion, cosmetic reasons, scapulothoracic joint pain or disturbance and the patients' desire to return to work earlier.

In our study, we aimed to discuss the results of middle 1/3 fractures treated with a single anatomical locking plate screw system.

2. Materials and Methods

We prospectively reviewed 25 patients diagnosed with middle clavicle fractures who underwent surgery for displaced middle 1/3 fractures according to X-ray examination from March 2009 to May 2020 (Fig. 1). The average patient age was 38 years (range 24-52 years). 20 patients were male and rest of 5 patients were female; the right clavicle was injured in 19 patients whereas the left clavicle was injured in 6 cases. Only patients with acute surgical treatment (within 3 weeks of injury) with an anatomic clavicle locked plate and at least 1 year of follow-up were included in the study.

The average time from injury to surgery was 3 days (range, 1–7 days). The mean follow-up period was 24 months

(range, 12–40 months). Eleven patients were injured in a cycling accident, four patients were injured in the ski, and five were injured falling off a horse, five were injured playing soccer. All participants were informed and informed consent form was obtained. Study was approved by our Institutional Review Board. Surgical procedures were performed under general anesthesia with the patient in the beach-chair position. A standard superior approach to the clavicle was used. After identification of the fracture site, all hematoma and debris were curetted and interposed soft tissue was removed. An anatomic clavicle plate was applied. The anatomical clavicle plate was fixed with at least 3 cortex on both sides of the fracture (Fig. 2).

Postoperatively, a sling was used for 10 days. Passive range of shoulder motion began at the second day. Elevation of the arm above the shoulder was prohibited for three weeks. Functional outcome of the shoulder was evaluated using a Constant scoring system (2). Union was evaluated radiologically.

3. Results

Bony union was achieved at a mean follow-up of 8 weeks (range 6-10 weeks) (Fig. 3). The mean Constant score was 97 (range, 92-100). There were no complications, such as deep infection, nonunion or malunion. All patients achieved satisfactory full range of shoulder motion. Implant loosening was not seen in the plate. Hardware removal was performed for prominence in ten case after the union was completed (Fig. 4).

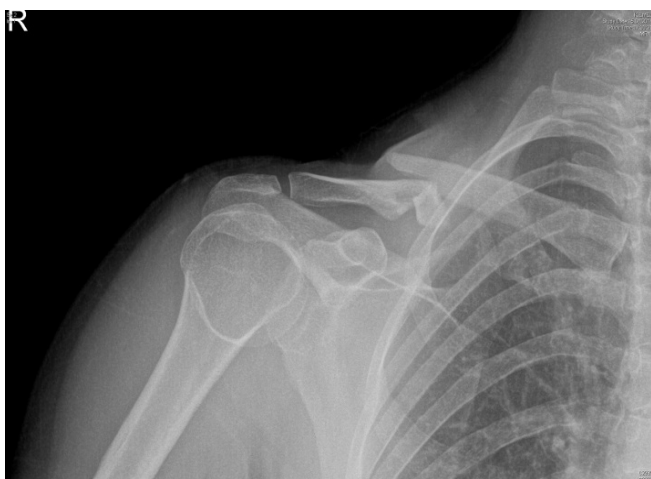

Fig. 1. 42 years woman's shoulder AP x-ray image showing that clavicle comminuted fracture

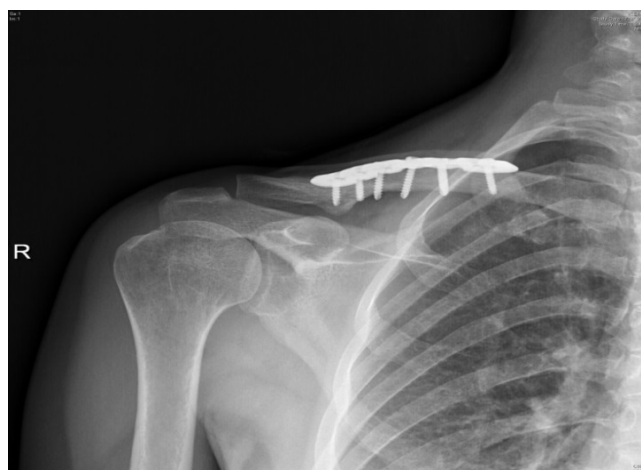

Fig. 3. 42 year's woman's follow-up shoulder AP x-ray image showing that achieved union clavicle comminuted fracture

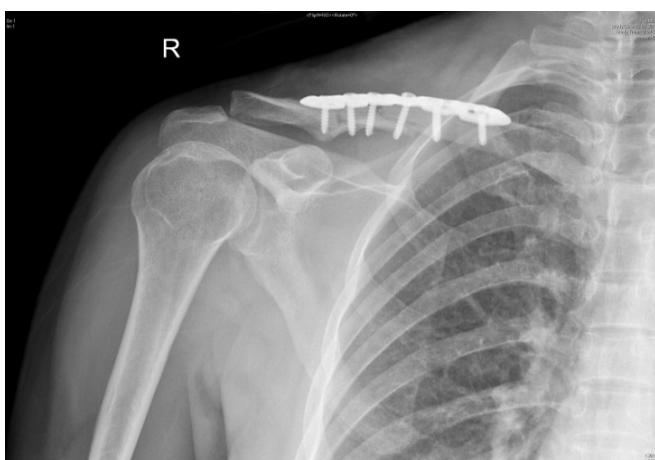


Fig. 2. 42 years woman's postoperative shoulder AP x-ray image showing that clavicle comminuted fracture that fixed anatomic plate

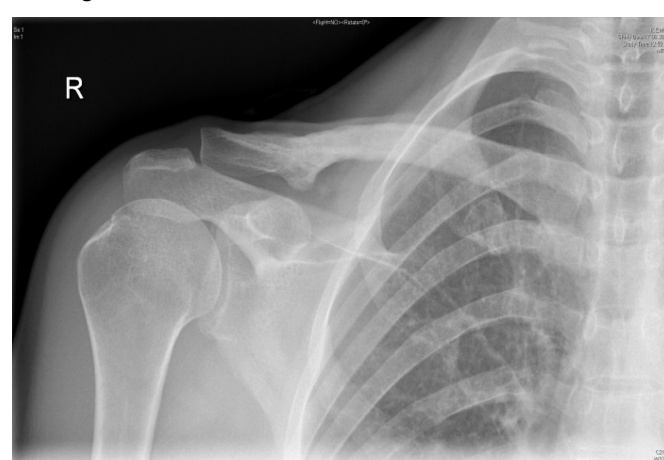

Fig. 4. 42 year's woman's follow-up shoulder AP x-ray image showing that achieved union clavicle comminuted fracture after the implant is removed

4. Discussion

Most of clavicle fractures are displaced due to muscular action and weight of the arm. Although many studies also suggest open reduction and fixation in the treatment of displaced mid-diaphyseal fractures, particularly those with 20 mm shortening, 100% displacement and bone defect (1). Conservative treatment of these displaced fractures may result in shortening, malunion, painfully nonunion, poor shoulder function, cosmetic problem. In a comparative study between surgically treated and conservatively treated displaced mid-diaphyseal fractures, high functional outcomes, low nonunion and malunion results were found in patients treated surgically (3). Thus, surgical treatment has been the first choice to avoid these problems and due to the high expectations of the patients; but ideal surgical treatment continues to be controversial (3-6). The main issue regarding surgical treatment of middle fractures is union and return to previous daily activities. Herein, we evaluated union, complications and results in a case series of patients treated with an anatomic plate.

The middle clavicle fractures in both anatomy and position upon evaluation; the distal fragment is located in the posterior-inferior position due to attachment of the deltoid

and trapezius; the proximal fragment is both superior and anterior due to the sternocleidomastoid and pectoralis major muscles (2). Although this muscle is able to function, it is difficult to open between the fractured fragments and results in a gap, causing the union issue. In some fractures, the fracture line will have multi fragments. Based on the literature, there are many surgical options for treatment of displaced clavicle fractures due to the union problem, including anatomic locking plates, double plates, intramedullary nail (4, 7-10). Despite the numerous techniques available, none method has proven superior for the union rates; but reconstruction plates had very high implant failure rate compared the non-reconstruction plates (8, 11). In this reason, we only preferred the anatomical locking plate screw osteosynthesis option. Plates with different number of holes and different number of screws were used related the type of fracture and length of the clavicle.

Upon examination of the history of surgical treatments, nonlocking plate system were used. However, with technological developments, locking plate technology has proven beneficial in fracture treatment with poor bone quality, as well as for short segments and allowed the early movement (5, 6). This is especially important if the medial or

lateral fragment is small or osteopenia due to comminuted. Although, many authors reported that use of double plate provided sufficiently stable fixation for comminuted fracture or requesting early movement; Denise reported to return to professional athletic activity with treated anteroinferior plate at 2 weeks after surgery (7). As many authors have stated, we preferred a single plate application.

Despite the good stability, compression and mechanical fixation with plate fixation, complications such as infection and formation of scar tissue were found 6. Although the clavicle fixation as an intramedullary is cosmetically acceptable, complications rates of up to 75% were reported, namely lack of rotational control, the need for a second surgical procedure to remove the implant, skin problems, and implant migration and shortening due to comminuted (12). Therefore, plate fixation is the preferred treatment in our hospital. Optimal plate fixation for the treatment of mid-diaphyseal clavicle fracture is still controversial. Some studies suggest that anteroinferior plate fixation techniques are better, suggesting that plate prominence is felt less often. However, more soft tissue dissection is required for this plate fixation 4. Therefore, a high rate of wound infection or wound healing can be expected complications. The other point is the subclavian artery in the medial half of the clavicle was the closest to the posterior cortex (13). So that anteroinferior plate application can cause neurovascular injury in the medial clavicular area. In order to prevent this complication, we preferred superior plate application by taking the risk of skin irritation. Although clinically, plate prominence inferiority due to low profile of anatomically compatible plate in mid-diaphyseal clavicle fractures is low; all of our patients complained the plate prominence (12). We also think that the use of preformed anatomically compatible plates in our study reduces the duration of surgery and plate tiredness risk.

In a study conducted biomechanically, the anterior, antero-superior, and superior plating types were found to be the most important method for detecting axial fracture of superior plate in the detection of midshaft clavicle fractures. In the same study, no difference was found between torsional forces and resistance among all three types of plate fixation 5.

We believe we have achieved successful results on the fixation of the fracture with our superior plate fixation and with an early activity program applied to all patients

Complications such as shortening, painful nonunion, cosmetic disorder and excessive callus formation can be observed as a result of displaced or comminuted midshaft clavicle fractures. It is possible to obtain complete union with high patient satisfaction by avoiding the complications with anatomically compatible low profile locking plates.

Acknowledgements

None.

Funding

No found has been received.

Conflicts of Interest

Authors, their immediate family, and any research foundation with which they are affiliated did not receive any financial payments or other benefits from any commercial entity related to the subject of this article.

References

- Ramponi DR, Jo Cerepani M. Clavicle Fractures. *Adv Emerg Nurs J* 2021;43(2):123-127. doi: 10.1097/tme.0000000000000347.
- Robinson L, Persico F, Lorenz E, Seligson D. Clavicular caution: an anatomic study of neurovascular structures. *Injury* 2014;45(12):1867-9. doi: 10.1016/j.injury.2014.08.031.
- Smekal V, Irenberger A, Struve P, Wambacher M, Krappinger D, Kralinger FS. Elastic stable intramedullary nailing versus nonoperative treatment of displaced midshaft clavicular fractures-a randomized, controlled, clinical trial. *J Orthop Trauma* 2009;23(2):106-12. doi: 10.1097/BOT.0b013e318190cf88.
- Huang TL, Chen WC, Lin KJ, Tsai CL, Lin KP, Wei HW. Conceptual finite element study for comparison among superior, anterior, and spiral clavicle plate fixations for midshaft clavicle fracture. *Med Eng Phys* 2016;38(10):1070-5. doi: 10.1016/j.medengphy.2016.06.021.
- Kilinc BE, Oc Y, Erturer RE. Treatment of Midshaft Clavicle Fracture with Superior Plate Placement. *Acta Ortop Bras* 2020;28(2):88-91. doi: 10.1590/1413-785220202802226166.
- Rieser GR, Edwards K, Gould GC, Markert RJ, Goswami T, Rubino LJ. Distal-third clavicle fracture fixation: a biomechanical evaluation of fixation. *J Shoulder Elbow Surg* 2013;22(6):848-55. doi: 10.1016/j.jse.2012.08.022.
- Boyce GN, Philpott AJ, Ackland DC, Ek ET. Single versus dual orthogonal plating for comminuted midshaft clavicle fractures: a biomechanics study. *J Orthop Surg Res* 2020;15(1):248. doi: 10.1186/s13018-020-01771-x.
- Chiu YC, Huang KC, Shih CM, Lee KT, Chen KH, Hsu CE. Comparison of implant failure rates of different plates for midshaft clavicular fractures based on fracture classifications. *J Orthop Surg Res* 2019;14(1):220. doi: 10.1186/s13018-019-1259-x.
- Renfree T, Conrad B, Wright T. Biomechanical comparison of contemporary clavicle fixation devices. *J Hand Surg Am* 2010;35(4):639-44. doi: 10.1016/j.jhssa.2009.12.012.
- Rieser GR, Edwards K, Gould GC, Markert RJ, Goswami T, Rubino LJ. Distal-third clavicle fracture fixation: a biomechanical evaluation of fixation. *J Shoulder Elbow Surg* 2013;22(6):848-55. doi: 10.1016/j.jse.2012.08.022.
- Constant CR, Murley AH. A clinical method of functional assessment of the shoulder. *Clin Orthop Relat Res* 1987(214):160-4.
- VanBeek C, Boselli KJ, Cadet ER, Ahmad CS, Levine WN. Precontoured plating of clavicle fractures: decreased hardware-related complications? *Clin Orthop Relat Res* 2011;469(12):3337-43. doi: 10.1007/s11999-011-1868-0.
- Lo EY, Eastman J, Tseng S, Lee MA, Yoo BJ. Neurovascular risks of anteroinferior clavicular plating. *Orthopedics* 2010;33(1):21. doi: 10.3928/01477447-20091124-09.