

# Medically Treated Emphysematous Gastritis in a Patient with Rheumatoid Arthritis: Report of Case

Cemal Ulusoy<sup>1</sup>, Andrej Nikolovski<sup>2</sup>, Tuba Saydam<sup>1</sup>

<sup>1</sup>Department of general surgery, Prof. Dr. Cemil Taşçıoğlu Şehir Hastanesi, Istanbul, Turkey

<sup>2</sup>Department of visceral surgery, University Surgery Clinic "Sv. Naum Ohridski", Skopje, N. Macedonia

## Abstract

Emphysematous gastritis is rare infection of the gastric wall associated with high mortality. Damage of the gastric mucosal barrier and bacterial translocation can lead to emphysematous gastritis. Non-steroidal anti-inflammatory drugs use is one of the etiological factors. Due to the high mortality rates, early diagnosis and treatment is important. Patients are presenting to emergency departments generally with non-specific acute abdominal signs. We present a case of an 82 years old patient with rheumatoid arthritis treated with non-steroidal anti-inflammatory drug that presented to the emergency department with diffuse abdominal pain, nausea and vomiting. After establishing the diagnosis, conservative treatment was conducted with success.

**Key Words:** emphysematous gastritis, medical treatment, rheumatoid arthritis.

## Introduction

Emphysematous gastritis (EG) is characterized by presence of gas in the gastric wall and is different condition from the benign gastric emphysema. A gas-producing bacterial infection of the gastric wall is in its essence. EG has a reported mortality rate of 50 - 60%<sup>1,2</sup>. Clinically is presented with acute onset of diffuse abdominal pain, nausea, vomiting and shock in some cases<sup>3</sup>. The diagnosis is feasible by radiological tools. The recommended initial treatment is conservative and surgery is advised in cases of deterioration or in cases of gastric mucosal necrosis and perforation<sup>3,4</sup>. Upper gastrointestinal endoscopy can help in the choice of the initial treatment. Presence of early ischemic signs and absence of necrotic mucosa can be the indication for medical treatment. Computerized tomography findings and images are available in the literature but there is limited number of cases with upper endoscopy images of EG. We present a case of medically treated EG in patient with rheumatoid arthritis and his endoscopic findings.

## Case Report

An 82 years old patient was admitted to our emergency department with nausea, vomiting and abdominal pain. The medical history revealed regulated hypertension and rheumatoid arthritis with impaired mobility of the lower limbs. The patient was using non-specific non-steroidal anti-inflammatory drug (NSAID). At the same time, he reported

absence of regular follow-up on NSAID usage. His vital signs indicated a blood pressure of 145/90 mmHg, heart rate of 117 bpm and body temperature of 37.8°C. The abdominal examination demonstrated intense pain upon pressure in the epigastrium and rebound tenderness with abdominal guarding. Blood test results indicated White Cell Blood count of 18.070 U/ $\mu$ L, Neutrophil count of 95%, serum C-Reactive Protein value of 145.76 mg/L, serum Sodium value of 133 mEq/L and serum Potassium value of 6.54 mEq/L. Results from arterial blood gas analysis were: pH 7.29, HCO<sub>3</sub> 18.3 mEq/L, PaO<sub>2</sub> 30.5 mmHg and PaCO<sub>2</sub> 38.9 mmHg.

On the abdominal topogram we noticed intramural gas at the great curvature of the stomach spreading toward the esophageal wall (Figure 1). Air in the portal venous system and gas in the gastric wall was seen in the abdominal computerized tomography (CT) scans (Figure 2). Upper gastrointestinal endoscopy was performed next. The endoscopic examination showed ischemic signs of the gastric mucosa (Figure 3). According to the last finding, the decision for medical treatment was adopted.

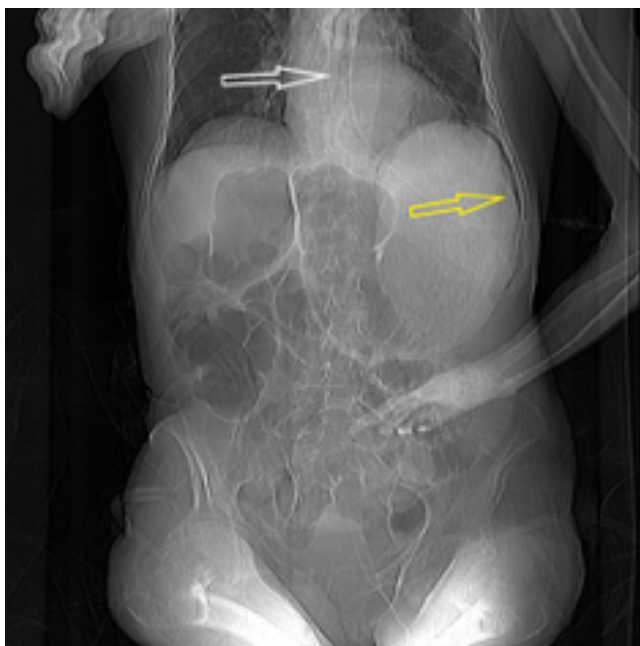The patient was admitted to intensive care unit. Oral intake was stopped, fluid and serum electrolytes were replaced and total parenteral nutrition was introduced. After consulting the department of Infectious diseases, a broad-spectrum antibiotic (Ceftriaxone 2x1g intravenously) and anaerobic antimicrobial agent (Metronidazole 3x500 mg intravenously) were administered. One week from the conservative treatment initiation, abdominal symptoms subsided gradually and the patient was transferred to the hospital ward. Oral intake was allowed. On day 15 from the admission, CT scan and upper endoscopy were repeated. Noticeable improve-

**Corresponding Author:** Andrej Nikolovski **e-mail:** andrejnikolovski05@gmail.com

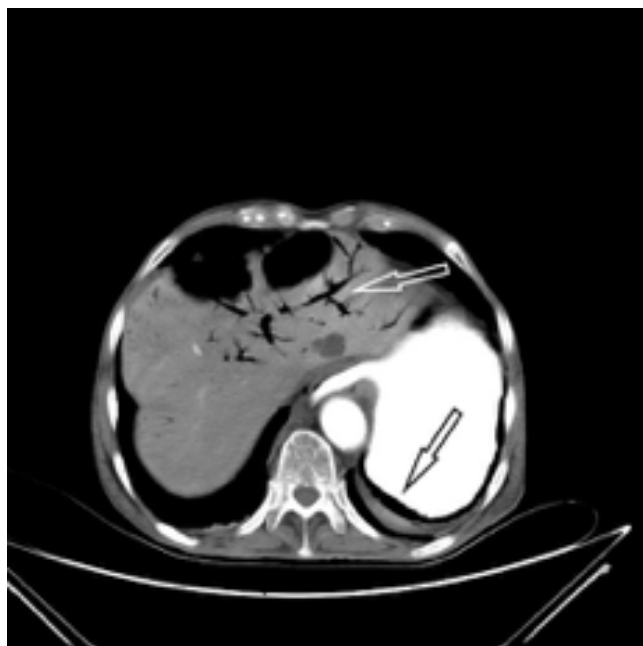
**Received:** 08.06.2021 • **Accepted:** 29.06.2021

**DOI:** 10.33706/jemcr.949264

©Copyright 2020 by Emergency Physicians Association of Turkey - Available online at [www.jemcr.com](http://www.jemcr.com)



**Figure 1:** Plain abdominal X-ray finding - gas in the gastric (yellow arrow) and esophageal wall (white arrow)



**Figure 2:** Axial CT scan of portal venous air (white arrow) and in the gastric wall (black arrow)

ment was seen. Blood tests normalized. The patient was discharged from the hospital on day 20.

## Discussion

Emphysematous gastritis is very rare and potentially lethal infection of the gastric wall. It should be differentiated from the gastric emphysema since their symptoms, findings, treatment and prognosis differ. Alcohol abuse, gastric surgery, recent gastroenteritis, corrosive ingestion, chronic consumption of NSAIDs/steroids, diabetes mellitus, chronic obstructive pulmonary disease, immunosuppression and trauma are reported

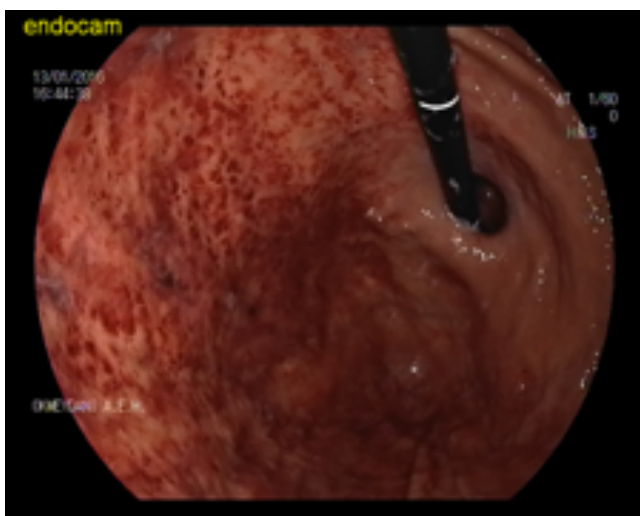as predisposing factors<sup>1</sup>. This multifactorial damage of the gastric mucosal barrier and bacterial translocation can cause emphysematous gastritis. Streptococci, Enterobacteriaceae, Esherichia Coli, Clostridium Welchii, Staphylococcus Aureus and Candida Albicans are reported to be isolated<sup>5,6</sup>.

Watson et al. report mortality rate of 59.1% and exploratory laparotomy rates of 62.5% before the year of 2000. After 2000 mortality is reported to be 33.3% and exploratory laparotomy rate of 22.2%. Early diagnosis of EG lowered the laparotomy rates and decreased mortality significantly<sup>7</sup>.

Patients with EG can be asymptomatic or can present with fever, nausea, vomiting, abdominal pain and hematemesis<sup>8</sup>.

Physical examination, radiology diagnostics and upper gastrointestinal endoscopy allow proper and timely diagnosis. Abdominal pain, nausea, vomiting are the most common symptoms. On physical examination, peritoneal signs can be ascertainable. X-ray and CT characteristic findings are intramural gas in gastric wall and air in the portal venous system<sup>5</sup>. Upper gastrointestinal endoscopic examination findings associated with EG are: ulcers, necrosis, perforation and mucosal erosion<sup>8</sup>.

The initial treatment of EG (if perforation is excluded) is advised to be medical<sup>9</sup>. However, the treatment should be individualized due to the patient's condition. Surgery is recommended in cases of clinical deterioration, positive peritoneal signs, suspicion for necrosis or failure of the medical treatment<sup>8</sup>.



**Figure 3:** Gastroscopy finding with mucosal ischemia

## Conclusion

Uncontrolled consumption of NSAIDs in rheumatoid arthritis can cause emphysematous gastritis. These patients must be fol-

lowed carefully by clinicians and be warned about the NSAIDs use. With the help of clinical findings and abdominal computerized tomography, abdominal X-ray and endoscopic examination lead the patients evaluations and treatment of EG medically with success. Although there is no certain evidence and standard treatment regiments, emphysematous gastritis can be treated medically with broad spectrum antimicrobial agents unless there is no extensive peritoneal sepsis, ischemia and perforation.

### **Informed consent for publication**

Not taken. The case report was written in an anonymous characteristic, thus secret and detailed data about the patient is removed. Editor and reviewers can know and see these detailed data. These data are backed up by editor and by reviewers.

### **Acknowledgement**

None to declare.

### **Conflict of interests**

None to declare.

### **References**

1. Yalamanchili M, Cady W. Emphysematous gastritis in a hemodialysis patient. *South Med J*. 2003 Jan;96(1):84-8. doi: 10.1097/01.SMJ.0000048085.35271.75. PMID: 12602725.
2. S.M. Lee, G.H. Kim, D.H. Kang, T.O. Kim, G.A. Song, S. Kim. Gastrointestinal: emphysematous gastritis. *J Gastroenterol Hepatol*, 22 (2007), pp. 2036. <http://dx.doi.org/10.1111/j.1440-1746.2007.05200.x>
3. Nemaakayala DR, Rai MP, Rayamajhi S, Jafri SM. Role of Conservative Management In Emphysematous Gastritis. *BMJ Case Rep*. 2018; 2018:bcr2017222118. Published 2018 Feb 23. doi: 10.1136/bcr-2017-222118
4. Ocepek A, Skok P, Virag M, Kamenik B, Horvat M. Emphysematous gastritis -- case report and review of the literature. *Z Gastroenterol*. 2004 Aug; 42(8):735-8
5. Misro A, Sheth H. Diagnostic dilemma of gastric intramural air. *Ann R Coll Surg Engl* 2014; 96(7): e11-3. doi: 10.1308/003588414X13946184901128
6. Shipman P, Drury P. Emphysematous gastritis: case report and literature review. *Australasian Radiology*. 2001;45:64-66
7. Watson A, Bul V, Staudacher J, Carroll R, Yazici C. The predictors of mortality and secular changes in management strategies in emphysematous gastritis. *Clin Res Hepatol Gastroenterol*. 2017 Feb;41(1):e1-e7. doi: 10.1016/j.clinre.2016.02.011. Epub 2016 Jun 20. PMID: 27339595
8. Szuchmacher M, Bedford T, Sukhramwala P, Nukala M, Parikh N, Devito P. Is surgical intervention avoidable in cases of emphysematous gastritis? A case presentation and literature review. *Int J Surg Case Rep*. 2013;4(5):456-459. doi:10.1016/j.ijscr.2012.12.021
9. Paul M, John S, Menon MC, Golewale NH, Weiss SL, Murthy UK. Successful medical management of emphysematous gastritis with concomitant portal venous air: a case report. *J Med Case Rep*. 2010 May 19;4:1409