

Elastofibroma Dorsi: An Uncommon Soft Tissue Tumor

Anil Arif Olguner¹, Omer Kokacya^{2*}, Cengiz Eser¹

Abstract

Elastofibroma dorsi is a rare clinical situation mostly encountered as a non-tender solid mass in inferior margin of scapula, typically in elder women. It is accepted as a pseudotumor.

55 year-old female patient complaining from a mass in her back, painful with shoulder movement is presented. The patient was referred with a suspicion of malignant tumor. Biopsy revealed that it was elastofibroma dorsi and also computerized tomography was used for detection of dimension and depth of the mass. After surgical removal, pathology of the specimen confirmed the biopsy. Differential diagnosis, clinical findings and pathophysiology is discussed.

During the follow-up seroma was realized 10 days after surgery and it was treated by 2 punctions performed in a week. No further surgical complications occurred in postoperative period and no recurrence was observed during one year follow up. Surgical removal is essential in symptomatic patients. Seroma is the most encountered complication especially if the tumor diameter is large. In some cases, biopsy may help to rule out malignancy.

Keywords: Elastofibroma, soft tissue, pseudotumor

Introduction

Elastofibroma dorsi (ED) is an uncommon, benign, pseudotumoral lesion, predominant in elderly women (1). The tumor is non-encapsulated, hypo cellular in nature, composed of elastic fibers, fat and collagen (2). The most common affected body part is infrascapular region. While most of the patients are asymptomatic besides a palpable mass, some patients are reported to have increased discomfort with shoulder movements. Differential diagnosis includes lipomas, fibro lipomas, hemangiomas and malignant tumors. Especially, large tumors which seem to be fixed by palpation, may require biopsy prior to surgical excision

Case

A 55-year-old woman was referred to our clinic for a mass in her left infrascapular region with a suspicion of malignant tumor. She realized it 3 years ago and stated progressive enlargement during the last 6 months. There was no resting pain; however she had discomfort with shoulder movements. There were no additional medical problems, and no familial malignancy in her history. Physical examination revealed a palpable, non-tender, fixed, solid mass at her left infrascapular region, which was approximately 10×15 cm.

Thorax computerized tomography (CT scan) revealed a heterogeneous, well circumscribed, non-encapsulated mass attached to the inferior border of scapula (Figure 1). Biopsy was taken under local anesthesia in order to rule out malignant tumor. Histologic examination revealed that it was elastofibroma.

The patient was operated under general anesthesia. The surgical approach included a 10 cm oblique incision parallel to intercostal line at left inferior scapular region. Latissimus dorsi muscle was transected to reach the mass. Rubber dense, 120×110 mm light colored mass was firmly attached to chest wall posteriorly between 6th and 9th costa, reaching the inferior border of scapula. Total excision, included the periost of costal bone where the tumor was fixed. Meticulous bleeding control was performed. Suction drain was applied for 3 days and firm dressing of the wound for 1 week in order to prevent hematoma. During the follow-up seroma was realized 10 days after surgery and it was treated by 2 punctions performed in a week. No further surgical complications occurred in post-operative period and no recurrence was observed during one- year follow up.

Received: 02-02-2016, **Accepted** 23-02-2016, **Available Online** 15-03-2016

¹ Dept of Plastic, Reconstructive and Aesthetic Surgery, Cukurova University School of Medicine, Adana, Turkey

² Dept of Plastic, Reconstructive and Aesthetic Surgery, Gaziantep Dr. Ersin Arslan Training and Research Hospital, Gaziantep, Turkey

*Corresponding Author: Omer Kokacya E-mail: kokacya@yahoo.com

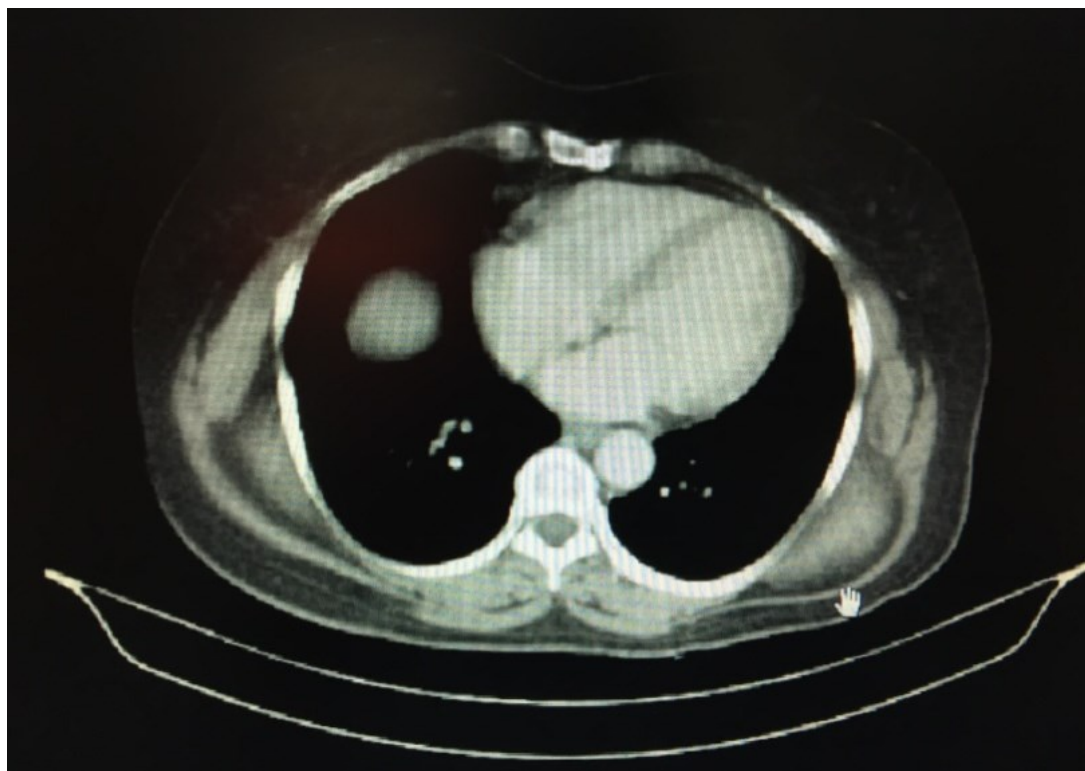


Figure 1: Thoracal CT image shows left infrascapular, well circumscribed mass, reaching chest wall.

Histologic examination of the lesion yielded a non-encapsulated excision material, circumscribed by adipose tissue and skeletal muscle streaks, rich in elastic fibers, finally diagnosed as elastofibroma consistent with prior biopsy

Discussion

Elastofibroma dorsi is a rare clinical entity which is typically seen in sixth decade of life predominantly in female patients (3). Usually it is asymptomatic and unilateral (4). However, bilateral and painful cases are also presented in the literature (5,6). Typical location is the inferior border of right scapula. Other rare locations are, forefoot, hand, breast, stomach and mediastinum (7,8). Our patient seems to carry some important characteristic properties of this clinical situation. She was 55-years-old, had a unilateral mass on her infrascapular border and it was only painful with shoulder movements. However, it was a fixed and solid lesion and the patient stated rapid growth during the last 6 months. Therefore we preferred to rule out malignancy prior to final surgery.

There are several scenarios to explain the pathogenesis of ED. Minor micro traumas due to friction between the inferior border of scapula and chest wall may cause reactive fibromatosis (9). Hypoperfusion by the enlargement of the lesion, enzyme deficiency, elastotic degeneration have also been discussed for pathogenesis (10,11).

There is a theory suggesting that the tumor arises from chest wall periosteum (12). In our case the tumor was fixed to periosteum and we had to remove it with the tumor. Another point is familial inheritance; a genetic instability in 1st chromosome has been shown to be linked with ED (13). In our case there was no family history.

Diagnostic approaches are not specific and physical examination, combined with an imaging modality such as CT or MRI would be enough. Some authors recommend fine needle aspiration biopsy, however hypo cellular nature of the lesion decreases the chance to obtain successful results (14). Therefore we preferred incisional biopsy to rule out malignancy.

In symptomatic cases, surgical excision is the recommended and sufficient treatment modality (15). Most encountered complications are seroma, hematoma and infection (16). Seroma was also detected in our case, 10 days post-operatively, resolved in a week by two punctions and drainage.

Elastofibroma dorsi should be kept in mind especially in middle-aged female patients presenting with fixed infrascapular mass. Surgical treatment is sufficient in symptomatic cases; biopsy would be useful if there is a suspicion of malignancy.

Acknowledgments: This research received no specific grant from any funding agency, commercial or not-for-profit sectors.

Conflict of Interest: The authors declare no potential conflicts of interest with respect to the research, authorship, and/or publication of this article.

References

- Ramos R, Ureña A, Macía I, Rivas F, Rius X, Armengol J. Elastofibroma dorsi: an uncommon and under-diagnosed tumour. *Arch Bronconeumol*. 2011; 47(5):262-3.
- Tsikkinis C, Balamoti S, Grigoropoulos P et al. Elastofibroma dorsi. *JBUON*. 2014; 19(2): 573-6.
- Kara M, Dikmen E, Kara SA, Atasoy P. Bilateral elastofibroma dorsi: proper positioning for an accurate diagnosis. *Eur J Cardio-thoracic Surgery*. 2002; 22:839-41.
- Cota C, Solivetti F, Kovacs D, Cristiani R, Amantea A. Elastofibroma dorsi: histologic and echographic considerations. *Int J Dermatol*. 2006; 45:1100-03.
- Schafmayer C, Kahlke V, Leuschner I, Pai M, Tepel J. Elastofibroma dorsi as differential diagnosis in tumors of thoracic wall. *Ann Thoracic Surgery*. 2006; 82:1501-04.
- Briccoli A, Casadei R, DiRenzo M, Favale L, Bacchini P, Bertoni F. Elastofibroma dorsi. *Surgery Today*. 2000; 30(2):147-52.
- Brown GW. Elastofibroma dorsi: report of two cases and literature review. *Wis Med J*. 1991; 90(6):281-4.
- Greenberg JA, Lockwood RC. Elastofibroma dorsi: a case report and review of the literature. *Orthop Rev*. 1989; 18(3):329-33.
- Dixon AY, Lee SH. An ultrastructural study of elastofibromas. *Hum Pathol*. 1980; 11(3): 257-62.
- Schick S, Zembsch A, Gahleitner A, et al. Atypical appearance of elastofibroma dorsi on MRI: case reports and review of the literature. *J Comput Assist Tomogr*. 2000; 24(2):288-92.
- Fukuda Y, Miyake H, Masuda Y, Masugi Y. Histogenesis of unique elastophilic fibers of elastofibroma: ultrastructural and immunohistochemical studies. *Hum Pathol*. 1987; 18(5): 424-9.
- Kumaratilake JS, Krishnan R, Lomax-Smith J, Clearly EG. Elastofibroma: disturbed elastic fibrillogenesis by periosteal-derived cells? An immunoelectronmicroscopic and in situ hybridization study. *Hum Pathol*. 1991; 22:1017-29.
- McComb EN, Feely MG, Neff JR, Johansson SL, Nelson M, Bridge JA. Cytogenetic instability, predominantly involving chromosome 1, is characteristic of elastofibroma. *Cancer Genet Cytogenet*. 2001; 126:68-72.
- Kourda J, Ayadi-Kaddour A, Meria S, Hantous S, Miled KB, Mezni FE. Bilateral elastofibroma dorsi. A case report and review of the literature. *Orthop Traumatol Surg Res*. 2009; 95:383-7.
- Karakurt O, Kaplan T, Gunal N et al. Elastofibroma dorsi management and outcomes: review of 16 cases. *Interactive CardioVascular and Thoracic Surgery*. 2014; 18:197-201.
- Muramatsu K, Ihara K, Hashimoto T, et al. Elastofibroma dorsi: diagnosis and treatment. *J Shoulder Elbow Surg*. 2007; 16:591-595.