

Biochemical and Histopathological Evaluation of the Protective Efficacy of Thymoquinone in Experimentally Ischemia Reperfusion Induced Rat Ovaries

Ozge Nur Turkeri¹, Ayhan Tanyeli², Nezahat Kurt³, Nuri Bakan⁴, Fazile Nur Ekinçi Akdemir⁵, Behzat Mokhtare⁶

¹Department of Nutrition and Dietetics, Faculty of Health Sciences, European University of Lefke, Lefke, TRNC

²Department of Physiology, Faculty of Medicine, Atatürk University, Erzurum, Turkey

³Department of Medical Biochemistry, Faculty of Medicine, Erzincan Binali Yıldırım University, Erzincan, Turkey

⁴Department of Biochemistry, Faculty of Medicine, Atatürk University, Erzurum, Turkey

⁵Department of Nutrition and Dietetics, High School of Health, Ağrı İbrahim Çeçen University, Ağrı, Turkey

⁶Department of Pathology, Veterinary Faculty Atatürk University, Erzurum, Turkey

Article History

Received 15 Jun 2021

Accepted 28 July 2021

Published Online 15 Sep 2021

*Corresponding Author

Ozge Nur Turkeri

Department of Nutrition and Dietetics

Faculty of Health Science,

European University of Lefke,

Lefke, TRNC

Phone: + 90 392 660 2000

E-mail: oturkeri@eul.edu.tr

ORCID: <https://orcid.org/0000-0001-8791-5331>

Abstract: In our study, oxidant-antioxidant and inflammation markers of ovarian tissue were evaluated in order to determine whether thymoquinone has a protective effect against experimentally induced ischemia/reperfusion in rat ovaries. Oxidant-antioxidant and inflammation markers in ovarian tissue were evaluated in order to determine whether thymoquinone has a protective effect against damage in rat ovaries in which ischemia/reperfusion was created. The rats, which randomly divided into 5 groups and were experimentally induced ischemia/reperfusion in their ovaries, were administered thymoquinone at the determined doses. The markers such as TAS, TOS and MDA from ovarian tissues were determined as spectrophotometrically obtained by experimental procedure. Tissues examined histopathologically were evaluated for immunopositivity after immunohistochemical staining with NF- κ B antibodies. While MDA, TOS, OSI levels in tissue were significantly higher in ischemia/reperfusion groups and TQ, MDA, TOS, OSI levels were significantly lower rather than the control group ($p < 0.05$). TAS levels in tissue were significantly lower in the I/R group but after treatment they increased significantly ($p < 0.05$). NFK β 1 immunopositivity could not be detected in Sham and experimental groups ($p > 0.05$). It was concluded that thymoquinone protected the tissues from ischemic damage by causing significant increase in TAS levels that were decreased by I/R injury and significant decrease in elevated levels of MDA and TOS that were increased by I/R injury. © 2021 NTMS.

Keywords: Ischemia/Reperfusion; Oxidative Stress; Thymoquinone.

1. Introduction

Ovarian torsion in women is a gynecological syndrome that results in oophorectomy (removal of the ovaries) by blocking blood circulation in the ovaries both in childhood and adolescence (1). In case of early detection of torsion, infarction departure can be prevented. In this case, ovarian detorsion is performed

to restore blood flow (2,3). Although blood flow has been fixed, ischemia/reperfusion (I/R) injury may occur in ovarian torsion. In this case, various problems may arise in the organism (4). However the mechanism causing the damage has not been fully elucidated, studies have shown that reactive oxygen

species (ROS) produced by polymorph core leukocytes (PMNL), cytokines and complement activation have impact on I/R damage (5, 6). Anti-inflammatory and antioxidant defense systems generally play an active role in preventing I/R damage in tissues (7).

'*Nigella sativa* (NS)', in other words black cumin, is an important plant species that has been used for the treatment of many diseases in the Middle and Near East countries for over 2000 years. Thymoquinone (TQ), one of the main components of its seeds of NS, is a monoterpene. Many studies have shown the antibacterial, antitumor, antioxidant, antineoplastic, antifungal, anti-inflammatory, reactive oxygen positive effects of TQ on the central nervous system (CNS). In addition to all these, it is known that TQ has important effects on cell cycle, immune system and apoptosis (8, 9).

Oxidative stress results from the disruption of the balance between the formation of ROS and antioxidant defense capacity. ROS cause serious damage to macromolecules such as cellular membrane lipids, proteins and DNA and lead to more toxic products such as MDA (10).

Antioxidant means that any substance prevents or delays oxidative damage on the target molecule. There are many substances that act as antioxidants. Although the basic system of protection from ROS damage is enzymatic systems that prevent oxidation, there are also non-enzymatic antioxidant compounds. ROS can cause many diseases such as cataract, skin aging, Alzheimer's, asthma, Parkinson's, and it is the first among the causes of I/R damage (11).

No studies have been found on whether TQ, known for its anti-inflammatory and antioxidant properties, has an effect on ovarian I/R damage or not. According to the this literature findings, in this study we aimed to investigate that whether there is an effectiveness of TQ in the prevention of experimentally I/R-induced damage to rat ovaries or not. For this reason, oxidative stress such as malonyldialdehyde (MDA), total oxidant status (TAS), total antioxidant status (TOS) in ovarian tissue samples after ovarian I/R parameters were measured.

After these measurements, the oxidative stress index (OSI), which is expressed as a percentage of the ratio of TOS levels to TAS levels, was calculated. In addition to this, it was evaluated histopathologically whether TQ had an effect on post-I/R inflammatory activity in ovarian tissue samples immunohistochemically stained with NFK β 1 antibodies for Nuclear Factor Kappa B (NFK β 1), which is known to have a role in events such as cell proliferation, cell differentiation, apoptosis and inflammation.

2. Material and Methods

2.1. Study Animals

'Wistar albino' female rats (12-16 weeks, with an average weight of 200 to 250 grams), which were obtained from Atatürk University Medical Experimental Application and Research Center

(ATADEM), were included in our study which was approved by Atatürk University Rectorate, Animal Experiments Local Ethics Committee with the decision dated 23.02.2018 and numbered 2018-29.

2.2. Chemicals

TOS and TAS of tissue homogenates were determined using kits (Reel Assay Diagnostics, Turkey). Sodium Dodecyl Sulfate (SDS) was obtained from Merck, Acetic acid (CH₃COOH) from Sigma® Thiobarbuturic acid (TBA) from Sigma® Tetraethoxypropane (C₁₁H₂₄O₄) from Sigma® for the measurement of malondialdehyde. Anti-NF- κ B 1 antibody Abcam (Cat. No. ab7971) kit was used for immunochemical analysis NF- κ B.

2.3. Experimental Procedure

Wistar albino rats were fasted the night before for ischemia and reperfusion experiments and were provided free access to water. Rats were randomly separated into 5 groups with 8 animals in each group. Rats were anesthetized with intraperitoneal ketamine (75 mg/kg) and Xylazine (8 mg/kg). Thymoquinone was applied to the rats with ischemia/reperfusion at determined doses. Animals have been underwent the following experimental procedures after 8 days.

Group 1 (Sham Control). Peritoneum were reached by making 1-2 cm incision in the lower abdomen of the experimental animals in this group and closed back without any other procedure.

Group 2 (3 Hours Ovarian Ischemia). Peritoneum was reached by making 1-2 cm incision in the lower abdomen of the experimental animals. The ovarian tissue was exposed to ischemia with the help of a clamp for 3 hours, and at the end of ischemia, the clamp was removed and reperfusion was started. Meanwhile, the incision was closed with a 3-0 surgical silk suture and 3 hours of reperfusion was achieved. After the reperfusion was completed, the ovarian tissues of the rats were removed.

Group 3 (3 Hour Ovarian Ischemia+Thymoquinone 4 mg/kg (intraperitoneal)). Experimental procedures in Group 2 were performed. 4 mg/kg thymoquinone was applied intraperitoneally 30 minutes before reperfusion.

Group 4 (3 Hour Ovarian Ischemia+Thymoquinone 8 mg/kg (intraperitoneal)). Experimental procedures in Group 2 were performed. 8 mg/kg thymoquinone was applied intraperitoneally 30 minutes before reperfusion.

Group 5 (3 Hour Ovarian Ischemia+Thymoquinone 25 mg/kg (intraperitoneal)). Experimental procedures in Group 2 were performed. 25 mg/kg thymoquinone was applied intraperitoneally 30 minutes before reperfusion. After the reperfusion was completed, the ovarian tissues of the rats were removed.

2.4. Biochemical Analysis

50 Mm, pH: 7.2, KH₂PO₄/ K₂HPO₄ buffer was used for tissue homogenization. Ovarian tissues weighing 0.1 g

were placed in glass tubes and homogenized in ice with 2 mL of phosphate buffer. The homogenized tissues were centrifuged at 5000 rpm for 20 minutes at +4 °C and the supernatants were carefully separated. The separated supernatants were used for analysis of MDA, TAS, TOS and protein. The protein concentration of the supernatant was measured using the method described by Bradford MM (12). Biochemical results were expressed on the basis of protein for per gram.

2.5. Determination of Malondialdehyde (MDA)

In the measurement principle of MDA formed as a result of lipid peroxidation, the absorbance of the pink colored complex formed as a result of the reaction of MDA and thiobarbutyric acid (TBA) is measured at 532 nm (13). Results are expressed in $\mu\text{mol/L}$. Tissue MDA concentration was calculated as $\mu\text{mol/g}$ protein using the formula below. Tissue MDA ($\mu\text{mol/g}$ protein) = MDA ($\mu\text{mol/L}$) / Tissue protein (g/L).

2.6. Determination of TAS and TOS

Rel Assay kit was used for the TAS analysis method. The principle used in the analysis method of this kit is based on the reduction of the colored complex ABTS (Ethylbenzothiazoline Sulfonic Acid) cationic radical by all antioxidant molecules in the samples and the decolorization of the colored radical in proportion to the total concentrations of antioxidant molecules (14). Results are measured in a spectrophotometer microplate reader at a wavelength of 660 nm and expressed as mmol Trolox Equiv./L. For tissue samples, the result was divided by protein and reported as μmol Trolox Equivalent/mg protein. The measurement principle of the kit (Rel Assay Diagnostics, Turkey) used for TOS analysis is based on the conversion of oxidants in the samples into ferric ion chelator complexes (15).

In an acidic environment, ferric ions form a colored complex with the help of chromogen. The intensity of the color measured spectrophotometrically at 530 nm. wavelength is related to the total amount of oxidant molecules in the samples. Results are expressed in ($\mu\text{mol H}_2\text{O}_2$ equiv/L). For tissue samples, the result was divided by protein and reported as $\mu\text{mol H}_2\text{O}_2$ equiv/g protein. The percentage ratio of TOS to TAS was used as the OSI. OSI was calculated as TOS divided by 10xTAS.

2.7. Histopathological Assessments

The removed ovarian tissues were determined in 10% neutral formalin solution. After washing, the tissues passed through routine alcohol xylol series were placed in paraffin blocks and 5 μm parts were taken. After deparaffinization, the parts were kept in microwave

oven for 15 minutes with 400 watts of antigen retrieval solution (pH 6.0). Parts washed with PBS were incubated with NFK β 1 (cat no. ab7971, dilution ratio 1/200, Abcam) antibodies for 15 minutes at room temperature for inflammatory activity. Parts washed with PBS were stained with Expose mouse and rabbit specific HRP/DAB detection IHC kit. 3,3' diaminobenzidine (DAB) was used as a chromogen. After counterstaining with hematoxylin, parts passed through alcohol xylol series were examined under a light microscope. The immunopositivity was evaluated as no (0), mild (1), moderate (2), and severe (3).

2.8. Statistical analysis

Statistical Package for Social Sciences (SPSS) for Windows 23.0 program was used for statistical analysis. Biochemical results were given as mean \pm standard deviation (X \pm SD), and P values below 0.05 were considered statistically significant. The normality test of the data was evaluated with Kolmogorov Smirnov. As the data fit the normal distribution, the groups were compared with the parametric test, one-way ANOVA. The significance of the difference between the groups was determined by the Post Hoc Tests Tukey HSD test. Kruskal Wallis, one of the non-parametric tests, and MannWhitney U test were used to determine the differences between the groups for histopathological data (p<0.05).

3. Results

3.1. Biochemical Results

Tissue MDA, TAS and TOS analysis X \pm SD and p values of all results are shown in Table 1.

When the MDA levels in Table 1 were compared, it was observed that the MDA level in the I/R damaged groups (8.99 \pm 1.14) increased significantly compared to the sham group (5.17 \pm 1.07) (p=0.001). It was observed that MDA levels in the groups treated with TQ approached the sham group after I/R (Figure 1).

When the mean of MDA levels was compared in the study groups, statistically significant difference were found between the groups (p<0.05). The amount of MDA in the IR+4 mg/kg TQ (p=0.000) and IR+8 mg/kg TQ (p=0.001) groups were statistically significantly decreased compared to the IR group. But there is no significant difference compared to the IR+25 mg/kg TQ group (p=0.114).

When the mean of OSI levels was compared in the study groups, there was a statistically significant difference among the groups (p<0.05). The amount of OSI in the IR+4 mg/kg TQ (p=0.000) and IR+8 mg/kg TQ (p=0.000) and IR+25 mg/kg TQ (p=0.001) groups were statistically and significantly decreased compared to the IR group. (Table 1).

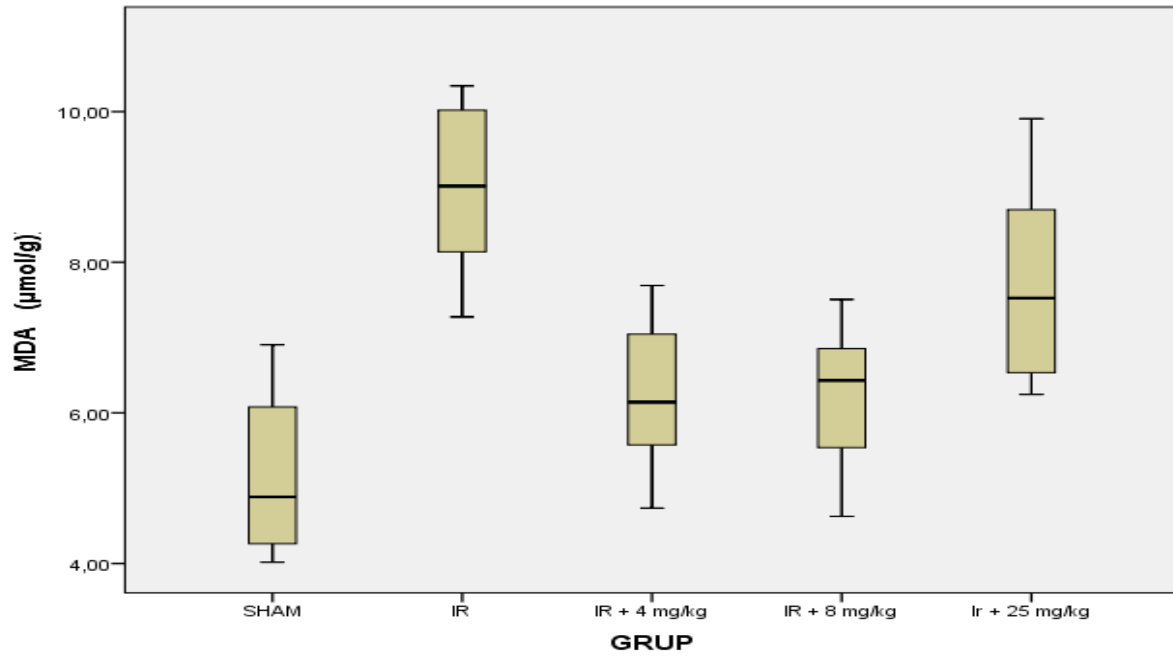


Figure 1: Ovarian Tissue MDA levels in Groups.

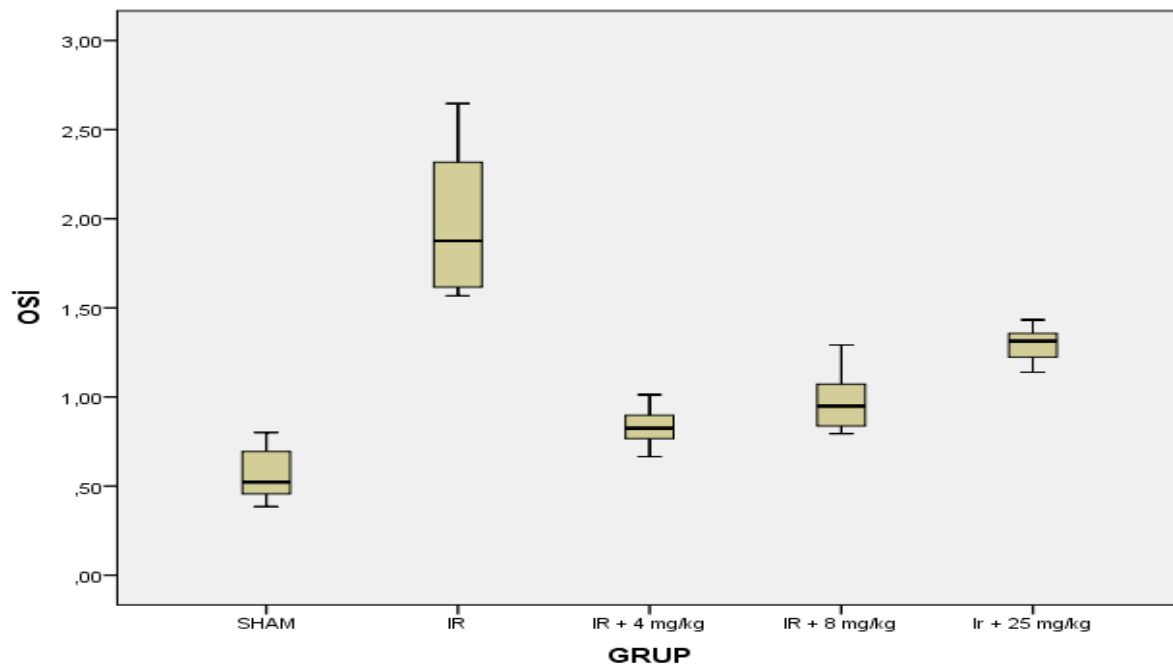


Figure 2. Ovarian Tissue OSI levels in Groups.

In Figure 2, Oxidative Stress Index (OSI) levels, known as the percentile of the ratio of TOS levels to TAS levels, are given. When the OSI levels in Table 1 were compared, it was observed that the OSI level was significantly higher in the groups with I/R injury (1.97 ± 0.41) compared to the sham (0.56 ± 0.14) group

($p=0.001$). OSI levels were significantly decreased after I/R injury in groups treated with TQ ($p=0.001$).

3.2. Histopathological Results

NF- κ B 1 immunopositivity in ovaries could not be detected in Sham and experimental groups (Figure 3, Table 2).

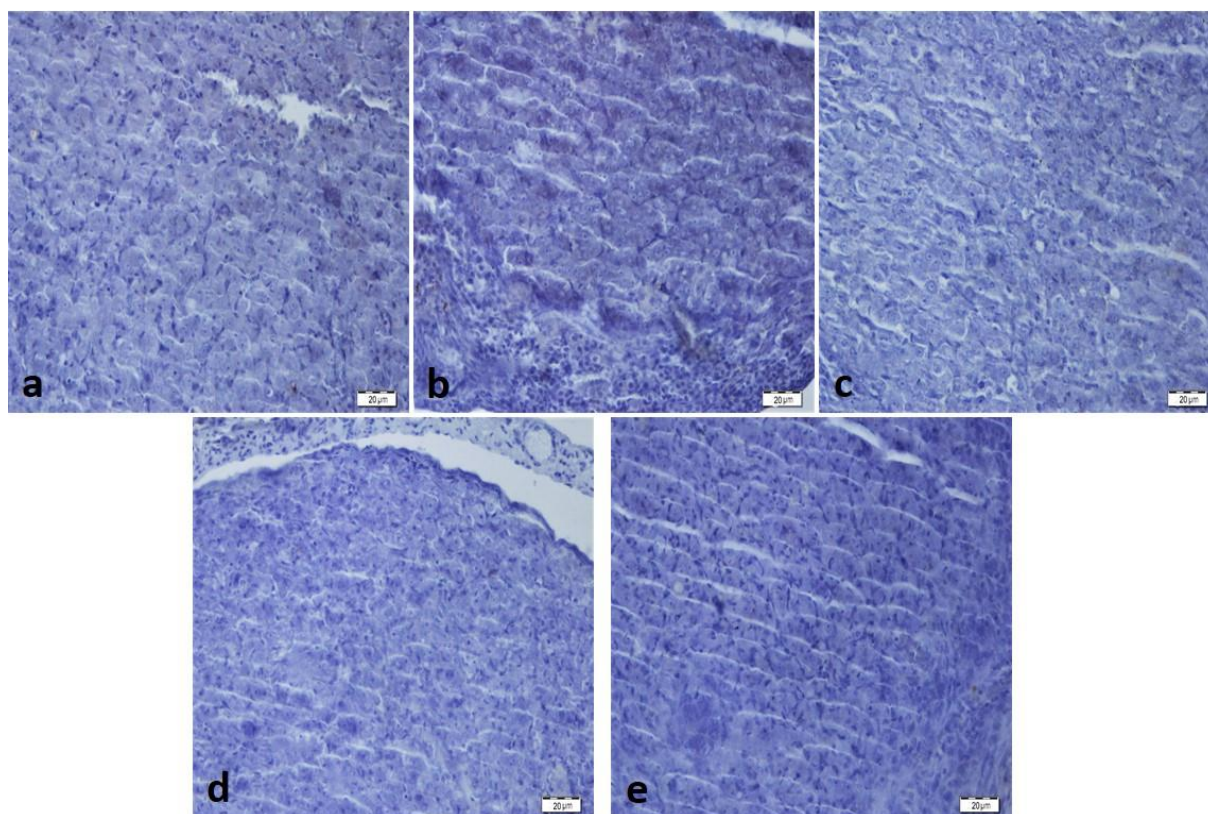


Figure 3: Immunonegativity in NFKB1 staining. (a) sham group, (b) I/R group, (c) I/R+4 mg/kg TQ group, (d) I/R+8 mg/kg TQ group, (e) I/R+25mg/kg TQ.

Table 1: Analyte levels in ovarian tissue.

	SHAM X±SD* (N:8)	IR X±SD* (N:8)	IR+4 mg/kg TQ X±SD* (N:8)	IR+8 mg/kg TQ X±SD* (N:8)	IR+25 mg/kg TQ X±SD* (N:8)	p
MDA μmol/g protein	5.17±1.07 ^b	8.99±1.14 ^{a,b,c,d}	6.24±0.99 ^b	6.22±0.97 ^{a,b}	7.70±1.31	0.000**
TAS mmol Trolox Equiv/mg protein	11.92±1.08 ^{a,b}	7.10±1.09 ^{b,c}	10.06±0.94	9.77±1.01	8.92±1.08	0.000**
TOS μmol H₂O₂ Equiv/mg protein	6.66±1.42	13.76±1.9 ^c	8.46±1.34 ^b	9.52±1.85	12.03±1.26	0.000**
OSI	0.56±0.14 ^b	1.97±0.41 ^{a,c,d,e}	0.84±0.13 ^b	0.97±0.16 ^b	1.35±0.13 ^b	0.000**

SHAM: Control, IR: Ischemia-reperfusion, IR+4 mg/kg TQ: Ischemia-reperfusion+4 mg/kg Thymoquinone group. IR+8 mg/kg TQ: Ischemia-reperfusion+8 mg/kg Thymoquinone group. IR+25 mg/kg TQ: Ischemia-reperfusion+25 mg/kg Thymoquinone group. MDA: Malondialdehyde, tGSH: total glutathione, TAS: Total antioxidant status, TOS: Total oxidative status. OSI: oxidative stress index. a: statistically significantly different compared with SHAM, b: statistically significantly different compared with IR, c: statistically significantly different compared with IR+4 mg/kg TQ, d: statistically significantly different compared with IR+8mg/kg TQ, e: statistically significantly different compared with IR+25 mg/kg. *x±SD: Mean±STD. ** p<0.05.

Table 2: Data Obtained from Staining with NF-kB1 Antibodies.

	Sham	I/R	IR+4mg/kg TQ	IR+8mg/kg TQ	IR+25mg/kg TQ
NFKB1	0.25±0.46	0.37±0.51	0.50±0.53	0.12±0.35	0.25±0.46

4. Discussion

Ischemia is defined as the inability to oxygenate and feed the organs or tissues as a result of a clot that occurs in the vessels that provide blood flow or a mechanical factor. Some structural and metabolic changes occur in cells with ischemia (16).

Reperfusion is defined as the increase in the amount of oxygen in the tissue with the mechanisms developed by the tissue after ischemia in order to prevent ischemia and restore blood flow. However, the reperfusion of tissues exposed to ischemia and the initiation of the inflammatory process with activated mechanisms cause more tissue damage than ischemia (17, 18).

Hesperetin (19), aprotinin (20), tacrolimus (21), ursodeoxycholic acid (22), N-acetyl cysteine and resveratrol (23), erythropoietin (24), curcumin (25) and sildenafil (26) were used in studies to reduce reperfusion damage in the ovaries and the studies showed that ovarian damage was reduced to a certain extent.

Studies showed that oxidative stress is primarily responsible for the formation of I/R damage (27). MDA, the end product of lipid peroxidation, is used as an indicator of oxidative stress in tissues (28). Kılıç et al. examined the effects of N-Acetyl Cysteine and Resveratrol on I/R damage in rat ovaries and showed that MDA levels increased significantly in I/R groups compared to the control group (23). On the other hand, Yuan et al. showed that MDA levels increased in the I/R group in their animal experiment studies in which they investigated hepatic I/R damage and MDA levels decreased significantly after treatment (29). In a study conducted by Beheshtian et al. shown that MDA levels increased in the I/R group compared to the control group in ovarian tissue and MDA levels were significantly decreased in the groups treated with sildenafil (30). In another study investigating the protection of atorvastatin in the ovarian I/R model, it was reported that MDA levels increased significantly in the I/R group, whereas MDA levels decreased significantly in the atorvastatin applied groups and approached the control group (31). In our study, as the other studies in the literature, tissue MDA levels were found to be significantly higher in the I/R group than in the sham group. In recent years, it has been determined that MDA levels have decreased significantly in the treatment groups in which TQ has been applied, which has focused on many properties such as antioxidant, antitumoral, antineoplastic, anticarcinogenic, antifungal and anti-inflammatory.

Considering recent studies, TOS parameter is used to analyze lipid peroxidation activities. Protective enzymes such as SOD, GSH, CAT react against damage caused by ROS, and these protective enzymes form TAS (30). Oxidative stress parameters such as

TOS and TAS are important markers used to determine the effectiveness of I/R damage and treatment modalities. In studies conducted, TAS levels were found to be significantly lower in I/R injury compared to control groups, while TOS levels were found to be higher (32, 33). Avni et al. while TOS and OSI levels were higher in I/R formed rat ovaries compared to the control group, it was reported that there was a significant decrease in oxidative stress levels after treatment with resveratrol and N-acetyl cysteine (18). In our study, while TOS and OSI levels were increased as markers of damage, TAS levels decreased in groups with I/R in ovarian tissue. While TOS and OSI values decreased significantly in TQ applied groups, it was determined that TAS levels increased and approached the sham group.

The immunopositivity of NF- κ B1, which is known as one of the important indicators of oxidative stress in histopathological evaluations, could not be detected in the sham and experimental groups in the immunohistochemical sections. When the studies have been examined in the literature, it has been seen that the activation of NF- κ B increases during ischemia, and it shows excessive reactivity in I/R damage in immunohistochemistry sections (34).

5. Conclusions

In our study, it is aimed to research the effectiveness of TQ, which is known for its anti-inflammatory and antioxidant properties, in the prevention of experimentally I/R-induced damage in rat ovaries, and we showed the protective effect of TQ in line with our findings. TQ showed these effects by reducing the oxidative stress parameters that occur in I/R damage. It was observed that MDA, TOS, OSI levels in particular increased in I/R injury and approached the control group with TQ application. In our current study, in addition to biochemical parameters, NF- κ B 1 immunopositivity was examined histopathologically, but immunopositivity could not be detected in Sham and experimental groups.

Conflict of Interests

The authors approved that they have no conflict of interest

Financial Support

The authors approved that this study has received no financial support from any institution.

Author Contributions

Turkeri ON, Tanyeli A and Bakan N contributed to the constructing the idea for research. Turkeri ON contributed to the planning the design of the work. Turkeri ON, Ekinci Akdemir FN, Tanyeli A, Kurt N and Mokhtare B contributed to the execution of the experiments. Turkeri ON, Tanyeli A and Kurt N

contributed to the analysis and interpretation of data. Turkeri ON contributed to the providing tools and instruments. Turkeri ON, Ekinci Akdemir FN, Kurt N and Mokhtare B contributed to the biological materials. Turkeri ON contributed to the literature review. Turkeri ON and Bakan N contributed to the critical review. Turkeri ON, Kurt N, Tanyeli A, Bakan N, Ekinci Akdemir FN, and Mokhtare B contributed to the final approval of the version to be published.

Ethical Approval

The study was approved by Atatürk University Rectorate Animal Experiments Local Ethics Committee with the decision dated 23.02.2018 and numbered 2018-29.

Acknowledgment

This study has been derived from the PhD Thesis "İskemi Reperfüzyonla İndüklenen Rat Over Hasarı Üzerine Timokinonun Biyokimyasal ve Histopatolojik Etkisi (Biochemical and Histopathological Effects of Thymoquinone on Ischemia Reperfusion-Induced Rat Ovarian Injury)".

References

- Meyer JS, Harmon CM, Harty MP, Markowitz RI, Hubbard AM, Bellah RD. Ovarian torsion: clinical and imaging presentation in children. *J Pediatric Surg* **1995**; 30: 1433- 1436.
- Chen M, Chen CD, Yang YS. Torsion of the previously normal uterine adnexa. Evaluation of the correlation between the pathological changes and the clinical characteristics. *Acta Obstet Gynecol Scand* **2001**; 80: 58-61.
- Haskins T, Shull BL. Adnexal torsion: a mind-twisting diagnosis. *South Med J* **1986**; 79: 576-577.
- Taskin O, Birincioglu M, Aydin A, Buhur A, Burak F, Yilmaz I, Wheeler JM. The effects of twisted ischaemic adnexa managed by detorsion on ovarian viability and histology: an ischaemia-reperfusion rodent model. *Hum Reprod* **1998**; 13: 2823- 2827.
- Kuroda S, Siesjo BK. Reperfusion damage following focal ischemia: pathophysiology and therapeutic windows. *Clin Neurosci* **1997**; 4: 199-212.
- Jordan JE, Zhao ZQ, Vinten-Johansen J. The role of neutrophils in myocardial ischemia-reperfusion injury. *Cardiovasc Res* **1999**; 43: 860-878.
- Mogilner JG, Lurie M, Coran AG, Nativ O, Shiloni E, Sukhotnik I. Effect of diclofenac on germ cell apoptosis following testicular ischemia-reperfusion injury in a rat. *Pediatr Surg Int* **2006**; 22: 99-105
- Medenica R, Mukerjee S, Muschart T, Koffskey J, Corbit W. Nigella sativa plant extract increases number and activity of immune component cell in humans. *Exp Hematol* **1993**; 21 (3): 1186.
- Aggarwal BB, Kunnumakkara AB, Harikumar KB, Tharakan ST, Sung B, Anand P. Potential of spice-derived phytochemicals for cancer prevention. *Planta Medica* **2008**; 74 (13): 1560-1569.
- Staicu ML, Mureşan A, Tache S, Moldovan R. Effects of exogenous antioxidants on oxidative stress in pregnancy. *J Med Life* **2011**; 4(2): 163-167.
- Abdollahi M, Ranjbar A, Shadnia S, Nikfar S, Rezaie A. Pesticides and oxidative stress: a review. *Med Sci Monitor* **2004**; 10, 6, 141-147.
- Bradford MM. A rapid and sensitive method for the quantitation of microgram quantities of protein utilizing the principle of protein-dye binding. *Anal Biochem* **1976**; 72, 248-254.
- Ohkawa H, Ohishi N, Yagi K. Assay for lipid peroxides in animal tissues by thiobarbituric acid reaction. *Anal Biochem* **1979**; 95: 351-358.
- Erel O. A novel automated method to measure total antioxidant response against potent free radical reactions. *Clin Biochem* **2004**; 37: 112-119.
- Erel O. A new automated colorimetric method for measuring total oxidant status. *Clin Biochem* **2005**; 38: 1103-1111.
- Dorweiler B, Pruefer D, Andradi TB, Maksan SM, Schmiedt W, Neufang A, Vahl CF. Ischemia-Reperfusion Injury Pathophysiology and Clinical Implications. *Eur J Trauma Emerg Surg* **2007**; 33: 600-612.
- Zimmerman BJ, Granger DN. Reperfusion injury. *Surg Clin North Am* **1992**; 72: 65-83.
- Cerqueira NF, Hussni CA, Yoshida WB. Pathophysiology of mesenteric ischemia/reperfusion: a review. *Acta Cir Bras* **2005**; 20: 336-343.
- Cakir Gungor AN, Gencer M, Karaca T, et al. The effect of hesperetin on ischemia-reperfusion injury in rat ovary. *Arch Gyne col Obstet* **2014**; 290: 763-769.
- Sahin FK, Cosar E, Koken G, et al. Protective effect of aprotinin on ischemia-reperfusion injury in rat ovary. *J Obstet Gynaecol Res* **2008**; 34: 794-800.
- Ustundag UV, Sahin S, Ak K, et al. The effects of tacrolimus on the activity and expression of tissue factor in the rat ovary with ischemia-reperfusion induced injury. *Reprod Biol* **2015**; 15: 139-145.
- Akdemir A, Sahin C, Erbas O, et al. Isursodeoxycholic acid crucial for ischemia/reperfusion-induced ovarian injury in rat ovary? *Arch Gynecol Obstet* **2015**; 292: 445-450.
- Kılıç A., Uyanıkoğlu H., İncebiyik A. Protective Effect of N-Acetylcystein and Resveratrol on Ischemia-Reperfusion Injury in Rat Ovary. *Dicle Med J* **2016**; 43(2): 229-236.
- Ergun Y, Koc A, Dolapcioglu K, et al. The protective effect of erythropoietin and

- dimethylsulfoxide on ischemia-reperfusion injury in rat ovary. *Eur J Obstet Gynecol Reprod Biol* **2010**; 152: 186-190.
25. Eser A, Hizli D, Haltas H, et al. Effects of curcumin on ovarian ischemia- reperfusion injury in a rat model. *Biomed Rep* **2015**; 3: 807-813.
 26. Celik M. Sildenafil'in Sıçan Överlerinde Oluşturulan İskemi Reperfüzyon Hasarındaki Etkisinin Biyokimyasal Ve Histopatolojik Olarak Araştırılması. Faculty of Medicine, Department of Biochemistry. Dissertation, Erzurum: Atatürk University, 2011.
 27. Hussein A, Abd-Elkhabir A, Abozahra A, et al. Pancreatic injury secondary to renal ischemia/reperfusion (I/R) injury: possible role of oxidative stress. *Physiol Res* **2013**; 63: 47-55.
 28. Kowalczyk K, Stryjecka-Zimmer M. The influence of oxidative stress on the level of malondialdehyde (MDA) in different areas of the rabbit brain. *Ann Univ Mariae Curie-Skłodowska. Sectio D: Med* **2002**; 57: 160-164.
 29. Yuan GJ, Ma JC, Gong ZJ, et al. Modulation of liver oxidant-antioxidant system by ischemic preconditioning during ischemia/reperfusion injury in rats. *World J Gastroenterol* **2005**; 11: 1825-1828.
 30. Sancak EB, Akbas A, Silan C, Cakir DU, Turkon H, Ozkanli SS. Protective effect of syringic acid on kidney ischemia-reperfusion injury. *Ren Fail* **2016**; 38: 629-635.
 31. Cadirci E, Oral A, Odabasoglu F, Kilic C, Coskun K, Halici Z, Suleyman H, Nuri Keles O, Unal B. Atorvastatin reduces tissue damage in rat ovaries subjected to torsion and detorsion: biochemical and histopathologic evaluation. *NaunynSchmiedeberg's Arch Pharmacol* **2010**; 381: 455-466.
 32. Yurtcu E, Togrul C, Ozyer S, Uzunlar O, Karatas YH, Seckin KD, Caydere M, Hucumenoglu S, Cicek N. Dose dependent protective effects of vardenafi I on ischemia-reperfusion injury with biochemical and histopathologic evaluation in rat ovary. *J Pediatr Surg* **2015**; 50: 1205-1209.
 33. Yildiz F., CobanS., Terzi A., Ates M, Aksoy N., Cakir H., Ocak A.R., and Bitiren M. Nigella sativa relieves the deleterious effects of ischemia reperfusion injury on liver. *World J Gastroenterol* **2008**; 14(33): 5204–5209.
 34. Curtis CD, Thorngren DL, Nardulli AM. Immunohistochemical analysis of oxidative stress and DNA repair proteins in normal mammary and breast cancer tissues. *BMC Cancer* **2010**; 10: 9.

Authors' ORCID

Ozge Nur Turkeri

<http://orcid.org/0000-0001-8791-5331>

Ayhan Tanyeli

<https://orcid.org/0000-0002-0095-0917>

Nezahat Kurt

<http://orcid.org/0000-0002-1685-5332>

Nuri Bakan

<http://orcid.org/0000-0002-2139-7268>

Fazile Nur Ekinci Akdemir

<http://orcid.org/0000-0001-9585-3169>

Behzat Mokhtare

<http://orcid.org/0000-0002-9075-7289>



<https://dergipark.org.tr/tr/pub/ntms>

All Rights Reserved. ©2021 NTMS.