

Repeated Hemothorax Following Ipsilateral Left Internal Jugular and Left Subclavian Venous Catheterization

Fatma ÜLGER*, Binnur SARIHASAN*, Alpaslan ŞENEL**

- ✓ Central venous catheterization is one of the most commonly used invasive procedures in critically ill patients. The most frequent sites of cannulation are the internal jugular and subclavian veins. They permit hemodynamic monitoring and allow access for the administration of fluids, blood products, medications, and total parenteral nutrition (TPN). Complications include arterial puncture with the internal jugular approach (0.1 to 4%) and pneumothorax or hemothorax with the subclavian approach (1 to 5%). Our patient with left internal jugular vein catheterization was complicated with hemothorax in the first cannulation application in operation. Left subclavian vein was cannulated in the intensive care unit and catheter was placed into the thorax. Overall, internal jugular and subclavian venous catheterization carry similar risks of mechanical complications as multiple cannulation applications in ipsilateral side, might increase complication rate.

Key words: central venous catheterization, internal jugular vein, subclavian vein, hemothorax

- ✓ **Aynı Taraf Sol İnternal Jugular ve Subklavian Venöz Kateterizasyondan Sonra Tekrarlayan Hemotoraks**

Kritik hastada en sık kullanılan invaziv girişimlerden birisi de santral kateterizasyon işlemidir. Kateterizasyon sıklıkla internal juguler ve subklavian vene uygulanır. Bu venler hemodinamik monitorizasyona izin verdiği gibi ilaç ve sıvı tedavileri, kan transfüzyonu ve total parenteral beslenmeye için de olanak sağlar. Komplikasyonlar internal juguler vende %1-4 sıklıkla arter delinmesi ve subklavian girişimlerde %1-5 sıklıkla hemotoraks ve hidrotoraktır. Bizim hastamızda ilk girişimde yerleştirilen internal juguler ven kateteri hemotoraksa yol açmıştır. Yoğun bakım koşullarında sol subklavian vene yerleştirilen kateter toraks içerisine yerleştirilmiştir. Sonuç olarak internal jugular ve subklavian venöz kateterizasyonun mekanik komplikasyonları benzer riskler taşımaktadır ve aynı taraftan çoklu kateterizasyon girişimlerinde komplikasyon olasılığı artabilmektedir.

Anahtar kelimeler: santral venöz kateterizasyon, internal juguler ven, subklavian ven, hemotoraks

INTRODUCTION

Central venous catheters allow measurement of hemodynamic variables and allow delivery

of medications and nutritional support that cannot be given safely through peripheral venous catheters. Unfortunately, the use of central venous catheters is associated with adverse events that are both hazardous to patients⁽¹⁻³⁾. More than 15 percent of patients who receive these catheters have complications^(4,6).

* Ondokuz Mayıs University Faculty of Medicine, Department of Anesthesiology and Reanimation, SAMSUN

** Ondokuz Mayıs University Faculty of Medicine, Department of Neurosurgery, SAMSUN

Mechanical complications are reported to occur in 5 to 19 percent of patients^(4,5), infectious complications in 5 to 26 percent^(4,6), and thrombotic complications in 2 to 26 percent⁽⁶⁾. Arterial puncture, hematoma, and pneumothorax are the most common mechanical complications during the insertion of central venous catheters. Subclavian catheterization is more likely than internal jugular catheterization to be complicated by pneumothorax and hemothorax, whereas internal jugular catheterization is more likely to be associated with arterial puncture.

We want to report a case with hemothorax after multiple application of ipsilateral internal jugular and subclavian venous catheterization.

CASE REPORT

A 2.5 year old patient with crying restlessness and sub febrile fever was brought to pediatric emergency service. She was, ASA 1 (*American Society of Anesthesiology*), GCS 15 (*Glasgow Coma Scale*). Her clinical conditions suddenly worsened; nausea, vomiting and neck stiffness started in emergency service. Neurological consultation showed the evidence of a mass localized at posterior side of the third ventricle and adjacent to the right thalamus on computed tomography scanning. Ventriculo-peritoneal shunt was placed for increased intracranial pressure. Two days later surgical procedure was performed to remove the mass completely. After routine monitorisation, anesthesia was induced through a peripheral venous line. Thereafter central cannulation was planned for insufficient peripheral venous access. Patient had bilateral femoral venous thrombosis and right ventriculo-peritoneal shunt, thus; right subclavian cannulation was failed; therefore left jugularis internal side cannulation with a single lumen 22G catheter (*Certofix Mono Pead B. Braun® Melsungen AG Germany*) was performed. During the operation; all medication, fluids and blood transfusion were administered via left internal jugular venous line. While the patient's oxygen saturation was decreased, inappropriate responses to medication and

blood aspiration were seen, probably due to the misplaced catheter. Infusion through central venous line was stopped and peripheral venous line was used afterwards. The operation was completed soon after the patient was transferred to the intensive care unit with ambu bag and oxygen. She had tachycardia with a heart rate of 190/min, respiration rate of 45/min and blood pressure of 175/90/80 mmHg. Breath sounds were diminished on the left hemithorax and peripheral O₂ saturation decreased to 89% and her face was pale. Arterial blood gas parameters were: pH 7.17, PCO₂: 35.5 mmHg, pO₂ 57.6 mmHg, SpO₂: 81%, ABE: 10mEq/L, HCO₃: 18mEq/L when FiO₂ was 100%. After a follow up period; a left sided hemothorax was diagnosed by a posterior-anterior chest x-ray and the tip of catheter was seen in the pleural cavity (Figure 1). The catheter was drawn back. The chest tube was placed to the left hemi thorax (Figure 2.) and 700 ml bloody fluid was drained. On auscultation; breath sounds improved and SpO₂ exceed to >90. The second central catheterization was inserted on the left subclavian vein as the peripheral intravenous access was still inefficient. The new central catheter was inserted and blood was easily aspirated from all lumens and patient's medications were started again. On the next chest x-ray films and CT scanning the catheter was observed in the pleural cavity and the second catheter was drawn back. A new peripheral line was inserted

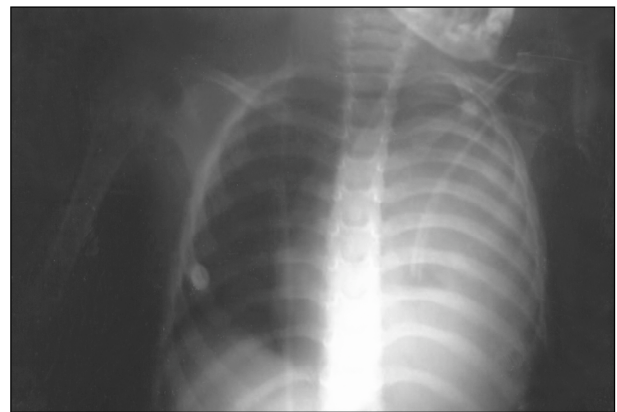


Figure 1. Chest x-ray showing left hemithorax.

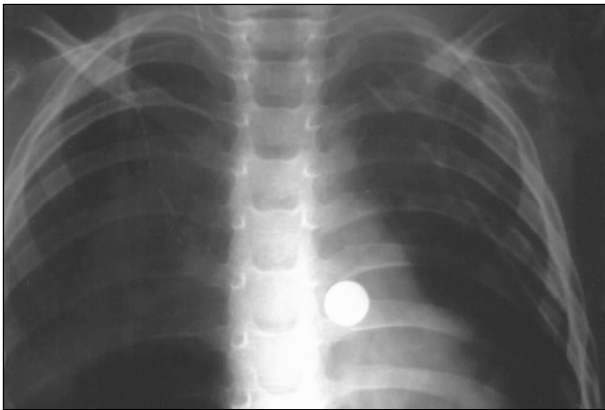


Figure 2. Chest x-ray showing left hemothorax after chest tube.

for medication infusion. The patient was observed at intensive care unit and transferred to the neurosurgery service after 24 hours from the operation. The thorax drain was drawn back on post-operative third day and she was discharged from hospital at tenth day following this procedure.

DISCUSSION

The main goal in placement of central venous catheters is to obtain an access to central circulation. Ante-cubital and femoral veins are used less frequently. Internal jugular veins and subclavian veins (sometimes external jugular veins) are frequently used for central venous catheterization.

The incidence of minor and major complications after central cannulation are approximately 10%⁽⁷⁾. Complications commonly occur at early stages but sometimes these complications may not be detected even if appropriate techniques are used. In this case, infused fluids and blood were collected in the pleural cavity. Confirming the right placement of the catheter by radiographic techniques in the operating room is a recommended procedure. However we were unable to confirm the catheter tip position because of technical problems. The risk of pneumothorax during the jugular venous cannulation is up to 0.3 %, and during the subclavian venous cannulation is between 0.3-3%⁽⁸⁾. So, anesthetist generally

prefer the jugular venous cannulation⁽⁹⁾. The migration of the tip of catheter or malposition occurs in 6% of cases⁽¹⁰⁾. 10 Brister and Barnette encountered with left hemothorax and effusion after the intrapleural placement of the catheter during the jugular vein catheterization⁽¹¹⁾. In another case report, Paw defined pleural effusion that occurred following puncture to the left internal jugularis⁽¹²⁾. Madhavi and Robinson reported unilateral hydrothorax in two preterm infant revealed after the central catheterization⁽¹³⁾. Johnson et al reported that central catheterization in children is relatively safe, with only a 3.2% complication rate and no mortality⁽¹⁴⁾. Their series included 1435 consecutive catheterizations in children over a 10-year period. Another study from Janik et al. with 1.6% total complications; 0.9% of them were pulmonary (pneumothorax, hemothorax or an effusion)⁽¹⁵⁾. Karakaya and colleagues reported unilateral hydrothorax after the right subclavian vein in a 14 years old child⁽¹⁶⁾.

In our case, because of peripheral and central vascular line problems, catheterization was performed on both jugularis interna and subclavian veins, which were located at the same side. Unfortunately, hemothorax was encountered for both catheterizations. After the second cannulation, free return of blood from all catheter lumens was confused because of the hemothorax caused by the first cannulation on the same side. Aspiration of blood from the bloody hemothorax considered as the needle was in the vein, so the catheter was inserted. Close observation and monitorization of the patient during the peri-operative period in the intensive care unit with chest radiographs, complications were detected at early period and the fatal outcome was hindered.

CONCLUSION

Free blood aspiration from the central venous cannula may mislead the physician if hemothorax had occurred during the catheterization. In conclusion; if the previous

central venous catheterization was misplaced and a complication like hemothorax was encountered, the catheter misplacement risk may be increased after subsequent catheterization application from the same side. For the prevention of such complications, contra-lateral cannulation site may be preferred. Hemothorax after the first cannulation might have facilitated the risk of misplacement after the subsequent application to the ipsilateral side.

Geliş Tarihi : 08/03/2005

Yayına kabul tarihi : 15/01/2007

Yazışma adresi :

Fatma ÜLGER

Ondokuz Mayıs Üniversitesi

Tıp Fakültesi

Anesteziyoloji ve Reanimasyon Anabilim Dalı

55139 Kurupelit / SAMSUN

REFERENCES

- Pittet D, Tarara D, Wenzel RP. Nosocomial bloodstream infection in critically ill patients: excess length of stay, extra costs, and attributable mortality. *JAMA* 1994; 271: 1598–601.
- Arnou PM, Quimosing EM, Beach M. Consequences of intravascular catheter sepsis. *Clin Infect Dis* 1993; 16: 778–84.
- Richards MJ, Edwards JR, Culver DH, et al. Nosocomial infections in medical intensive care units in the United States. *Crit Care Med* 1999; 27: 887–92.
- Merrer J, De Jonghe B, Golliot F, et al. Complications of femoral and subclavian venous catheterization in critically ill patients: a randomized controlled trial. *JAMA* 2001; 286: 700–7.
- Sznajder JI, Zvebil FR, Bitterman H, et al. Central vein catheterization: failure and complication rates by three percutaneous approaches. *Arch Intern Med* 1986; 146: 259–61.
- Veenstra DL, Saint S, Saha S, et al. Efficacy of antiseptic-impregnated central venous catheters in preventing catheter-related bloodstream infection: a meta-analysis. *JAMA* 1999; 281: 261–7.
- Muhm M. Ultrasound guided central venous access (editorial). *BMJ* 2002; 325: 1373–74.
- Rosen M, Latta IP, Nug WS, et al. Handbook of percutaneous central venous catheterization. London: WB Saunders; 1981.
- Bowdle TA. Complication of invasive monitoring. *Anesth Clin N Am* 2002; 20: 571–88.
- Vaquez RM, Brodski EG. Primary and secondary malposition of silicone central venous catheters. *Acta Anaesth Scand Suppl* 1985; 81: 22–6.
- Brister NW, Barnette RE. Intrapleural placement of central venous catheter. Failure of preventive practices. *Chest* 1992; 101: 1458–9.
- Paw HGW. Bilateral pleural effusions: unexpected complication after left internal jugular venous catheterization for total parenteral nutrition. *Br J Anaesth* 2002; 89: 647–50.
- Madhavi P, Jameson R, Robinson MJ et al. Unilateral pleural effusion complication central venous catheterization. *Arch Dis Child Fetal Neonatal Ed.* 2000; 82: 248–9.
- Johnson EM, Saltzman DA, Suh G, et al. Complications and risks of central venous placement in children. *Surgery* 1998; 124: 911–6.
- Janik JE, Cothren CC, Janik JS, et al. Is a routine chest x ray necessary for children after fluoroscopically assisted central venous access. *Pediatric Surg.* 2003; 38: 1199–202.
- Karakaya D, Baris S, Üstün E, et al. Hydrothorax a life threatening complication during thoracotomy. *Paed Anaesth* 2002; 12: 809.