

Solitary Fibrous Tumor of the Pleura: A Huge Intrathoracic Mass

Serhat FINDIK, MD¹, Merve G. BAYRAK, MD¹, M. Levent ERKAN, MD¹,
Oguz AYDIN, MD², Atilla G. ATICI, MD¹, Oguz UZUN, MD¹

Departments of Pulmonary Medicine¹ and Pathology,², Ondokuz Mayıs University, School of Medicine, SAMSUN

-
- ✓ Solitary fibrous tumor of the pleura is among the rare tumors of the thorax. We report a 60 years-old nonsmoker female patient who presented with increasing non-pleuritic chest pain, dyspnea and constitutional symptoms including weight loss, anorexia and malaise for one year. Chest x-ray and thorax computerised tomography (CT) revealed a huge mass on right hemithorax. The patient underwent thoracotomy at which complete resection of the mass was made. Immunohistopathologic examination of the surgical specimen revealed the presence of a solitary fibrous tumor of the pleura. The patient was still alive without any recurrence at the 58th month of follow-up.

Key words: *Solitary fibrous tumor, pleura, thoracotomy, immunohistopathology.*

- ✓ **Plevranın Soliter Fibröz Tümörü: Dev Bir İntratorasik Kitle**
Plevranın soliter fibröz tümörü toraksın nadir tümörleri arasındadır. Bir yıl içinde giderek artan nonplöritik göğüs ağrısı, nefes darlığı ile kilo kaybı ve iştahsızlık şikayetleri ile başvuran 60 yaşında sigara içmeyen bir kadın hastayı takdim ediyoruz. Akciğer grafisi ve bilgisayarlı toraks tomografisinde (BT) sağ hemitoraksta dev bir kitle görüldü. Hasta torakotomiye alınarak kitlenin total rezeksiyonu yapıldı. Cerrahi örneğin immünohistopatolojik incelenmesi bir plevra fibröz soliter tümör varlığını gösterdi. Takibin 58. ayında hasta halen hayatta olup herhangi bir nüks görülmemiştir.

Anahtar kelimeler: *Soliter fibröz tümör, plevra, torakotomi, immünohistopatoloji*

INTRODUCTION

Solitary fibrous tumor of the pleura has been described by a variety of names including subpleural, submesothelial, or pleural fibroma; local, fibrous, or benign mesothelioma; localised or solitary fibrous tumor; and fibrosarcoma. Among these, the solitary fibrous tumor is preferred. The tumor is uncommon, approximately 350 cases had been documented in the literature by 1980⁽¹⁾, and additional 223 cases were reported from the files of the Armed Forces Institute of Pathology ("AFIP") in 1989⁽²⁾. Approximately 1500 intrathoracic malignancies have been diagnosed in our clinic, which is the reference clinic in the Black Sea Region, since 1988 and among them there was

only one (present case) solitary fibrous tumor of the pleura.

In this report, we describe the first case of solitary fibrous tumor of the pleura in our clinic.

CASE

A 60-years-old female who was previously healthy presented to our clinic with a history of right-sided nonpleuritic chest pain and constitutional symptoms including malaise, weight loss (8 kg) and anorexia. She was a nonsmoker, house-wife and there was no significant event in her past history. On physical examination, she appeared ill and was in mild respiratory distress. She was

afebrile with a pulse rate of 76 beats/min, BP of 120/80 mmHg and a respiratory rate of 24 breaths/min. Respiratory sounds were not heard on lower two-thirds of the right hemithorax, posteriorly. The rest of the physical examination was normal.

The hemoglobin level was 10 g/dL, hematocrit was 30%, the WBC count was 7.80×10^3 cells/ μ L, and platelets were 242×10^3 cells/ μ L. Erythrocyte sedimentation rate was 48 mm per hour. Urinalysis, routine serum chemistry findings and ECG findings were normal.

Her pulmonary function test revealed a moderate degree of restrictive pattern: FEV1 of 1.05 L (52% predicted); FVC, 1.10 L (51.0%); and FEV₁/FVC, 105%. The measurement of arterial blood gas levels on room air revealed the following: pH 7.52, PaO₂ 61 mmHg, PaCO₂ 32 mmHg, HCO₂ 24 mmol/L, and arterial O₂ saturation, 91.5%.

Her chest roentgenogram at admission showed homogenous opacification of the right lower hemithorax without mediastinal shift (Figure 1). A thoracic computed tomography (CT) scan (Figure 2) demonstrated a mass that occupied almost entire right lower hemithorax and there was neither pleural effusion nor pleural thickening. Fiberoptic bronchoscopy

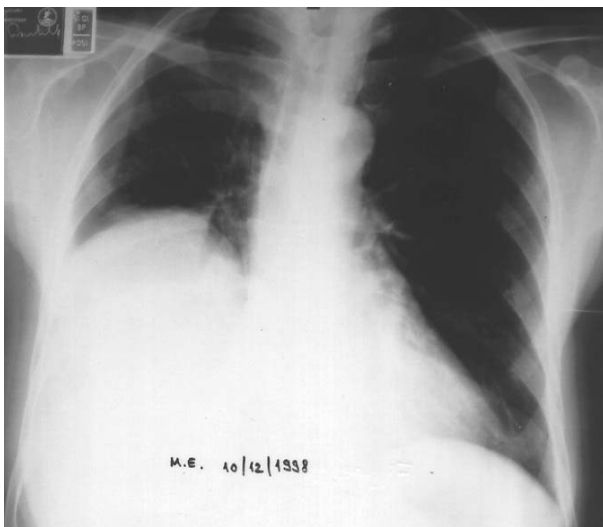


Figure 1. Initial chest radiograph showing homogenous opacification of the right lower hemithorax without mediastinal shift.

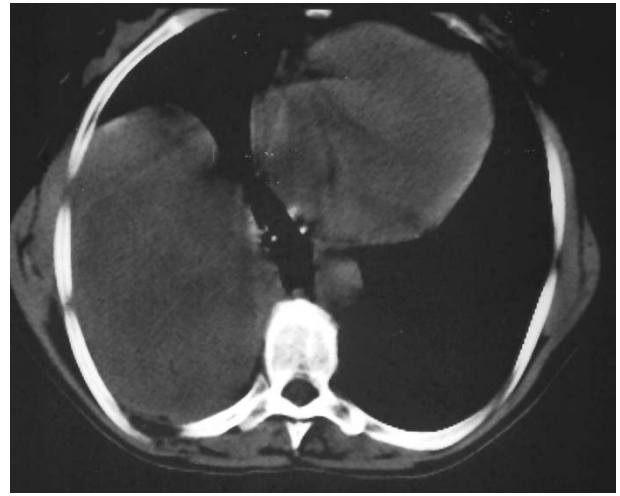


Figure 2. Initial chest CT revealing a well defined mass that occupied almost entire right lower hemithorax. There was neither pleural nor mediastinal involvement

revealed an extrinsic compression of the right lower lobe bronchus but there was not any endobronchial lesion or mucosal irregularity. CT-guided transthoracic biopsy was performed and histopathologic examination of the biopsy resulted as fibrous tumor of the pleura. Results of the staging procedures including abdominal and cranial CT, bone scintigraphy were normal. A right thoracotomy performed on January 7th 1999 revealed a firm well-circumscribed tumor that was attached to the visceral pleura by a short vascular pedicle and there was neither invasion to contiguous structures nor pleural effusion. Resection of the tumor with pedicle was easily achieved and the contiguous atelectatic part of the right lung expanded after resection of the tumor. Histopathologic examination of the surgical specimen (Figure 3) revealed fascicles of spindle cells which had neither mitotic figures nor nuclear atypia. There was little amount of collagen among the spindle cells (Figure 4). Cytokeratin, CEA, protein S-100 and epithelial membrane antigen were negative, but CD34 was positive. These immunohistopathologic findings were compatible with solitary fibrous tumor of the pleura.

During follow-up period, a remarkable improvement was noted in the clinical,

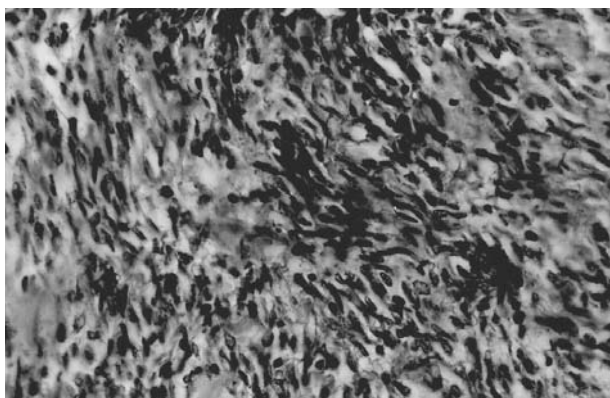


Figure 3. Fascicles of spindle cells which had neither mitotic figures nor nuclear atypia (x 200 Hematoxyline Eosine)



Figure 4. There was little amount of collagen among the spindle cells (x 200 Gomori trichrom staining).

physiological [pulmonary function tests: FEV₁ of 1.95 L (91.7% predicted); FVC, 2.71 L (96.2%); and FEV₁/FVC, 97.9% and arterial blood gas values: pH 7.40, pCO₂ 39 mmHg, pO₂ 91 mmHg, HCO₃ 24 mmol/L, arterial O₂ saturation, 96%] and radiologic picture. She has remained asymptomatic and has not experienced a recurrence for a follow-up of 58 months (Figure 5).

DISCUSSION

Solitary fibrous tumors of the pleura are rare and occurs slightly more often in females than males. The mean age at presentation is about 50 years but it can be seen at any age⁽¹⁾. Our patient was 60 years-old at the time of diagnosis. The etiology is unknown in the majority of cases but there were papers reporting

development of the tumor after radiotherapy to the chest wall. The tumor is not related with cigarette smoking or asbestos exposure.

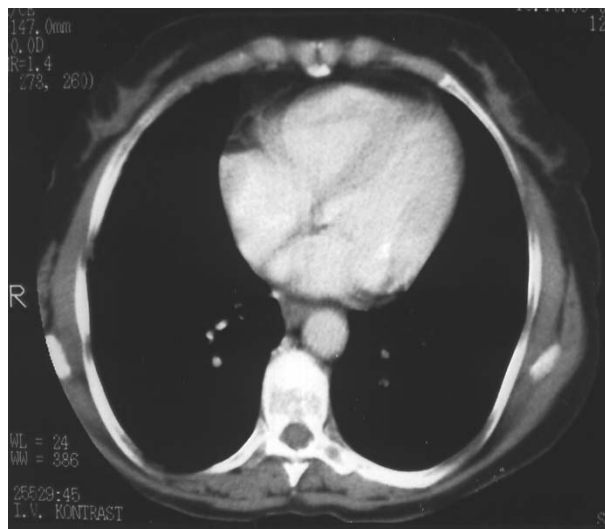


Figure 5. Control thorax CT obtained 58 months after surgery is normal

Clinical presentation varies depending on size and intrathoracic localisation⁽³⁾. Most patients have little or no symptoms at the presentation. Most patients are asymptomatic but especially patients with large tumors complain of cough, chest pain and dyspnea. The tumors may enlarge rapidly and may induce paraneoplastic syndromes, such as hypoglycemia, digital clubbing and osteochondropathy⁽⁴⁾. Although hypertrophic osteoarthropathy is common and its presence in a patient with a large intrathoracic mass should suggest its diagnosis, there were neither symptoms nor signs of hypertrophic osteoarthropathy in our case.

Radiographically, tumors are well-circumscribed, smooth, or lobulated, pleura-based masses of homogenous density ranging in diameter from 1 to 40 cm. Pleural effusion was reported in 17% of the patients (especially in malignant types)⁽⁵⁾. There was no pleural effusion in the case. In thorax CT, most tumors larger than 5 cm in diameter form acute angles with the chest wall. Presence of tapering margins and displacement of adjacent lung parenchyma are helpful signs for

determining the extrapulmonary nature of the tumor, as in our case.

Solitary fibrous tumors of the pleura arise from a pedicle on the visceral pleural surface, but rarely invade the visceral pleura. Grossly, the tumors are usually well delimited from contiguous structures. Histologically, solitary fibrous tumors of the pleura originate from submesothelial connective tissue and the tumor consists of haphazardly arranged fascicles of spindle cells and there is a variable amount of dense collagenous material between the spindle cells. Although it is not the rule, abundance of mitotic figures and nuclear atypia usually imply an aggressive behaviour of the tumor. In our case, tumor was attached to the visceral pleura by a short vascular pedicle and consisted of mainly spindle cells with little amount of collagen and also neither mitotic figures nor nuclear atypia were not detected.

Immunohistochemical examination usually shows expression of the tumor cells for CD34, bcl-2, keratin and CD31 are negative⁽⁶⁾.

Treatment is always surgical. Surgical resection of solitary fibrous tumors of the pleura usually results in complete cure, especially tumors with a well-defined pedicle, but if initial surgery is inadequate local recurrence can occur. Complete resection of the tumor is the best prognostic factor. Close observation is justified for tumours measuring >10 cm in diameter, because this predicts shorter disease-free survival and a high tendency of local recurrence and/or metastasis⁽⁷⁾. The patient is completely healthy without recurrence at 58th month of the surgical resection.

In conclusion, solitary fibrous tumor of the pleura should be considered in differential diagnosis of intrathoracic large tumors, especially in nonsmoker patients. Surgery is usually curative for benign forms.

Geliş Tarihi : 22.12.2003

Yayına kabul tarihi : 11.06.2004

Yazışma adresi:

Dr. Serhat FINDIK

Ondokuz Mayıs Üniversitesi, Tıp Fakültesi,

Göğüs Hastalıkları Anabilim Dalı,

55139 Kurupelit, SAMSUN

SAMSUN

REFERENCES

1. Briselli M, Mark EJ, Dickersin GR. Solitary fibrous tumors of the pleura: eight new cases and review of 360 cases in the literature. *Cancer* 1981; 47: 2678-2689.
2. England DM, Hochholzer L, McCarthy MJ. Localized benign and malignant fibrous tumors of the pleura. A clinicopathologic review of 223 cases. *Am J Surg Pathol* 1989; 13: 640-.
3. Robinson LA, Reilly RB. Localized pleural mesothelioma. The clinical spectrum. *Chest* 1994; 106: 1611-1615.
4. Meyer M, Krause U. Solitary fibrous tumors of the pleura. *Chirurg* 1999; 70: 949-952.
5. Rena O, Filosso PL, Papalia E, et al. Solitary fibrous tumour of the pleura: surgical treatment. *Eur J Cardiothorac Surg* 2001; 19: 185-189.
6. Hummel P, Cangiarella JF, Cohen JM, et al. Transthoracic fine-needle aspiration biopsy of pulmonary spindle cell and mesenchymal lesions: a study of 61 cases. *Cancer* 2001; 93: 187-198.
7. Gold JS, Antonescu CR, Hajdu C, et al. Clinicopathologic correlates of solitary fibrous tumors. *Cancer* 2002; 94: 1057-1068.