

Intentional Hand Tremor Due to Thalamic Astrocytoma in Childhood: A Case Report

Alparslan ŞENEL, MD., Cengiz ÇOKLUK, MD., Yurdal SERARSLAN, MD.,
Lütfi İNCESU¹, MD., Filiz KARAGÖZ, MD.²,

Ondokuz Mayıs University, Medical Faculty, Department of Neurosurgery, Radiology¹
and Pathology², SAMSUN

✓ The case report of an 11 years old girl with intentional tremor of the right hand due to a low-grade astrocytoma in the left thalamus is presented. The tumor was resected by the left sylvian fissure approach. We presented this case as rarely seen symptom well childhood as.
Key words: *Intentional tremor, movement disorder, thalamic astrocytoma*

✓ **Çocukluk Yaş Grubunda Talamik Astrositoma Bağlı İntansiyonel El Tremoru**
Burada sol talamik yerleşimli düşük gradeli astrositoma bağlı sağ kolda intansiyonel el tremoru olan 11 yaşında kız olgu sunulmaktadır. Tümör sol silvian fissür girişimi ile çıkarıldı. Çocukluk yaş grubunda nadir görülen bu semptom literatür bilgilerinin ışığı altında tartışılmaktadır.
Anahtar kelimeler: *İntansiyonel tremor, hareket bozuklukları, talamik astrositom*

INTRODUCTION

Supratentorial tumors comprise approximately 40% of brain tumors in children; of these about one-half are of neuroectodermal origin^(1,2).

Hemispheric supratentorial astrocytomas account for some 20% of supratentorial tumors in childhood. The peak incidence in children seems to be at around 7 to 8 years and there is a slight preference for males⁽³⁾.

Tumors of the thalamus and the basal ganglia are relatively rare. They are estimated to make up 1-2.5% of intracranial tumors. Majority of these neoplasms are benign or malignant astrocytomas^(2,4-6). The tremor in the tumors of the thalamus and the basal ganglia is rare in childhood.

CASE REPORT

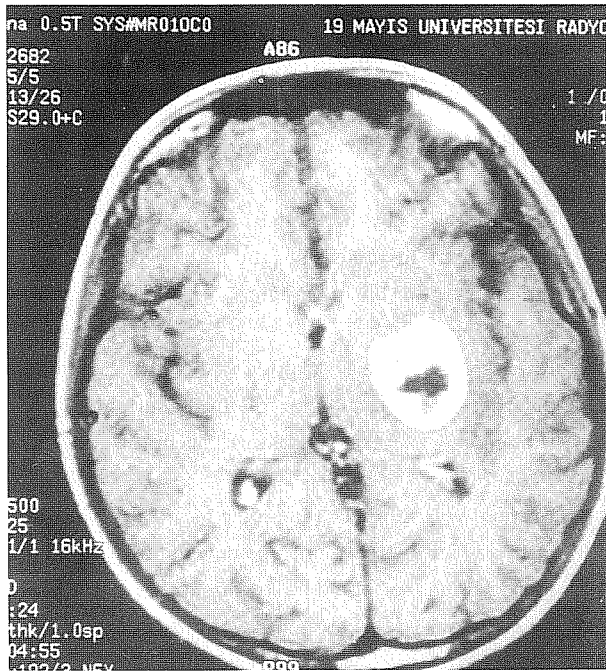
An 11 years old girl was admitted with 14 months history of mild shaking on the right

hand. The neurologic examination showed papiledema and intentional tremor on the right hand without paresis.

The magnetic resonance imaging (MRI) sequences showed a low signal intensity lesion on T1 weighted and high-signal intensity on T2 weighted sequences, with a maximum diameter of 2.5 cm in the left thalamus. Enhanced MRI (with Gd-DTPA) shows a ring shaped high-signal intensity lesion with a low signal intensity area inside the ring (Figure 1).

Surgery was performed and the tumor removed totally through a right pterional approach (through the sylvian fissure). Postoperative course is uneventful and the tremor has been totally improved.

On microscopic examination; glial tissue showed increased cellularity because of slightly enlarged neoplastic astrocytes expanding in an irregular and patternless



in fashion. There were no mitoses, vascular endothelial proliferation or necrosis thus the lesion was diagnosed as low-grade astrocytoma (Figure 2).

Postoperatively 6000 cGy radiotherapy was performed.

At the central one year later she managed with no antiepileptic agent and remained symptom free.

DISCUSSION

As movement disorders are often related to dysfunction or structural lesions of the basal ganglia and the thalamus, a high incidence might be expected in intrinsic tumors, but paradoxically they seem to be infrequent⁽⁶⁾.

The frequency reported for movement disorders in patients with tumors of the basal ganglia and the thalamus varies considerably and ranged from 1 to 33%^(4,6,7).

Mark Brenstein et al⁽²⁾ found the arm

Figure 1. The left-sided thalamic located and markedly peripherally enhancing tumor is seen in axial contrast-enhanced spin-echo T1-weighted images.

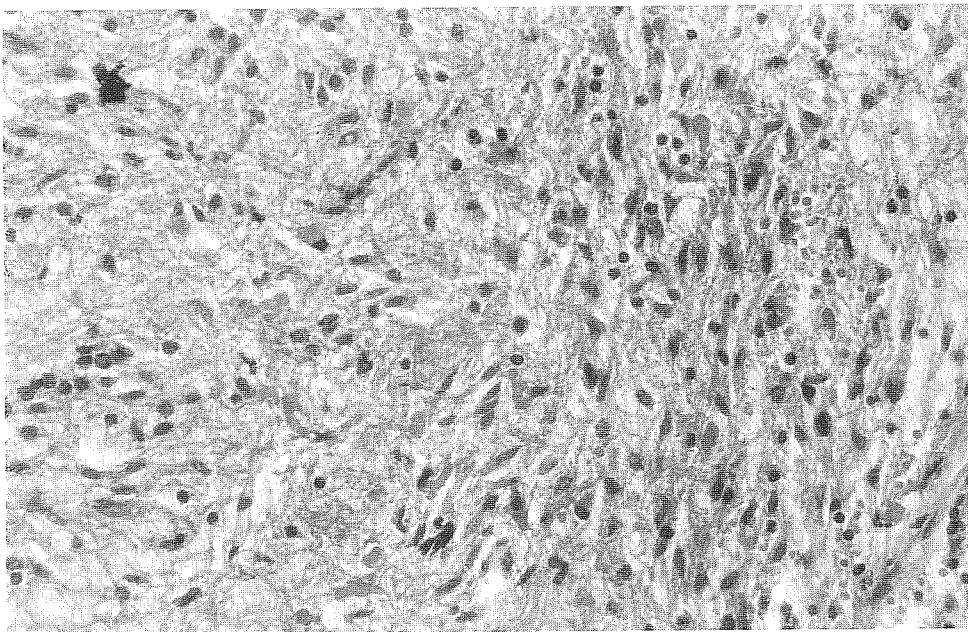


Figure 2. Low-grade astrocytoma. Increased cellularity and slightly enlarged neoplastic cells (H&E, X400).

tremor in 3 cases from a series of 60 children with thalamic tumors (5%).

The tremor or tremor/parkinsonism was reported in 59 cases (for all ages) with tumors of the basal ganglia and the thalamus in the literature from 1992^(6,8).

The real controversy regarding irradiation applies to the management of children with low-grade tumors. Incompletely and also gross totally excised astrocytomas carry malignancy potential and they may invade spinal cord^(9,10). A number of reports demonstrate a beneficial effect of radiation therapy on incompletely excised astrocytomas^(11,12).

We presented this case because of the thalamus and the basal ganglia and the tremor in these neoplasms are relatively rare especially in childhood.

Geliş tarihi : 25.12.1999

Yayına kabul tarihi : 03.06.1999

Yazışma adresi:

Dr. Alparslan ŞENEL

Ondokuz Mayıs Üniversitesi, Tıp Fakültesi,

Nöroşirürji Anabilim Dalı

55139 Kurupelit, SAMSUN

REFERENCES

- Hoffman HJ. Supratentorial brain tumors in childhood, in Youmans JR (ed): Neurological Surgery, 2nd ed Philadelphia WB Saunders, 1982; Vol 5, pp. 2702-2732.
- Bernstein M, Hoffman HJ, Halliday WC, et al. Thalamic tumors in children. J Neurosurgery 1984; 6: 649-656.
- Mercuri S, Russo A, Palma L. Hemispheric supratentorial astrocytomas in children. Long term results in 29 cases. J Neurosurgery 1981; 55: 170-173.
- Kelly PJ. Stereotactic biopsy and resection of thalamic astrocytomas. Neurosurgery 1989; 25: 185-195.
- Mc Girr SJ, Kelly PJ, Scheithauer BW. Stereotactic resection of juvenile pilocytic astrocytomas of the thalamus and basal ganglia. Neurosurgery 1987; 20: 447-452.
- Krauss JK, Nobbe F, Wakhloo AK, et al. Movement disorders in astrocytomas of the basal ganglia and thalamus. J Neurol Neurosurg Psychiatry 1992; 55: 1162-1167.
- Kraus JK, Braus DF, Mohadjer M, et al. Evaluation of the effect of treatment on movement disorders in astrocytomas of the basal ganglia and thalamus. J Neurol Neurosurg Psychiatry 1993; 56: 1113-1118.
- Kulali A, Tugtekin M, Ütkür Y, et al. Ipsilateral hemiparkinsonism secondary to an astrocytoma. J Neurol Neurosurg Psychiatry 1991; 54: 653.
- Shaw EG, Daumas-Duport C, Schetthauer BW, et al. Radiation therapy in the management of low-grade supratentorial astrocytomas. J Neurosurg 1989, 70: 853-861.
- Gajjar A, Bhargava R, Jenkins JJ. Low grade astrocytoma with neuroaxis dissemination at diagnosis. J Neurosurg 1995, 83: 67-71.
- Greenberger JS, Cassidy JR, Levene MD: Radiation therapy of thalamic, midbrain and brain stem gliomas. Radiology 1977; 122: 463-468.
- Marsa GW, Probert JC, Rubinstein LJ: Radiation therapy in the treatment of childhood astrocytic gliomas. Cancer 1973; 32: 646-655.