

A Giant Calculus Within A Congenital Urethral Diverticulum Presenting With Impotence

Dr. Şaban SARIKAYA, Dr. Mahmut ULUBAY, Dr. Mustafa YETER,
Dr. Sacit YILDIZ

Department of Urology, Faculty of Medicine, Ondokuz Mayıs University, SAMSUN

✓ We report a 28-year-old man with a giant calculus in his urethral diverticulum whose main complaint was impotence. Interestingly, he described improvement in his erectile function after the removal of the diverticulum and calculus.

Key words: Congenital urethral diverticulum, urinary calculus, impotence.

✓ Asıl yakınması impotans olan ve üretral divertikülü içinde dev taş saptanan 28 yaşında bir erkek olgu sunuldu. Divertikül ve taşın çıkarılmasının sonra erektil fonksiyonunda düzelme tanınması ilginç bulundu.

Anahtar Kelimeler: Konjenital üretral divertikül, üriner taş, impotans.

Urethral diverticulum in the male is very rare. It may be either congenital or acquired⁽¹⁻⁵⁾. Stone formation in a urethral diverticulum may be seen especially in ones with a narrow orifice⁽⁶⁻⁸⁾. Usual complaints of these patients are about voiding⁽¹⁻⁸⁾. Here we report a case who referred us with impotence.

Case report: A 28-years old male referred to us with his wife because of inability to have sexual intercourse for the last two years, since they got married. He told he did not have any sexual experience and he did not experienced even a rigid erection before the wedding either. There was no history of genital trauma, surgery, infection or voiding difficulty. On physical examination, there was a hard mass, 3 cm in diameter, at the peno-scrotal junction. The remainder of genital and systemic examinations were normal.

A plain film of the pelvis and a retrograde urethrography revealed a calculus located in a urethral diverticulum (Figure 1 and Figure 2). All of the laboratory findings, including testosterone and prolactin, were normal. Cystoscopy confirmed the presence of a

calculus via a 6 mm diverticular opening at ventral side of the penile urethra. The diverticulum was excised and removed together with the calculus. Urethral closure was performed over an 18 Fr Foley catheter. Recovery was uneventful. The urethral catheter was removed at postoperative 15th day and the patient voided normally. At his first control performed 2 weeks after he was discharged from the hospital the defined rigid erections and he told that he succeeded the coitus.

DISCUSSION

The etiology, diagnosis and management of urethral diverticula have been properly discussed in the literature⁽¹⁻⁸⁾. Here we needed to determine whether this situation can cause erectile dysfunction or not. The history obtained from the patient suggests a primary impotence because of its duration⁽⁹⁾. Unawareness of our patient of such a large calculus is interesting and this might have been as a result of his low socioeconomic situation. Thus, erectile dysfunction in psychogenic origin was considered in our case. For this reason, we planned to treat apparent

organic pathology at first, then to investigate the erectile disorder. However, the rapid improvement in erectile function lead us to think whether such a calculus can cause erectile dysfunction or not.

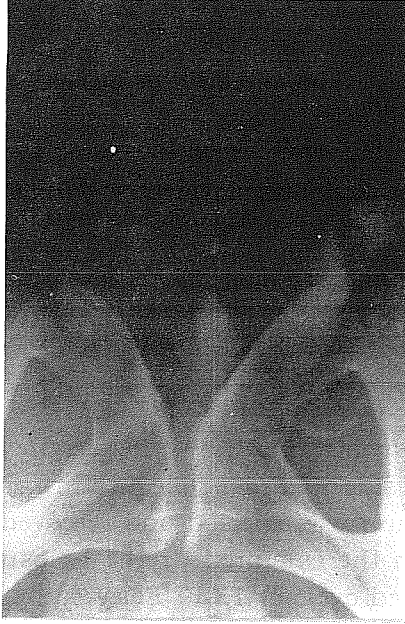

Figure :1. Appearance of the calculus on plain film.

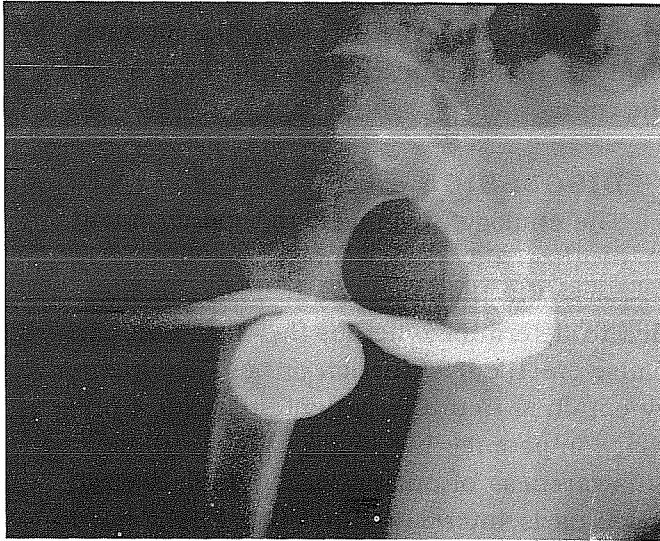


Figure :2. Retrograde urethrogram demonstrating the urethral diverticulum.

It's very difficult to make a comment because of the lack of the tests required for the classification of the erectile dysfunction in our patient. Neither a calculus, nor urethral diverticula have been never mentioned previously in the etiology of erectile disorders⁽¹⁰⁾. Theoretically, it is not impossible that this situation diminishes erectile function. Because, such a calculus enveloped within the Buck's fascia together with the cavernous bodies may prevent the stretching of elastic fibers of the tunica that is required for the maintenance of rigidity.

In conclusion; this case is one of the best examples stressing the importance of proper physical examination, so that, further unnecessary invasive tests could be avoided. Despite the latest developments, there are still some cases in whom the exact pathophysiology of erectile dysfunction cannot be fully understood.

Received: 10.04.1996

Accepted for publication: 06.05.1996

REFERENCES

1. Şen SE, İşeri C, Eryiğit M. Congenital urethral diverticulum in the male. *Urology* 1989, 34:129-130.
2. Tank SE, Anterior urethral valves resulting from congenital urethral diverticula. *Urology* 1987, 30:467-469.
3. Mohan V, Gupta SK, Cherian J, et al. Urethral diverticulum in male subjects: Report of 5 cases. *J Urol* 1980, 123:592-594.
4. Laudone VP, Green FK, Wyker Jr AW: Giant posterior urethral diverticulum after radical retropubic prostatectomy. *J Urol* 1980, 139:364-366.

5. Ortlip SA, Gonzales R, Williams RD: Diverticula of the male urethra. *J Urol* 1980, 124:350-355.
6. Khinev A, Gochev D, Ralichkova L: A case of a congenital diverticulum of the urethra combined with calculosis. *Khirurgiia-Sofiia* 1991, 44:57-59 (abstr).
7. Garmendia-Larrea JC, Lopez-Garcia JA, Arocena-Lanz F: Giant calculus in a diverticulum of the anterior urethra. *Actas Urol Esp* 1990, 14:200-201, (abstr).
8. Firlit C: Urethral abnormalities. *Urol Clin North Am* 1978, 5:31-41.
9. Stief GC, Bahren W, Scherb W, Gall Ho: Primary erectile dysfunction. *J Urol* 1989, 141:315-319.
10. Carrier S, Brock G, Kour NW, Lue TF: Pathophysiology of erectile dysfunction. *Urology* 1993, 42:468-481.

