

Scurvy Associated with Poliovirus Infection and Mimicking Paralytic Disease: A Diagnostic Challenge

Fadıl ÖZTÜRK, MD.¹, Feyzullah ÇETİNKAYA, MD.¹,

Muzaffer ESKİOCAK, MD.², Mustafa Bekir SELÇUK, MD.³,

^{1,3}Department of Pediatrics, and Radiology, Ondokuz Mayıs University Faculty of Medicine, Samsun

² Directorate of Mother and Child Health, and Family Planning, Samsun

✓ We present a case of aseptic meningitis due to vaccine poliovirus type 1 in a three-year-old female child with scurvy. This association, which has not been described before, may be caused by the altered immunity due to scurvy.

Key words: Scurvy, aseptic meningitis, poliovirus

✓ **Poliovirüs Enfeksiyonunun Eşlik Ettiği ve Paralitik Hastalığı Taklit Eden Skorbüt: Tanısal Bir Sorun**

Üç yaşında skorbütlü bir kız çocukta tip 1 aşı poliovirüsüne bağlı bir aseptik menenjit olgusu sunuyoruz. Daha önce tanımlanmamış olan bu birliktelik skorbütün bağışıklık sisteminde oluşturduğu değişiklikler sonucu ortaya çıkmış olabilir.

Anahtar kelimeler: Skorbüt, aseptik menenjit, poliovirüs

Although scurvy is a very rare disease, it is easily diagnosed if the physician keeps the possibility in mind. In a country where plentiful consumption of fresh fruits and vegetables, which are the principal sources of vitamin C, by all age groups, is a common practice, scurvy has a very low prevalence and thus a low suspicion index. A low index of suspicion for scurvy is a cause of misdiagnosis⁽¹⁾. Presence of an underlying illness in which paralysis is expected to occur is also another cause of misdiagnosis.

We report a patient with scurvy and aseptic meningitis due to vaccine poliovirus type 1 presenting with acute flaccid paralysis in lower extremities suggestive of acute paralytic poliomyelitis.

CASE REPORT

A three-year-old girl was admitted for three days of febrile illness, irritability, malaise, and sudden inability to stand and walk. Four months prior to the admission, she had received oral attenuated poliovirus vaccine (OPV) during a National Immunisation Campaign against poliomyelitis in Turkey. She had been vaccinated with OPV in the past (first dose at 2 months of age, the second and third doses at 1-month intervals thereafter). On admission she was distressed and agitated. Weight 11.700 kg, height 90.5 cm, weight for height >5th centile (according to National Center for Health Statistics standards). She had a fever of 37.4°C, many dental caries

resembling nursing bottle caries, and a nuchal rigidity. There was weakness of both legs, more marked on the right. The tendon reflexes in the legs were absent. The plantar responses were bilaterally flexor. No abnormality was found in the upper limbs. Sensory testing could not be performed since she was unable to cooperate. The patient had a microcytic anaemia with a haemoglobin level of 8.9 g/dl, hematocrit of 0.26 and mean corpuscular volume of 65 fl. White blood cell and platelet counts, erythrocyte sedimentation rate and antistreptolysine O titer were normal. Cerebrospinal fluid (CSF) analysis disclosed a mild pleocytosis with a leukocyte counts of 80/ μ l (lymphocytes predominate). The protein content was 47 mg/dl, and the glucose content 72 mg/dl. Blood and CSF cultures were negative.

In view of these symptoms and findings, our provisional diagnosis was an acute paralytic poliovirus infection. Fecal samples and throat swab specimens were taken from the patient for virus isolation. The vaccine virus strain poliovirus type 1 (Sabine like) was isolated [performed by National Public Health Institute (KTL), Finland] from the feces of the patient. On the second day of admission, her titers of antibody to PV1, PV2, and PV3 were 1:124, 1:512, and 1:32, respectively, and the antibody titer to PV1 had increased to 1:1024 by the day 30.

The child was observed for three days with the administration of analgesic and absolute bed rest. The fever dropt to normal levels within 72 hours but the irritability became progressively greater with appearance of swelling over the right thigh. The plain radiography of the right thigh performed to exclude underlying osteomyelitis of the femur revealed radiologic findings of acute scurvy (Wimberger's ring, subperiostal hemorrhage, Pelkan's spur,

Frankel's line and atrophic scurvy line) (figure 1 and 2). A more detailed nutritional history revealed that the patient had been fed with only boiled cow's milk, bread, and biscuits since birth. Serum vitamin C level was 0.03 mg/dl (normal, 0.2 to 2 mg/dl). On day 4, treatment with ascorbic acid was started at a dose of 300 mg twice a day. After

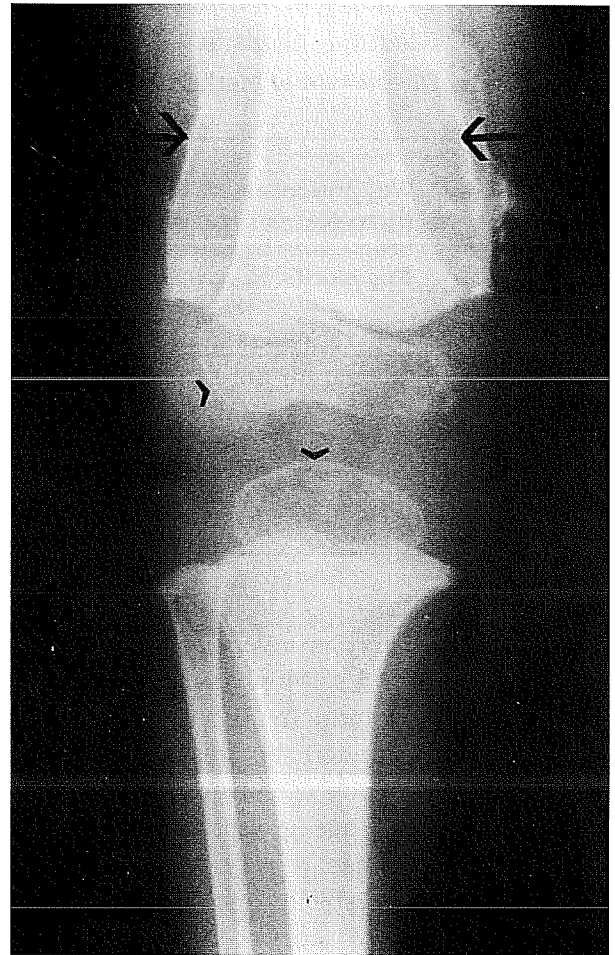


Figure 1. X-ray of the right femur with knee joint shows subperiosteal hemorrhage (arrows) and Wimberger's ring (arrowheads) characterized by osteoporosis at the end of the shaft and at the epiphyseal ossification center in contrast to the dense periphery.

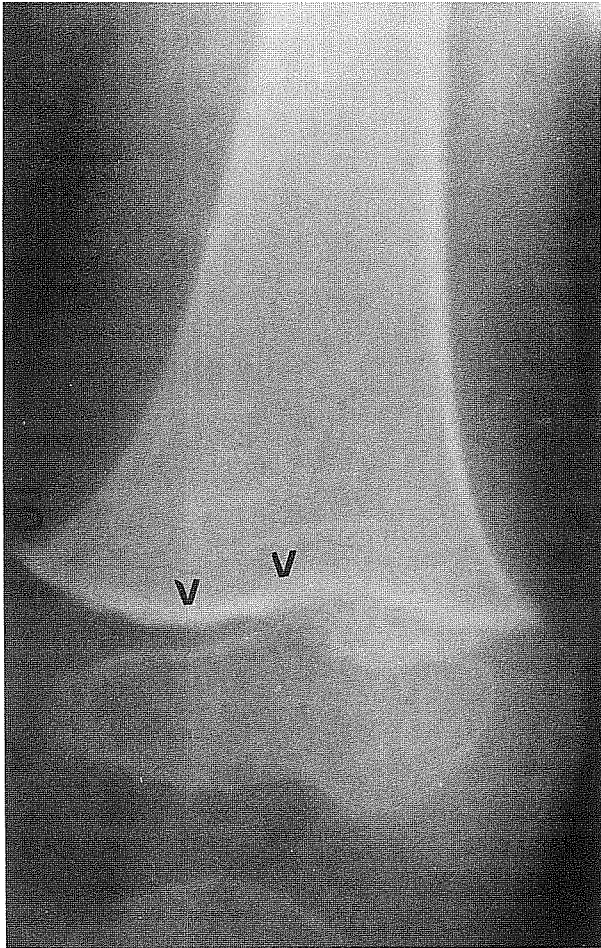


Figure 2. X-ray of the left femur shows Pelkan's spur (arrow) and a radiolucent zone-atrophic scurvy line on the diaphyseal side of the Frankel's line (arrowheads).

a week, she improved, gradually lost her irritability, and on the 10th day of treatment became mobile with complete remission of her neurological symptoms. On day 12, she was discharged, and maintenance treatment with ascorbic acid (300 mg/day) was prescribed. When reevaluated 2 weeks later, she looked very well, and viral cultures of the feces were negative.

DISCUSSION

Unlike most other animals, humans require vitamin C in the diet because of their inability to synthesise L-ascorbic acid. If the mother eats appropriate food, breast milk usually contains adequate vitamin C in contrast to low levels in cow's milk⁽²⁾. Vitamin C is a potent reducing agent that is easily oxidised and destroyed by heating. Deficiency of vitamin C leads to depression of osteoblastic activity and failure of bone matrix formation. Endochondral bone formation ceases and the bony trabeculae that have been formed become brittle and fracture easily. The periosteum becomes loosened, and subperiosteal hemorrhages occur, especially at the ends of the femur and tibia. Most of the clinical findings in scurvy relate to the importance of vitamin C in the metabolism of collagen. The tendencies to hemorrhage, defective tooth dentin, and loosening of the teeth are caused by deficient collagen⁽²⁾. Anaemia is present in up to 75% of patients with scurvy. The anaemia is multifactorial and may relate to blood loss, dietary deficiencies, reduced intracellular iron availability, and decreased amounts of the active form of folate^(2,3). Scurvy may occur at any age but in children the majority of cases occur in infants 6-24 months of age⁽²⁾. Early signs of scurvy are often seen in the skin. Subcutaneous and mucosal bleeding leads to petechiae, purpura, ecchymoses, and gingival haemorrhage. Pain resulting in pseudoparalysis is a common symptom.

When a person susceptible to infection is exposed to poliovirus, one of the following responses may occur: (I) inapparent subclinical infection (90%-95% of cases), (II) minor illness (abortive poliomyelitis) (4%-8% of cases), (III) aseptic meningitis (0.5%-1% of cases), or (IV) paralytic poliomyelitis (0.1%-1% of cases)⁽⁴⁾. Nonspecific findings,

including fever, malaise, anorexia, listlessness, headache, sore throat, nausea, vomiting, and constipation are symptoms of the minor illness and resolve in a few days. In addition to these symptoms and signs, if the patient has stiffness and pain in the back and neck, the diagnosis is aseptic meningitis⁽⁴⁾. Occasionally; there is mild muscle weakness or transient paralysis. The disease lasts 2 to 10 days, and recovery is almost always complete⁽⁴⁾. The CSF contains increased number of leukocytes-usually 10 to 200/ μ l, seldom more than 500/ μ l. The protein content in the CSF is elevated whereas the glucose content remains normal. Neutralising antibodies in serum appear early and are usually already detectable at the time of hospitalisation. Paired serum specimens are required to show a rise in antibody titer⁽⁴⁾. Poliovirus can be recovered from the feces, throat, urine, and rarely from CSF. In children with aseptic meningitis caused by poliovirus, the rate of positive cultures from rectal swabs has been 50% to 60%, which is more than that for CSF (30%), throat (20%), or urine (20%) cultures⁽⁵⁾.

OPV multiplies, infects and thus immunises. In this process, infectious progeny of the vaccine virus are disseminated in the community. Although the viruses, particularly types 2 and 3, mutate in the course of their multiplication in vaccinated children, only extremely rare cases (about 1 per 760,000 children receiving their first dose) of paralytic poliomyelitis have occurred in recipients of OPV or their contacts^(4,6). For subsequent doses, the risk is substantially lower for both recipients and contacts. For immunodeficient persons, the risk is 3200-to 6800-fold higher than that in immunologically healthy OPV recipients⁽⁶⁾. In recipients of OPV, the virus persists in the throat for 1 to 2 weeks; it is excreted in the feces for several weeks⁽⁵⁾.

Onorato et al⁽⁷⁾ reported that the mean duration of virus shedding was 6.4 days (median, 7 days) in OPV recipient children. In their studies, virus was isolated from only one OPV vaccine (1%) 21 days after challenge. No infected immunocompetent persons have been known to be permanent carriers, but immunodeficient patients excrete virus for prolonged periods⁽⁵⁾. Our patient who lives in a remote village from town had received OPV four months before the admission, and there was no person recently received OPV in her environment, and virus could not be isolated from her family members. Therefore, she had no immunodeficient conditions except for scurvy to explain the prolonged virus excretion.

Although scurvy has been documented since the time of Hippocrates, the immunological aspects of this ancient disease has not been completely understood yet. In most patients with scurvy, investigation has been limited to standard laboratory tests or to exploration of ascorbic acid metabolism. The effects of scurvy on immune system have not yet been completely studied. Several studies have indicated that vitamin C may play a role in infections other than those of the common cold viruses. Anderson⁽⁸⁾ reported that vitamin C enhanced production of interferon in both cell cultures and animal models. Grob and et al⁽⁹⁾ have suggested that vitamin C deficiency plays a role in defective interferon production. It has recently been suggested that vitamin C (1 g/day) treatment is beneficial for recurrent furunculosis in patients with impaired neutrophil functions⁽¹⁰⁾. Thus vitamin C should be related with several aspects of immune response.

In conclusion, scurvy may occur due to improper food intake even in countries with high dietary vitamin C consumption. In the presented case, although coexistence of

scurvy and aseptic meningitis due to vaccine virus may be incidental, it is also possible that vaccine virus infection and prolonged virus excretion developed in the altered immunity due to scurvy. In expanded programme on immunisation, although WHO does not consider malnutrition to be a contraindication for the administration of live vaccines to children, we think that, until immunological changes in scurvy are clearly documented, the children with scurvy should not be vaccinated with live viral vaccines unless the disease is treated.

Geliş tarihi : 22.04.1998

Yayına kabul tarihi : 19.06.1998

Address for correspondence:

Dr. Fadıl ÖZTÜRK

Ondokuz Mayıs Üniversitesi, Tıp Fakültesi,

Çocuk Sağlığı ve Hastalıkları Anabilim Dalı

55139 Kurupelit, SAMSUN

REFERENCES

1. Ramar S, Sivaramakrisman V, Manoharan K. Scurvy-a forgotten disease. *Arch Phys Med Rehabil* 1993; 74: 92-95.
2. Barness LA. Nutrition and nutritional disorders. In: Behrman RE, ed. *Nelson. Textbook of Pediatrics*. 14th ed. Philadelphia: WB Saunders, 1992: 105-46.
3. Stokes PL, Melikian V, Leeming RL, et al. Folate metabolism in scurvy. *Am J Clin Nutr* 1975; 28: 126-129.
4. Melnick JL. Current status of poliovirus infections. *Clin Microbiol Rev* 1996; 9: 293-300.
5. American Academy of Pediatrics. Summaries of infectious diseases. In: Peter G, ed. 1994 Red Book: Report of the Committee on Infectious Diseases. 23rd ed. Elk Grove Village, IL: American Academy of Pediatrics; 1994: 379-386.
6. Committee on Infectious Diseases, American Academy of Pediatrics. Poliomyelitis prevention: Recommendations for use of inactivated poliovirus vaccine and live oral poliovirus vaccine. *Pediatrics* 1997; 99: 300-305.
7. Onorato IM, Modlin JF, McMean AM, et al. Mucosal immunity induced by enhanced-potency inactivated and oral polio vaccines. *J Infect Dis* 1991; 163: 1-6.
8. Anderson R. Effect of ascorbate on normal and abnormal leukocyte functions. *Int J Vitam Nutr Res* 1982; 3 (suppl 23): 23-34.
9. Grob JJ, Collet-Villette AM, Aillaud MF and et al. Spontaneous adult scurvy in a developed country: new insight in an ancient disease. *Arch Dermatol* 1990; 126: 249-251.
10. Levy R, Shriker O, Porath A, et al. Vitamin C for the treatment of recurrent furunculosis in patients with impaired neutrophil functions. *J Infect Dis* 1996; 173: 1502-1505.

