

## Treatment of Tuberculous and Nontuberculous Psoas Abscesses with Percutaneous Catheter Drainage

Murat DANACI, MD.<sup>1</sup>, Ümit BELET, MD.<sup>1</sup>, Hüseyin AKAN, MD.<sup>1</sup>,  
Mustafa Bekir SELÇUK, MD.<sup>1</sup>, T. Nedim KARAİSMAİLOĞLU, MD.<sup>2</sup>,  
Ersan ELÇİM, MD.<sup>1</sup>, Murat BAŞTEMİR, MD.<sup>1</sup>,

*Ondokuz Mayıs University, Medical School, Department of Radiology<sup>1</sup>, and  
Orthopaedics<sup>2</sup>, SAMSUN*

✓ There are operative and non operative approaches in the treatment of psoas abscesses. The aim of this study was to assess the utility of the percutaneous catheter drainage in the tuberculous and nontuberculous psoas abscesses.

Eight patients with psoas abscesses were treated with computed tomography and ultrasonography guided drainage. Antituberculous or antibiotic chemotherapy was given to all patients after the drainage.

Six patients had tuberculous psoas abscess and two patients had pyogenic psoas abscess. All abscesses were unilateral. There was vertebral involvement in five patients with tuberculous abscesses, but they did not have vertebral instability and neurologic deficit. Mean drainage duration was 9 days and mean drained abscess volume was 85 ml. There was no complication and death. None of the cases required surgery. Recurrence was not detected in clinical follow-up and the computed tomographic examination.

We consider that percutaneous abscess drainage with chemotherapy should be the first choice of treatment method in selected cases with psoas abscesses that do not have vertebral instability, and neurologic deficit.

**Key words:** *Percutaneous abscess drainage, psoas abscess, tuberculosis, computed tomography, ultrasonography.*

### ✓ **Tüberküloz ve Pyojenik Psoas Abselerinde Perkütan Kateter Drenajı**

Psoas abselerinin tedavisinde operatif ve operatif olmayan yaklaşımlar mevcuttur. Bu çalışmanın amacı tüberküloz ve pyojenik psoas abselerinin tedavisinde, perkütan kateter drenajının etkinliğinin araştırılmasıdır.

Sekiz psoas abseli hastada ultrasonografi ve bilgisayarlı tomografi eşliğinde perkütan drenaj uygulandı. Tüm hastalara drenajdan sonra antitüberküloz veya antibiyotik tedavisi uygulandı

Altı hastada tüberküloz, iki hastada ise pyojenik abse saptandı. Tüm abseler tek taraflı idi. Tüberküloz psoas abseli beş hastada vertebral tutulum olmasına rağmen vertebral instabilite ve nörolojik kayıp saptanmadı. Ortalama drenaj volümü 85 ml, drenaj süresi 9 gün idi. Komplikasyon görülmedi. Hastaların hiçbirinde cerrahi tedavi gerekmedi ve takiplerde nüks tesbit edilmedi.

Psoas abselerinde, nörolojik kayıp ve vertebral instabilite bulunmayan seçilmiş vakaların tedavisinde perkütanöz kateter drenajı ve antibiyotik tedavisinin ilk seçilmesi gereken yöntem olduğunu düşünüyoruz.

**Anahtar kelimeler:** *Perkütan abse drenajı, psoas absesi, tüberküloz, bilgisayarlı tomografi, ultrasonografi*

## INTRODUCTION

The treatment of psoas abscesses could be either operative or non operative. The aim of this study was to assess the utility of the percutaneous catheter drainage in the tuberculous and nontuberculous psoas abscesses. Tuberculous has become an important public health problem in Turkish society and other developing countries for the last decade. There has been an increase in the number of cases of tuberculosis since 1984. 30% of world population have been infected by the mycobacteria tuberculosis<sup>(1)</sup>. Percutaneous abscess drainage (PAD) has quickly established as the primary drainage procedure for abscess involving most body location<sup>(2)</sup>. Treatment of spinal tuberculosis has fluctuated between operative and non operative approaches over the years<sup>(3)</sup>. Percutaneous catheter drainage with antituberculous treatment has appeared as a new practical approach in the management of tuberculous psoas abscesses. However the utility of PAD in the management of tuberculous psoas abscesses is less known<sup>(4)</sup>. Our purpose was to determine the utility of PAD in the management of tuberculous and non tuberculous psoas abscesses with or without vertebral lesion that do not cause vertebral instability. Eight patients with psoas abscesses were treated with computed tomography and ultrasonography guided drainage.

## MATERIALS AND METHODS

Eight patients with psoas abscesses were treated with computed tomography (CT) and ultrasonography (US) guided drainage for 2 years (seven patients with CT, one patient with US). These patients presented with fever, back pain, and weight loss. The age of the patients ranged from 8 to 60 years (mean: 44 years). Six patients were female

and two patients were male. There were no multiloculated abscesses. But one patient with pyogenic abscess had two abscesses in the right psoas muscle. Two catheters were used in this patient. Drainage of abscess was accomplished by posterior approach. Single lumen catheter (12-14 F) was used for the drainage. Under local anesthesia, with the guidance of US or CT, first, 18 Gauge needle with styled was inserted into the cavity. Then, styled was removed and the sheath left in the cavity, and 0.038 inch guide wire was inserted into the cavity. After dilatation with different dilators, catheter was placed into the abscess and guide wire was removed. The catheter was irrigated with saline solution. The catheter was removed under CT or US control, later 7-12 days.

## RESULTS

The patients' information are presented in Table. Six patients had tuberculous psoas abscess and two patients had pyogenic abscess. Six patients with tuberculous psoas abscess had positive culture or microscopic examination. Staphylococcus aureus and alpha hemolytic streptococcus were shown in two patients with pyogenic abscess (Figure 1) Except for two, other patients with tuberculous psoas abscess had vertebral erosion and/or paravertebral abscess between the levels T12-L5 vertebrae (Figure 2). The bony lesion in the vertebra caused no serious disturbance in the vertebral stabilization. There was no neurologic deficit in our cases. One patient with tuberculous abscess had no vertebral lesion and another patient with tuberculous abscess was operated due to the vertebral involvement three months ago. All patients had unilateral abscess. Three abscesses were in the left psoas and five were in the right psoas. Duration of drainage ranged from 7 to 12

**Table.** Patients' Informations.

No	Age, sex	Location	Organism	Vertebral Lesions	Catheter size (F)	Drainage duration (day)	Follow-up duration (month)	Drainage volume (ml)	Guide
1	8- F	Left	M.Tbc	TB. Spond.	12	12	6	40	CT
2	55- F	Left	Stf.Au	-	14	10	8	200	US
3	60- F	Right	M.Tbc	TB. Spond.*	14	11	7	90	CT
4	41-M	Right	M.Tbc	-	12	7	8	80	CT
5	50- F	Right	M.Tbc	TB. Spond.	12	10	9	75	CT
6	53-M	Right	M.Tbc	TB. Spond.	14	8	20	70	CT
7	55- F	Left	M.Tbc	TB. Spond.	14	10	24	65	CT
8	30-F	Right	A.He.St	-	14	8,7	3	90,60	CT

M.Tbc: Mycobacterium tuberculosis

TB. Spond: Tuberculous spondylitis

\*: Operated

Stf.au: Staphylococcus aureus

A.He.St: Alpha hemolytic streptococcus

days (mean: 9 days). The volume of abscesses changed between 40 to 90 ml in the tuberculous abscesses and 80 to 200 ml in pyogenic abscesses (mean: 85 ml). Antituberculous therapy was given to all of the patients with tuberculous psoas abscess. Four patients have taken antituberculous therapy since the drainage procedure. Antibiotic therapy was given to two patients with pyogenic abscess for 3 weeks. Hospitalization period changed from 10-30 days. Patients were followed by the orthopedic clinic during this period. The drainage procedure was well tolerated by all patients. There was no recurrence in CT follow-up from 3 to 24 months and no complication occurred after the drainage procedures in the hospital and in the follow-up.

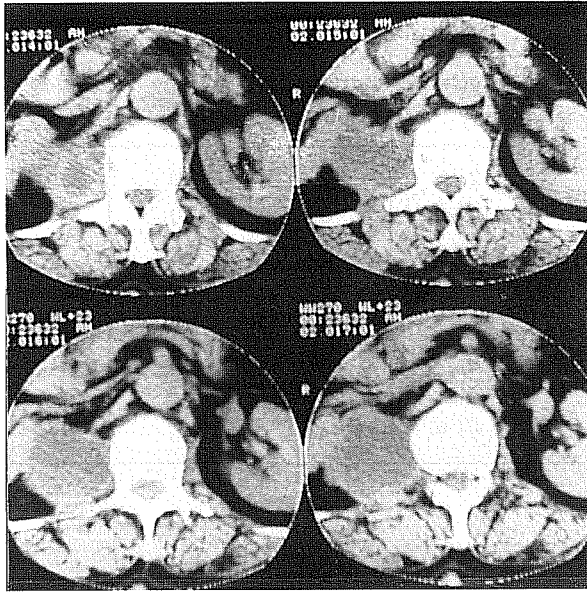
## DISCUSSION

The psoas muscle originates from the transverse processes of the twelfth thoracolumbar vertebrae. The fibers then

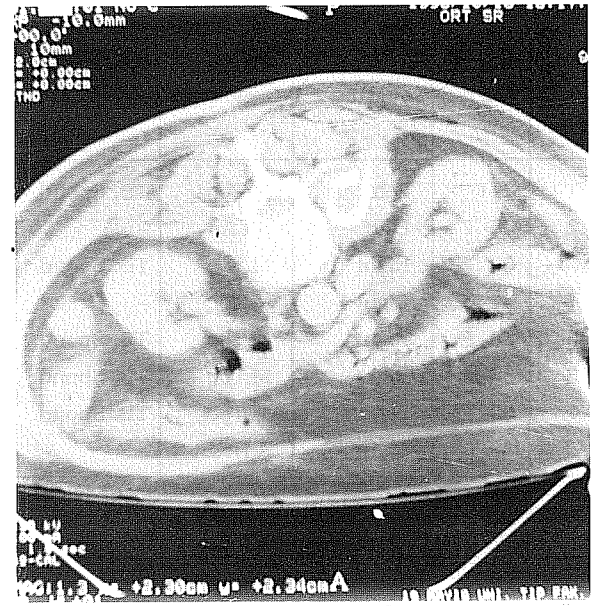
pass along the iliac bone and beneath the inguinal ligament to insert on the lesser trochanter of the femur. The psoas compartment is bordered posteromedially by the quadratus lumborum muscle and spine and laterally by the posterior perirenal fascia and perirenal space and its contents<sup>(5)</sup>.

A primary psoas abscess has no obvious infection focus. The common pathogen is staphylococcus aureus (84% of all). Secondary psoas abscess is defined as occurring by direct spread from contagious structures. Several causes are described, the most common being Crohn's disease (60%). Others include appendicitis, colon disorders, neoplasm, disc infection, osteomyelitis, pyonephrosis and tuberculosis.

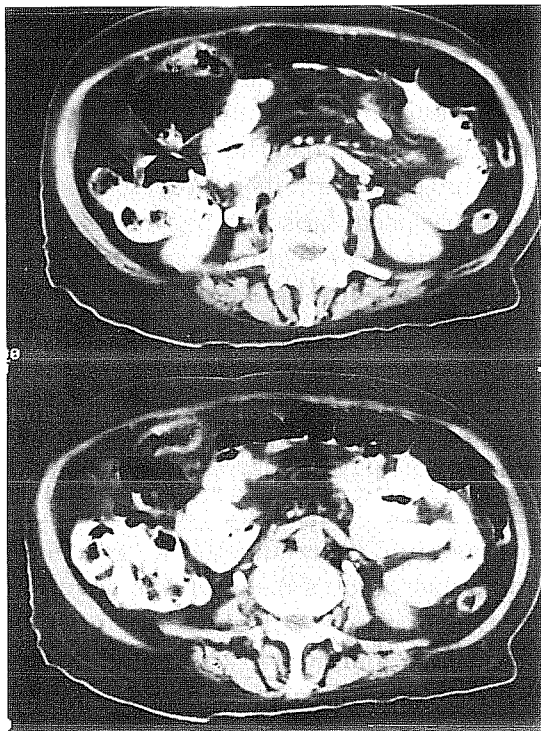
Tuberculosis (Pott's disease) was once the main cause of the psoas abscess, but it is rare now. A total 434 cases of psoas abscesses have been reported<sup>(6)</sup>. Spinal tuberculosis is the most common and serious form of skeletal tuberculosis. The major site of infection is the vertebral body of the



(a)

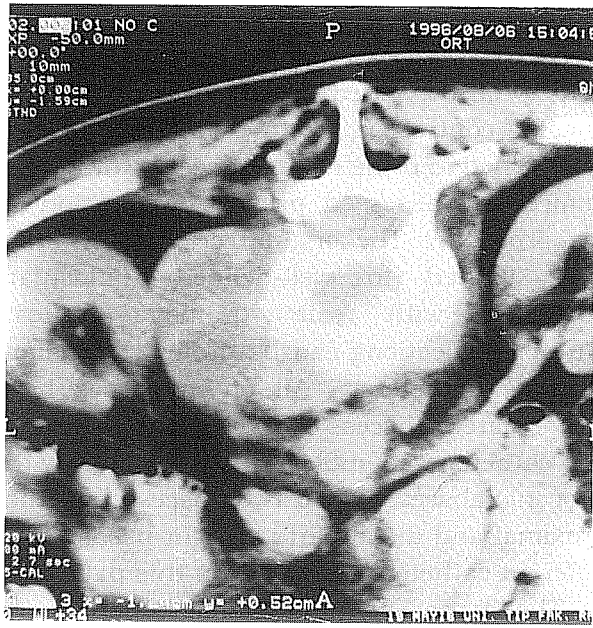


(b)

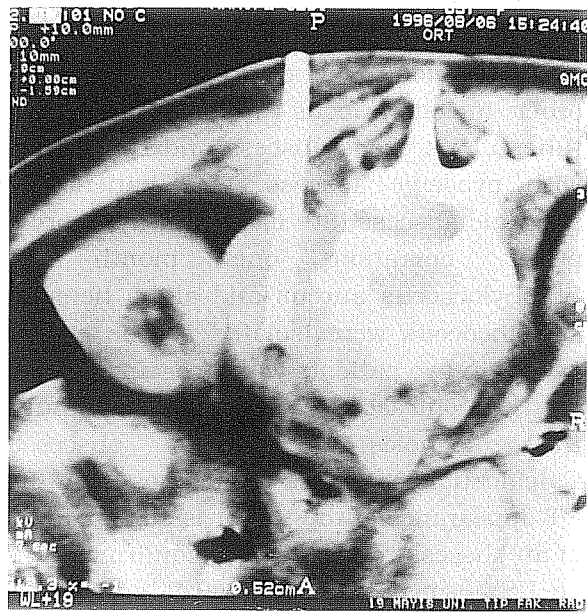

(c)

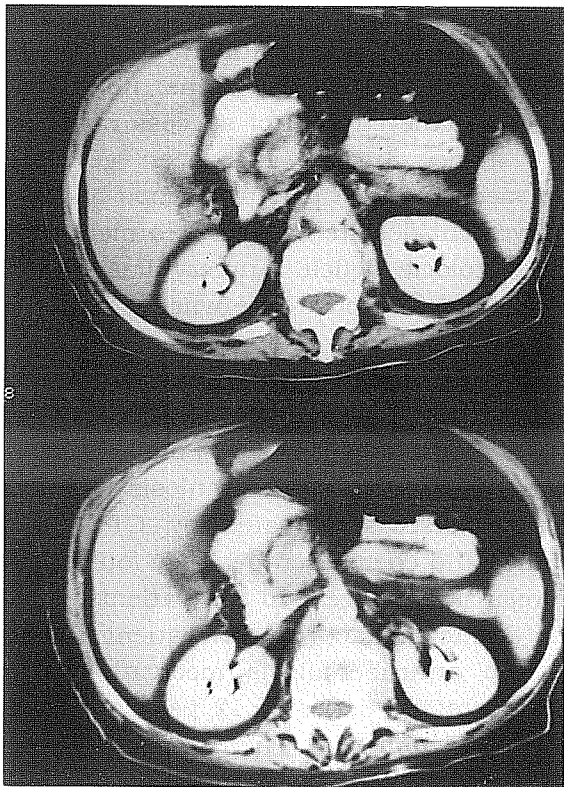
**Figure 1.** (a) CT scan shows a pyogenic abscess in the right psoas, (b) The catheter in the abscess, (c) Three months later, CT scanning reveals an improvement completely.



(a)



(b)



(c)

**Figure 2.** (a) Tuberculous abscess and vertebral lesion are seen in the left, (b) The catheter in the abscess, (c) Five months later, no recurrence.

thoracolumbar junction<sup>(3)</sup>. In our study five tuberculous psoas abscesses were secondary to tuberculous spondylitis. There was no other infection focus in one patient with tuberculous psoas abscess and two patients with pyogenic abscess. One patient with pyogenic abscess (8th case) had a history of pelvic operation one month ago. *Staphylococcus aureus* and alpha hemolytic streptococcus were isolated as the etiologic agents in two patients with pyogenic abscess.

The contrast enhanced CT is helpful in the diagnosis of psoas abscesses. Calcification or gas is sometimes seen. The CT appearance of the tumor is similar to that of an abscess<sup>(5)</sup>. Diagnosis is confirmed by CT or US. Psoas abscess is most prevalent in young patients. Primary psoas abscess rarely occurs in elderly. Secondary psoas abscess is found mainly in the 10 to 40 year's age group. Females are more often affected than males (with incidences of 73% and 27%, respectively). There is no significant difference between right and left sides<sup>(6)</sup>. We think that the drainage procedure is even usable in the diagnosis of the lesion and detection of pathogenic agent in the psoas. Six patients were female and two patients were male (ratio 75%; 25%) in our study. Except for the youngest patient, ages of others patients were above 30 years age.

Psoas abscess can be drained in the guidance of both CT and US. CT is more sensitive than US in showing the exact location and extend of abscess, its relation to nearby organs and localization of the catheter. US is more practical to use and allows bedside drainage<sup>(7,8)</sup>. Seven abscesses were drained under CT, and one pyogenic abscess was drained under US in our study. We suggest that CT guided drainage is easier than US guided drainage especially in obese patients and small abscesses.

PAD offers a number of advantages. General anesthesia and the stress of the surgery are avoided. Under cross-sectional imaging control, a safe access route can be determined and the completeness of drainage immediately assessed, prior to termination of the procedure. The original criteria for PAD were limited to well-defined unilocular abscesses with 'safe' drainage routes. Multiple collections can be drained by using multiple catheters<sup>(2)</sup>. All of our cases had uniloculated abscess. Because of this, only one catheter was sufficient. One patient with pyogenic abscesses had two abscesses in the proximal and distal parts of right psoas. Two different catheters were used in this patient.

The management of spinal tuberculosis varies from immobilization with antituberculous chemotherapy to various forms of operative treatment combined with drug therapy in different parts of the world<sup>(9)</sup>. In nonoperative treatment of any tuberculosis forms of the spine, Korea and Rhodesia achieved 85% of success rate with drugs alone. Surgery has been generally performed in the patients who had no improvement despite medical treatment, and had neurologic deficit. Surgery has a high failure and recurrence rate when abscess is not recognized or adequately drained<sup>(3)</sup>. Procaccino et al. reported two or more operations due to either failure or recurrence in 27 of 67 (40%) patients<sup>(10)</sup>. Pumbo et al. in 6 patients, reported 7 tuberculosis psoas or iliopsoas abscesses treated by CT guided drainage and chemotherapy. They found only one relapse of abscess in the patients, most likely due to the fact that the patient did not take the antituberculosis medication<sup>(4)</sup>. In Robert E. et al.' series of 12 psoas abscess, PAD were employed. There were 8 (67%) cures, one (8%) palliation, and 3 (25%) temporarizations. The temporarizations were

in those patients with Crohn disease and communication who later underwent segmental bowel resection<sup>(2)</sup>. There were no complication and deaths in their group. No recurrence was seen.

Despite such advantages, several questions remain concerning the efficacy of PAD that, to our knowledge, have not been addressed in the published studies of PAD. Many series have included little or no clinical follow up. Thus, recurrence rates for various types and locations of abscesses are difficult to determine<sup>(2)</sup>.

There were no complication and no deaths in our cases. No surgical intervention was required. We have not seen recurrence up to now. However, CT and clinical follow up keep going on.

PAD has a low risk and is a fairly easy procedure for the management of psoas abscess, when performed by experienced staff and when suitable cases are chosen, especially in the countries where tuberculosis is widespread. It is less traumatic when compared to surgery.

### CONCLUSION

In our opinion, in the treatment of tuberculous and pyogenic abscesses, PAD and chemotherapy should be the first treatment method in selected cases with psoas abscess that do not have extensive vertebral lesion, vertebral instability and neurologic deficit. PAD is as effective as the surgical treatment.

Geliş tarihi : 21.07.1998

Yayına kabul tarihi : 22.12.1998

Yazışma adresi:

Dr. Murat DANACI

Ondokuz Mayıs Üniversitesi, Tıp Fakültesi,

Radyodiagnostik Anabilim Dalı

55139 Kurupelit, SAMSUN

### KAYNAKLAR

1. Erkan ML. Tüberkülozun tarihçesi, ülkemiz ve dünyadaki durum. Ondokuz Mayıs Üniversitesi Tıp Dergisi 1996; 13: 291-295.
2. Robert E, Lane D, John JC, et al. Percutaneous drainage of 355 consecutive abscesses; Result of primary drainage with 1 year follow up. Radiology 1992; 184: 167-179.
3. Patrik KM. Pathologic spinal fractures due to infections. In: Errici TJ, Bauer RD, Waugh T, (ed). Spinal trauma. Philadelphia, JB Lippincot Company, 1991: 529-552.
4. Pombo E, Egana RM, Cela A, et al. Percutaneous catheter drainage of tuberculous psoas abscesses. Acta Radiologica 1993; 34: 366-368.
5. Michael A, Ruben K, Paul FG. Psoas compartment disease studied by computed tomography. Radiology 1983; 148: 505-512.
6. Gruen WI, Abrahamsen J, Cohen O. Psoas abscess: Case report and review of the literature. The journal of Urology 1992; 147: 1624-1626.
7. Pouchat J, Vinceneux P, Barge J, et al. Tuberculosis of the sacroiliac joints: Clinical features, outcome, and evaluation of the closed needle biopsy in consecutive cases. Am J Med 1988; 84: 622-628.
8. Vanssonanberg E, Mueller FR, Ferruci JT. Percutaneous drainage of 250 abdominal abscesses drainage. Radiology 1984; 151: 337-341.
9. Moon MS, Kim I, Woo YK, et al. Conservative treatment of tuberculosis of the thoracic and lumbar spine in adults and children. In Orthop 1987; 11: 315-322.
10. Procaccini JA, Lavery JC, Fazio VW, et al. Psoas abscess: Difficulties encountered. Dis Colon Rectum 1991; 45: 784-789.

