

LEFT ATRIAL BALL-VALVE THROMBUS MIMICKING MYXOMA. A CASE REPORT*

M.Kamuran Erk,M.D** Mikail Yüksel,M.D*** Olcay Sağkan,M.D****
Bedri Kandemir,M.D*****

SUMMARY

A 55-year-old woman has been hospitalized with a complaint of frequent syncopal attacks, especially when she lay over her back. She had no overt signs of heart failure and rhythm was atrial fibrillation. Preoperative echocardiographic study revealed a left atrial mass strongly suggestive of myxoma. At the operation, an egg shaped, with smooth surface thrombus was found in the left atrium. There were no any other thrombi, neither atrium nor atrial appandage, and the mitral valve was slightly stenotic.

Key words : Left atrial mass, Free-floating atrial thrombi, Ball-valve thrombi.

Atrial thrombi may occur much more often in the presence of atrial fibrillation than with sinus rnythm. Free-floating left or right atrial ball thrombi are rare^{4,6-8}. Echocardiography has been used to diagnose intraatrial masses.

CASE REPORT

A 55-year-old woman was admitted with complaint of palpitation, frequent syncopal attacks especially when she lay over her back. There was no history and sign about systemic embolization. Physical examination revealed a loud first heart sound followed by a Grade

* From the Departments of Cardiology, Cardiovascular Surgery and Pathology, Ondokuz Mayıs University, Medical Facult, Samsun, Turkey.

** Associate Professor of Cardiovascular Surgery.

*** Assistant Professor of Cardiovascular Surgery.

**** Professor of Cardiology.

***** Professor of Pathology.

2/6 middiastolic murmur. Character of auscultatory findings were changing with patient's position. Electrocardiography showed atrial fibrillation and right ventricular hypertrophy. X-Ray revealed cardiomegaly with left atrial enlargement. M-mode echocardiography revealed an enlarged left atrium, the mitral valve appeared slightly stenotic with normal structure of the leaflets. The tumor echoes were seen behind the mitral valve at the systole and diastole. Two-dimensional echocardiography showed mobile, sharply demarcated ovoid, left atrial mass suggestive of myxoma more than thrombi (Fig.:1). At surgery, ovoid shaped, with smooth surface, mobile tumor measuring 4 cm x 2 cm x 2 cm was attached by a bandlike long pedicle to the postero-medial wall of atrium. This band was disconnected easily from the atrial wall when the tumor was manipulated. Grossly the tumor did not look like myxoma (Fig.: 2). The mitral valve was slightly stenotic. There were no any other thrombi, neither atrium nor atrial appandage. The pathology report showed organized thrombus.

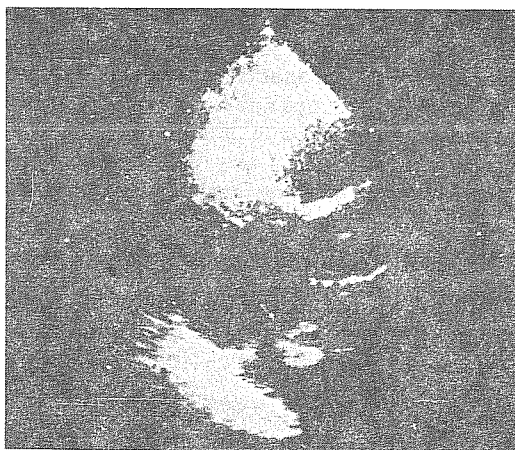
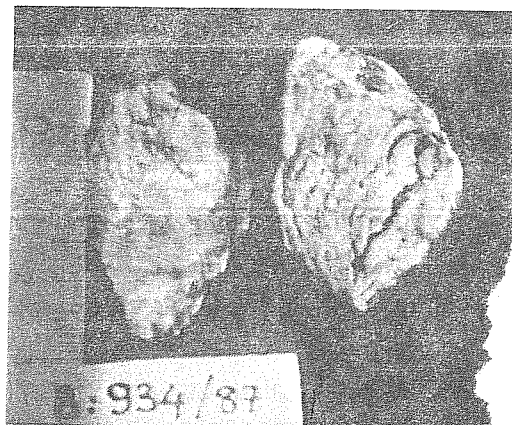


Figure 1.
Two-dimensional echocardiogram revealing large mass (arrows) within the left atrium.

Figure 2.
Gross view showing a mass 4x2x2 cm., appeared to be a myxoma. Histology revealed an organized thrombus.



DISCUSSION

Thrombi are the most common cause of mass lesions within the atria, but myxomas and other neoplasms must be considered in differential diagnosis. Free-floating left or right atrial ball thrombi are rare^{4,6-8}. Usually in left atrial myxoma and ball-valve thrombus the murmurs are intermittently heard. Only in certain position this murmur is heard or the character of the murmur changes depending of the patient's position. Change in body position, incident to the loss of consciousness, may cause the mass to become dislodged from the mitral valve. As a result the patient regains consciousness as our patient.

Echocardiography is the detection of choice for suspected intracardiac masses. Criteria have been proposed to differentiate between the various types of atrial masses^{1,2,5-8}. But echocardiographic features of the free-floating atrial thrombus sometimes mimicked atrial myxomas^{3,5}. However, accompanying structural abnormalities such as rheumatic mitral valve disease and left atrial enlargement support the diagnosis of thrombus². Left atrial thrombi only rarely occur without mitral valve abnormalities⁶. The mitral valve of our patient was slightly stenotic with normal structure of the leaflets. We are unable to explain why she developed atrial fibrillation or a large atrial thrombus with many features of myxoma.

REFERENCES

1. Come PC, Riley MF, Markis JE, Malagold M. Limitation of echocardiographic techniques in evaluation of left atrial masses. *Am J Cardiol* 48: 947-953, 1981.
2. DePace NL, Soulen RL, Kotler MN, Mintz GS: Two dimensional echocardiographic detection of intraarterial masses. *Am J Cardiol* 48: 954-960, 1981.
3. Kmetz JJ, Peters RW, Plotnick GD, Carliner NH, Baumgartner WA, and Fisher ML. left atrial mass. Thrombus mimicking myxoma. *Chest* 88: 906-907, 1985.
4. Przybojewski JZ, Vogts BC, Hunter J, Knott-Craig CJ. Mitral stenosis with free-floating left atrial thrombus and recurrent systemic embolisation. *South Af Med J* 71: 186-188, 1987.
5. Shiu MF, Abrams LD. Echocardiographic features of free floating thrombus mimicking right ventricular myxoma. *Br Heart J* 49: 612-614, 1983.
6. Sogaard PE. Free ball thrombus of the left atrium. *Eur J Cardiol* 12: 177-179, 1981.

7. Sunagawa K, Orita Y, Tanaka S, Kikuchi Y, Nakamura M, Hirata T. Left atrial ball thrombus diagnosed by two-dimensional echocardiography. *Am Heart J* 100: 89-94, 1980.
8. Tabak SW, Maurer G. Echocardiographic detection of Free-floating left thrombus. *Am J Cardiol* 53: 374-375, 1984.