



Technical Note

Nonanastomotic indirect bypass surgery in the surgical treatment of malignant glial tumors

Cengiz Çokluk*, Kerametdin Aydın, Ersoy Kocacıbağ

Department of Neurosurgery, Medical Faculty, Ondokuz Mayıs University, Samsun, Turkey

ARTICLE INFO

Article History

Received 23 / 02 / 2010

Accepted 10 / 03 / 2010

* Correspondence to:

Cengiz Çokluk
Ondokuz Mayıs University
Medical Faculty
Department of Neurosurgery
Samsun, Turkey
e-mail: cengizcokluk@yahoo.com

Key Words :

Pial Synangiosis
Indirect Bypass Surgery
Malignant Glial Tumors
Surgical Treatment
Cerebral Reperfusion
Chemotherapy

ABSTRACT

The primary treatment of malignant glial tumors is surgical intervention for maximally reducing and/or total removing of tumors. The purpose of this report was to describe pial synangiosis or indirect nonanastomotic bypass surgery for diversion of blood brain barrier for enhancing of systemic blood-brain tissue penetration in the enhancing of the effect of chemotherapy. The other purposes are the increasing of oxygen and metabolic product providing, enhancing of radiation sensitivity, and stabilization of brain tissue around the tumor bed for reducing of malignant transformation. We used the technique of indirect non anastomotic by-pass surgery technique during the surgical treatment of malignant glial tumors. Preoperative and postoperative magnetic resonance images were obtained to evaluate peri-lesional edema and residual complications. This technique was used in three cases of malignant glial tumors. There were no operative mortality and morbidity related to this technique. This technique may be used during the surgical treatment of malignant glial tumors to enhance penetration of chemotherapeutic agents, increasing of radiation sensitivity and providing of tissue stability.

J. Exp. Clin. Med., 2010; 27:31-34

© 2010 OMU All rights reserved

1. Introduction

Tumor lesions located in the CNS system can be mainly divided into two main groups as primary and secondary tumors. The term of primary tumors are used for describing of the tumors primarily originated from the nervous system cells. The term of secondary tumors are used for grouping of metastatic lesions. Primary brain tumors and secondary brain metastasis represent an important cause of morbidity and mortality in adults. It is estimated that 10%-30% of patients with solid tumors are diagnosed the CNS metastasis (Lassman et al., 2003).

Despite much advancement in the innovation and using of antineoplastic agents, the chemotherapeutic treatment of central nervous system (CNS) tumors and its metastatic involvement originated commonly from the lung, still have some controversies because of blood brain barrier causing poor penetration chemotherapeutic drugs into the nervous system parenchyma (Lassman et al., 2003; Motl et al., 2006).

In this clinical study, we used extracranial-intracranial pial synangiosis surgery using temporal muscle

in the cases with malignant glial tumor for enhancement of macrophage and leukocyte penetration into the brain parenchyma. It is known that extracranial capillary system doesn't have the tight junctions between endothelial cells mainly represented from the BBB. The newly forming capillaries originated from extracranial vessels structurally will not have endothelial tight junctions such as intracranial vessels. We hypothesized that these new capillaries may be used for macrophage and leukocyte as well as chemotherapeutic agents delivering into the brain tissue after pial synangiosis surgery. The chemotherapeutic agents such as MTX that have poor penetration into the brain parenchyma because of BBB may be used in the patients who have primary or metastatic lesions in the brain or spinal cord after pial synangiosis.

2. Materials and methods

This technique was used in three cases of malignant glial tumors (2 man and 1 woman) aged between 49 and 65 years old. All patients underwent preoperative computerized tomography and magnetic resonance imaging. Detailed

physical and neurological examination was performed before surgery. Total blood count, urinalysis, biochemical parameters of metabolic functions were examined. Heart and lung functions were analyzed. Dexametazon treatment was started in the cases with perilesional edema. Prophylactic antiepileptic drug treatment was started in all cases. The operative site, field and position of the patients during surgery were determined based on each patient's magnetic resonance findings. In the cases that underwent secondary operation, the previous skin incision and craniotomy bone flap was used to reach the lesion.

Operative Technique

The surgical position of the patients was determined after evaluation of the magnetic resonance images obtained before surgery. The skin incision was marked after three point fixation of the head with Mayfield head holder. The area of incision was shaved and skin incision was marked with surgical pen. The operation area was cleaned with Batticon solution. The operative field was covered with sterile cottons. Surgical drape was used for final preparation of the surgical site. The skin and subcutaneous tissue was cut by using surgical blade. The cutaneous and subcutaneous vessels were protected as much as possible during surgery. Galeo-periosteal flap was prepared with maximal protection of vessels. Kraniotomy flap was done in according to tumor located within the brain. After opening the bone flap the operative microscope was began to use for surgical intervention. Dura mater was opened.

Arachnoid and pia mater was cut by using sharp dissection technique. Intraoperative ultrasound examination was used in the localization and extension of the tumor. It was reached down the tumor. Surgical dissection was done from the surrounding brain tissue. The feeding arteries and draining veins was coagulated. The tumor tissue was removed with small pieces. The tumor tissue was totally removed with maximal protection of surrounding brain tissue. After completing this first step we started to second step of the operation, the indirect bypass surgery. In this step we prepared galeoperiosteal flap with maximal attention to protect vascular feeding arteries and draining veins. The flap was mobilized into the operative field from the nearest edge of the dura mater. After this first step we used two different surgical techniques. In the first technique, we just mobilize the myo-galeo-periosteal flep into the tumor bed. We did not use any suture materials for pial attachment. In the second technique, we used 10/0 suture materials for suturing of the galeo-periosteal flep to the arachnoid mater. Dura mater was sutured without drowning of the flap. The bone flap was put on the operative field keeping distance between skull edges for protection of galeoperiosteal flap. The subcutaneous tissue and skin were sutured with conventional technique. Computerized tomography was obtained early period after the surgery. Followup magnetic resonance imaging was obtained three months later after the surgery.

3. Results

This technique was used in three cases of malignant glial tumors. The first case was 49 years old man. In this, the tumor located on the right frontal lobe. The patient was operated six months before the second admission. The previous biopsy revealed that this is an anaplastic astrocytoma. Computerized tomography revealed that the presence of recurrent tumor in the right frontal lobe. The patient was operated and the tumor was removed gross totally. After removing of the tumor coagulation was done by using bipolar coagulation. Myo-galeo-periosteal flep was prepared and diverted into the tumor bed. The second case was 64 years old man. In the second case, the tumor was located on the parietal lobe. The pathological diagnosis was glioblastome multiforme. The third case was 65 years old woman. In the third case the tumor was located on the occipital lobe.

4. Discussion

Surgery, chemotherapy and radiotherapy are treatment methods. Although chemotherapy had been defined as a treatment method for many years, there is no common consensus in the treatment of brain metastasis because of chemo sensitivity and the BBB. The presence of intact or partially intact BBB is the main limitation of cytoreductive chemotherapy in these cases. Some different methods had been defined for diversion and/or penetration of BBB. Some of these methods are used together with systemic chemotherapy. Some others are used in focal chemotherapy

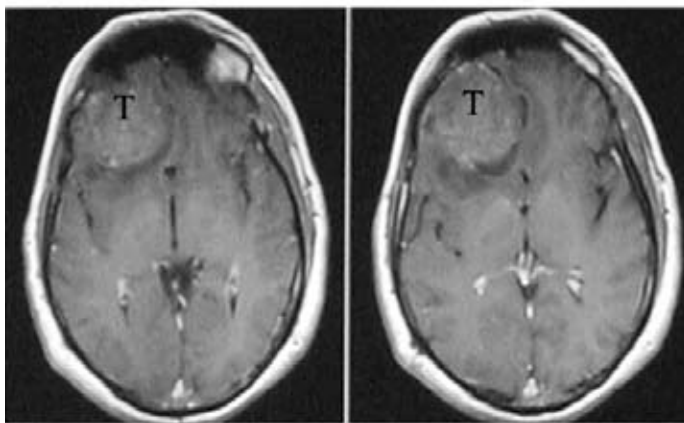


Fig. 1. This figure shows right frontal tumor.

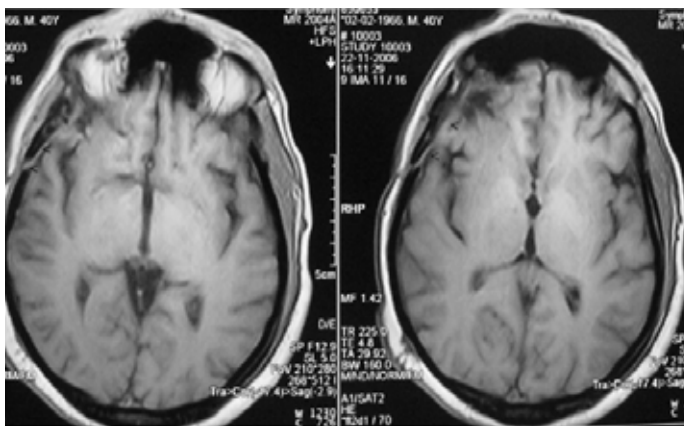


Fig. 2. This figure shows myo-galeo-periosteal flep and tumor bed after 6 months of the operation.

treatment methods. Such kind of methods had been described for the treatment of primary brain tumors as well as malignant metastasis.

BBB had been defined by Deekens and Loscher (Deeken and Löscher, 2007). Endothelial tight junctions and glial cellular barrier restrict the passage of some materials into the brain parenchyma. Extracellular matrix, pericytes, and astrocytic foot processes further mediate the specific permeability of BBB. The main BBB is the lack of fenestrated endothelial cells and the presence of tight junctions in the brain capillary vasculature (Bellavance et al., 2008).

The technique of pial synangiosis had been described treating of cerebral vascular insufficiency such as the moyo moyo disease and other vascular occlusive pathologies. In this procedure, extracranial tissues is mobilized with protection of their vascular feeders and exposed to pia mater. For this purpose, the temporal muscle is frequently used. Following this procedure the microcapillary vasculature of extracranial structures invades the very delicate membrane of pial mater to reach down the interstitial and extracellular matrix space of nervous system for developing of new vascularization tree. These new generations of vascular structures originating from extracranial vessels doesn't have structurally endothelial tight junction mostly responsible from BBB. These new generations have the endothelial pores and gap between endothelial cells like their original extracranial vessels. The passing of chemotherapeutic agents should be easier than normal intracranial capillary structures.

Indirect by-pass surgery may enhance the delivery of Oxygen and metabolite product to the operated brain area. Well nutrition of the brain tissue may enhance the capability of the self defense of the brain tissue against the destructive tumor tissue. In the other hand indirect by-pass surgery may regulate the microcirculation of brain tissue after tumor surgery. Indirect by-pass surgery may provide better microcirculation to the brain tissue in the enhancing of neuronal restoration after surgical intervention. Well oxygenated medium has more sensitivity to the radiation in comparison with anoxic condition. Indirect bypass surgery may be used in the enhancing of the efficacy of radiation treatment after surgical intervention to brain tumors. Another effect is to facilitate the passing of

chemotherapeutic agents into the brain tissue.

Hypoxia has negative effects on tumor biology. Tumors may have more aggressive behavior in hypoxic condition (Hockel et al., 1996; Rofstad, 2000). Tumor tissue tries to survive in their microenvironment. The instability of the providing of metabolic product and oxygen may result with the aggressive behavior and instability of tumor itself (Rofstad, 2000). Especially malignant tumors are more sensitive the unstable factors belonging to microenvironment. A more likely explanation is that the chronically hypoxic tumor environment might select for genomic instability and genetic heterogeneity, and thus for more malignant cellular phenotypes (Graber et al., 1996; Hockel et al., 1996). Indirect by-pass surgery may enhance the stability of the brain tissue. Chronic stabilization of tumor bed and peritumoral regions may result with cell stabilization in genetic and biological aspect. Stabilization also may prevent the new cellular transformation into tumor cells, or may reduce the number of malignant cells. Hypoxia could also influence tumor response to other treatment modalities such as chemotherapy and radiotherapy by altering gene expression. For example, activation of the transcription factors HIF-1 and NF- κ B by hypoxia can contribute to malignant progression by promoting cell proliferation and survival and/or upregulating genes that control angiogenesis and cell adhesion (Rofstad, 2000; Baldwin, 2001). Indirect bypass surgery may enhance the effect of nonsurgical treatment modalities in malignant glial tumors.

5. Conclusion

Indirect bypass surgery is generally used in the cases with hypoperfusion of the brain for restoration of blood circulation inside the brain parenchyma. The theoretical knowledge obtained from experimental study revealed that the diminished oxygen and nutrient providing into the perilesional brain may result increasing of malignant progression because of the instability of the brain parenchyma. Hypoperfusion also have a negative effect on the radiation chemotherapeutic treatment. Indirect bypass surgery may enhance the effect of radiation and chemotherapy on the brain tumors. Our conclusion is to use the indirect bypass surgery in the cases with malignant brain tumors.

REFERENCES

- Baldwin, A.S., 2001. Control of oncogenesis and cancer therapy resistance by the transcription factor NF- κ B. *J. Clin. Invest.* 107, 241–246.
- Barnholtz-Sloan, J.S., Sloan, A.E., Davis, F.G., Vignea, F.D., Lai, P., Sawaya, R.E., 2004. Incidence proportions of brain metastases in patients diagnosed (1973 to 2001) in the Metropolitan Detroit Cancer Surveillance System. *J. Clin. Oncol.* 22, 2865-2872.
- Bellavance, M.A., Blanchette, M., Fortin, D., 2008. Recent advances in blood-brain barrier disruption as a CNS delivery strategy. *AAPS J.* 10, 166-177.
- Caro, J., 2001. Hypoxia regulation of gene transcription. *High Alt. Med. Biol.* 2, 145–154.
- Deeken, J.F., Löscher, W. 2007. The blood-brain barrier and cancer: transporters, treatment, and Trojan horses. *Clin. Cancer Res.* 13, 1663-1674.

- Graeber, T.G., Osmanian, C., Jacks, T., 1996. Hypoxia-mediated selection of cells with diminished apoptotic potential in solid tumours. *Nature*. 379, 88–91.
- Hockel, M., Schlenger, K., Aral, B., 1996. Association between tumor hypoxia and malignant progression in advanced cancer of the uterine cervix. *Cancer Res*. 56, 4509–4515.
- Hockel, M., Vaupel, P., 2001. Biological consequences of tumor hypoxia. *Semin Oncol*. 28, 36–41
- Lassman, A.B., DeAngelis, L.M. 2003. Brain metastases. *Neurol. Clin*. 21, 1-23.
- Motl, S., Zhuang, Y., Waters, C.M., Stewart, C.F. 2006. Pharmacokinetic considerations in the treatment of CNS tumours. *Clin. Pharmacokinet*. 45, 871-903.
- Rofstad, E.K., 2000. Microenvironment-induced cancer metastasis. *Int. J. Radiat Biol*. 76, 589–605.