



A foreign body which caused esophageal perforation and was aspirated into the right main bronchus

Yasemin Bilgin Büyükkarabacak*, Ayşen Taslak Şengül, Selçuk Gürz, Ahmet Başoğlu

Department of Thoracic Surgery, Faculty of Medicine, Ondokuz Mayıs University, Samsun, Turkey

ARTICLE INFO

ABSTRACT

Article History

Received 22 / 07 / 2013

Accepted 26 / 08 / 2013

* Correspondence to:

Yasemin Bilgin Büyükkarabacak
Department of Thoracic Surgery,
Faculty of Medicine,
Ondokuz Mayıs University,
Samsun, Turkey
e-mail: yaseminbuyukkarabacak@gmail.com

Tracheobronchial and esophageal foreign body aspirations are life-threatening, and require immediate intervention. Major symptoms in case of a foreign body aspiration are shortness of breath, cough, wheezing and cyanosis. In esophageal foreign bodies, the major symptoms caused by irritation are dysphagia, hypersalivation and odynophagia. Foreign bodies lodged in the cervical esophagus and hypopharynx can cause airway obstructions by moving into the adjacent organs with the effect of coughing, swallowing or esophageal peristalsis. In this study, a patient who swallowed a chicken bone which caused a perforation in the proximal esophagus and then aspirated the bone into the right main bronchus is presented.

J. Exp. Clin. Med., 2014; 31:193-195

Keywords:

Dysphagia
Dyspnea
Esophageal foreign body
Esophageal perforation
Tracheobronchial aspiration

© 2014 OMU

1. Introduction

Foreign bodies in the esophagus and tracheobronchial tract can be seen in any age group but they are more common in children. In both cases, foreign bodies can cause not only minor symptoms but also life threatening major complications such as airway obstruction, mediastinitis due to esophageal perforation, or aorto-esophageal or esophago-tracheal fistulas (Kılıçgün et al., 2009).

In this study, a patient with proximal esophagus perforation is presented with the literature. The patient swallowed a chicken bone which caused a perforation in the proximal esophagus, then he aspirated the bone into the right main bronchus.

2. Case report

A 72-year-old male patient applied to the emergency department with the complaints of shortness of breath, cough,

throat pain during swallowing and redness on the neck, and stated that the complaints started 6 hours after eating a bone-in chicken. Medical history of the patient revealed that he had a cerebrovascular disease 6 years ago, and had been followed for 10 years due to a chronic obstructive lung disease. His body temperature was 38.6°C, and white blood cell count was 19.600/mm³. Physical examination revealed diffuse neck tenderness, redness, bilateral subcutaneous emphysema, bilateral diffuse sibilant rhonchi and coarse rales in lower zones. Computed tomography of the thorax and neck reported air values around the esophagus in the neck area and a foreign body density in the right main bronchus (Fig. 1, 2). The patient underwent bronchoscopy and esophagoscopy under emergency conditions. With rigid bronchoscopy under general anesthesia, a foreign body which lodged in the bronchial mucosa in the right main bronchus was detected and removed. (Fig. 3) After entering esophagus with rigid

esophagoscopy, mucosal damage and hemotoma were detected on the posterior wall of the esophageal entrance, and was evaluated as perforation area. The area was washed with sterile fluid, and food remains were removed. Oral nutrition was ceased, and a broad-spectrum antibiotic therapy and total parenteral nutrition were started. Physical examination and blood tests revealed no additional problems.

No pathological findings were detected in the control oral + iv contrast-enhanced thorax and neck tomography. The patient was discharged with advice on the postoperative 8th day. The patient is in the 6th month now, and no problem was detected during the follow-up.

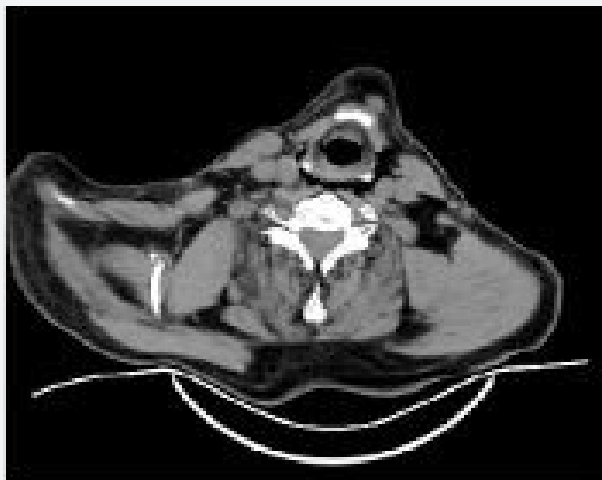


Fig. 1. Air densities around the esophagus in the neck

3. Discussion

Tracheobronchial and esophageal foreign body aspirations are life-threatening, and require immediate intervention. Major symptoms in case of a foreign body aspiration are shortness of breath, cough, wheezing and cyanosis (Elhassani, 1988; Smitheringale, 1995). While the foreign bodies in the proximal airway cause obstruction or laryngospasm, the foreign bodies in lower levels cause infection in the distal of the site lodged and chronic parenchymal destruction. Right main bronchus is shorter and wider than the left one, and its direction is closer to the vertical, so the foreign body aspirations into the right main bronchus and its branches are more common (Çobanoğlu and Yalçinkaya, 2009).

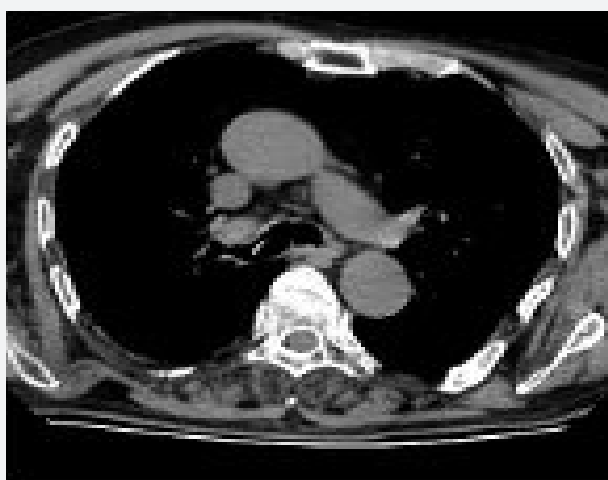


Fig. 2. The foreign body in the right main bronchus

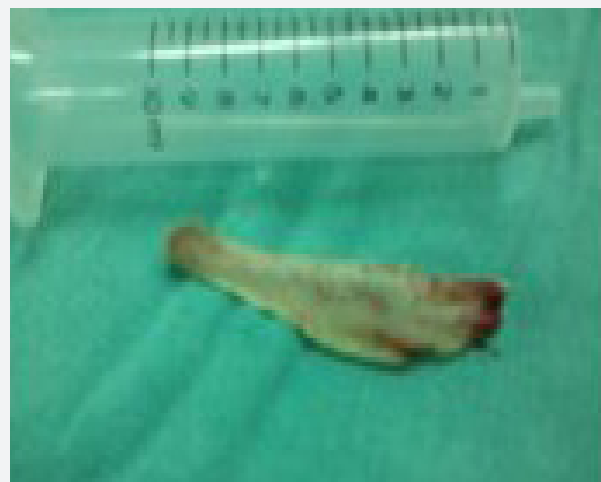

Fig. 3. Foreign body—chicken bone

In esophageal foreign bodies, the major symptoms caused by irritation are dysphagia, hypersalivation and odynophagia. Although the 80-90% of the foreign bodies which lodged in the esophagus passes spontaneously, 10-20% requires endoscopy and 1% requires surgical intervention (Pinto et al., 2012). The foreign body which has penetrated into the esophageal wall can weaken the wall by local inflammation and causes a perforation, and this perforation may cause life-threatening conditions such as mediastinitis, aorto-esophageal-esophagotracheal fistulas, retropharyngeal or epidural abscesses (İnci et al., 1999).

The first step in diagnosis is a true and informative medical history. Socio-economic and cultural structures, awareness and accompanying diseases of the patients and their families should be investigated. Then the location of the foreign body should be determined with radiographical examination. If the interval between the initial radiographic examinations and bronchoscopy or esophagoscopy is long, re-imaging should be performed before the procedures, because the location of the foreign body may change during this interval. In the literature, the sensitivity and the specificity of the direct radiographs for tracheoesophageal foreign bodies have been reported to be 65-85% and 51-70%, respectively (Sayır et al., 2012).

Therefore, in cases who have positive anamnesis but does not reveal a foreign body in plain radiography, in cases who have chronic foreign body history and in cases whose plain radiography reveals indefinable lesions, computed tomography should be applied.

Foreign bodies lodged in the cervical esophagus and hypopharynx can cause airway obstructions by moving into the adjacent organs with the effect of coughing, swallowing or esophageal peristalsis (Pinto et al., 2012). In our patient, the bone lodged in the cervical esophagus, then it was detached from the esophageal mucosa with the effect of the reflex coughing and was aspirated into the right main bronchus. The complaints of the patient at the admittance were severe shortness of breath and wheezing, rather than the pain in the throat.

Conservative therapy can be applied to a selected group of patients who have been admitted with perforation suspicion or who have limited perforation, minimal symptoms, injuries

with cervical esophageal perforation and minimal pleural or mediastinal contamination. According to this approach, in patients who meet the criteria, oral nutrition is ceased, and broad-spectrum antibiotic therapy and total parenteral nutrition are started (Hunerbein et al., 2004; Chiricaa et al., 2010). Although our patient had heat, redness and induration at the neck, and subcutaneous emphysema, there was no contrast material leakage in the contrast-enhanced neck and thorax tomography, and except for air values in the neck, no fluid or abscess formation was detected. So the patient was thought to have limited perforation, and he was treated with conservative approach.

In the literature, general mortality in esophageal perforations has been reported to be 18%. This rate is 6% for cervical esophageal perforation and 27% for thoracic

esophageal perforations (Chiricaa et al., 2010). In our series, in which cases of esophageal perforation are presented, no mortality has been observed in patients with cervical esophageal perforation. Four patients who had had thoracic esophageal perforation and had presented after the first day sepsis (Şengül et al., 2013).

Tracheobronchial and esophageal foreign body aspiration cases are life-threatening clinical conditions that require immediate intervention. It should be remembered that hypopharynx and upper esophageal foreign bodies may be aspirated into the tracheobronchial tract due to vomituration reflex or during the endoscopic extraction process. In such cases, early diagnosis and determination of the proper treatment choice is vital in the prevention of mortality or complications that may occur.

REFERENCES

- Chiricaa, M., Champaulta, A., Drayb, X., Sulpicec, L., Munoz-Bongranda, N., Sarfati, E., Cattan P., 2010. Esophageal perforations. *J. Visc. Surg.* 147, 117-128. doi: 10.1016/j.jviscsurg.2010.08.003.
- Çobanoğlu, U., Yalçınkaya, İ., 2009. Trakeo bronşiyal yabancı cisim aspirasyonları. *Ulus. Travma Acil Cerrahi Derg.* 15, 493-499.
- Elhassani, N.B., 1988. Tracheobronchial foreign bodies in the middle east. *J. Thorac. Cardiovasc. Surg.* 96, 621-625.
- Hunerbein, M., Stroszczyński, C., Moesta, K.T., Schlag, P.M., 2004. Treatment of thoracic anastomotic leaks after esophagectomy with self-expanding plastic stents. *Ann. Surg.* 240, 801-807.
- İnci, İ., Özçelik, C., Ülkü, R., Eren, N., 1999. Özofagus yabancı cisimleri: 682 olgunun incelenmesi. *GKDC. Dergisi.* 7, 148-152.
- Kılıçgün, A., Gezer, S., Sarıkıaş, N.G., 2009. Yabancı cisim aspirasyon / yutma şikayetleriyle başvuran hastaların endoskopik tedavisi: 26 olgunun analizi. *AİBÜ İzzet Baysal Tıp Dergisi.* 4, 1-5.
- Pinto, A., Muzj, C., Gagliardi, N., Setola, F.R., Scaglione, M., Romano, L., 2012. Role of Imaging in the assessment of impacted foreign bodies in the hypopharynx and cervical esophagus. *Semin. Ultrasound CT MR.* 33, 463. doi: 10.1053/j.sult.2012.06.009.
- Sayır, F., Çobanoğlu, U., Sertoğullarından, B., 2012. Özofagus vebronşial sistemde ilginç yabancı cisimler: 9 olgunun analizi. *J. Clin. Anal. Med.* 3, 278-282.
- Smitheringale, A., 1995. Management of foreign bodies of the tracheo bronchial tree. In Pearson. *Thoracic surgery.* Philadelphia. Churchill Livingstone. pp. 1591-1599.
- Şengül, A.T., Büyükkarabacak, Y.B., Yetim, T.D., Pirzirenli, M.G., Çelik, B., Başoğlu, A., 2013. Early diagnosis saves lives in esophageal perforations. *Turk J. Med. Sci.* 43, 939-945.