



## Charcot's foot

Hafize Titiz<sup>a</sup>, Ayşe Güler<sup>b</sup>, Yavuz Katirci<sup>c</sup>, Hayati Kandis<sup>b</sup>, Gokhan Ersunan<sup>d</sup>, Ayhan Saritas<sup>b\*</sup>

<sup>a</sup> Department of Internal Medicine, Faculty of Medicine, Düzce University, Düzce, Turkey

<sup>b</sup> Department of Emergency Medicine, Faculty of Medicine, Düzce University, Düzce, Turkey

<sup>c</sup> Department of Emergency Medicine, Ankara Teaching and Research Hospital, Ankara, Turkey

<sup>d</sup> Department of Emergency Medicine, School of Medicine, Recep Tayyip Erdoğan University, Rize, Turkey

### ARTICLE INFO

### ABSTRACT

#### Article History

Received 18 / 09 / 2013

Accepted 25 / 10 / 2013

#### \* Correspondence to:

Ayhan Saritas  
Department of Emergency Medicine,  
Faculty of Medicine,  
Düzce University, Düzce, Turkey  
e-mail: a\_saritas\_@hotmail.com

Charcot's arthropathy which occurs due to loss of pain and proprioceptive sensation is a chronic, destructive joint disease affecting bone, joint and soft tissues. Although it may be seen as a part of many diseases which cause peripheral neuropathy, most common cause is diabetic neuropathy. In this report a case with neuropathic arthropathy of right foot occurring due to diabetic neuropathy is presented, and current literature is reviewed. Charcot's neuroarthropathy which is generally seen as a complication of diabetes mellitus is even more important today because uncontrolled diabetes incidence tends to increase. Early diagnosis and treatment of that situation which should be included in differential diagnosis of a diabetic patient with an edematous foot without any pain provide opportunity to prevent neuroarthropathies that decrease quality of life.

*J. Exp. Clin. Med., 2013; 30:381-383*

#### Keywords:

Arthropathy  
Emergency  
Foot  
Neuropathy

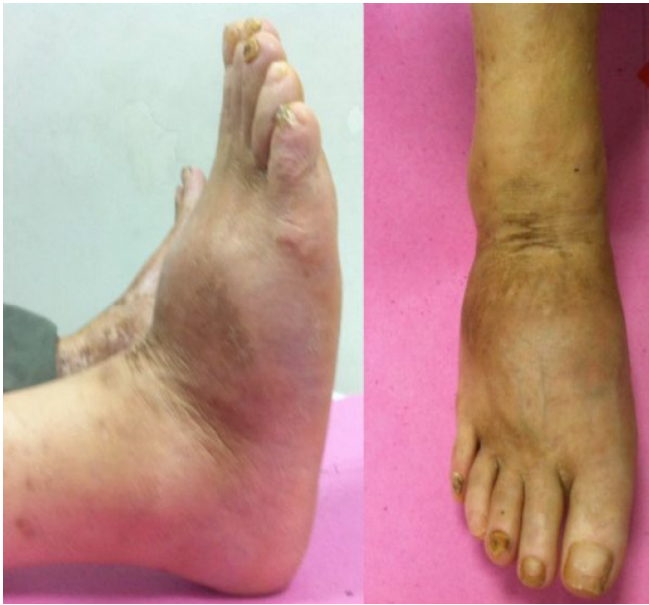© 2013 OMU

### 1. Introduction

Charcot's neuropathic osteoarthropathy namely Charcot's foot is a chronic degenerative arthropathy which is accompanied by loss of sensation, and affects bone, joint and soft tissues. Progressive changes causing painless swellings are present in the joint with loss of sensation, and destruction of bone together with abnormal bone formation are seen radiographically (Yağcı, 2009). It was first described by Jean Martin Charcot in a syphilitic patient in 1868 (Kumar et al., 2011). Association with diabetes and neuroarthropathy was reported by Jordan in 1936 (Jordan., 2011). Although it may be seen as a part of many diseases which cause peripheral neuropathy, most common cause of it is diabetic neuropathy. Charcot's neuroarthropathy (CN) is seen in 0.09% to 1.4% of diabetic patients, although peripheral neuropathy is seen in 9% to 32% of them. An increase in frequency of Charcot's neuroarthropathy is suspected with increasing incidence of diabetes (Pakarinen et al., 2002). In this article a case with neuropathic arthropathy of right foot occurring due to diabetic neuropathy is presented and current literature is reviewed.

### 2. Case

A 50-year-old male patient admitted to our emergency department due to swelling in his right foot and difficulty in walking which had been present for the last two days. Although there were swelling, and some decrease in range of motion in his right foot, pain, erythema or increased local skin temperature were not present (Fig. 1). Peripheral pulses were palpable bilaterally. A stocking hypoesthesia up to 10 cm above ankle joints was found in both feet. We have learned that patient who has had type 2 diabetes for 17 years had complaints of swelling, erythema and increased local skin temperature in his right foot without any trauma one year ago and all of his symptoms healed without any medical treatment in two to three months. X-rays showed diffuse osteoporosis of bones, decrease in bone density, more evident trabecular pattern, and ventrally luxated metatarsal bones in the level of tarsometatarsal joints. Communited displaced fracture lines in proximal parts of the first, second and third metatarsal bones and increased opacity in adjacent soft tissues were seen (Fig. 2). Complete blood count, erythrocyte sedimentation rate, and

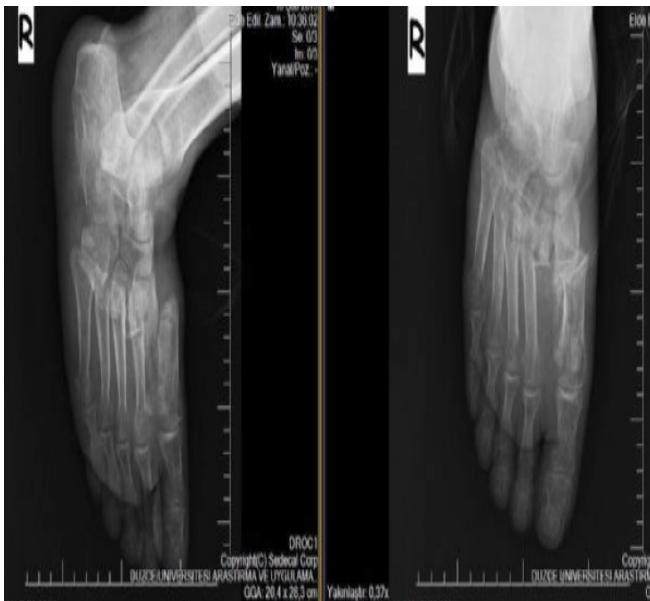

**Fig. 1.** Photographic images of the patient with Charcot's joint

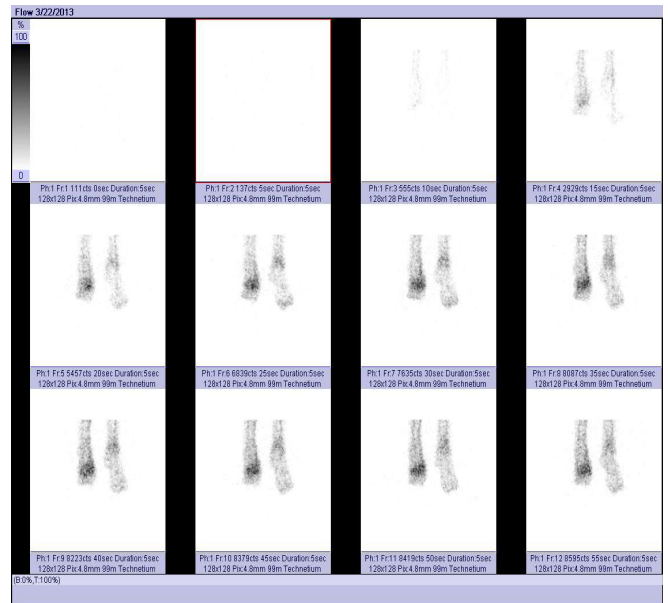
C-reactive protein levels were normal. Patient was referred to orthopedic outpatient clinic and magnetic resonance imaging was performed but it could not give enough information for discrimination between neuroarthropathy and osteomyelitis. Hence three-phase Tc-99m bone scintigraphy was performed and findings were interpreted as supporting the diagnosis of Charcot's neuroarthropathy (Fig. 3). Patient was taken to outpatient follow-up by orthopedic clinic and his current osteoporosis treatment with alendronate monosodium trihydrate plus vitamin D<sub>3</sub> was continued. Insulin doses of patient who had poorly controlled diabetes were re-regulated by Diabetes outpatient clinic, and he was advised to use proper shoes.

### 3. Discussion

Neuroarthropathic fracture and dislocations may result from minor injuries for example sprains as well as repeating little traumas. They may also rarely develop secondary to major traumas such as falls and traffic accidents (Öznur et



**Fig. 2.** X-ray images of Charcot's joint



**Fig. 3.** Scintigraphy images of Charcot's joint

al., 2011). Etiological reasons of neuroarthropathy include diabetes mellitus, tabes dorsalis, leprosy, syringomyelia, meningomyelocele, spinal cord trauma and tumors, poliomyelitis, Riley-Day Syndrome, cystic disease of bone, congenital insensitivity to pain, amyloid neuropathy, cerebral palsy, lead intoxication, and cerebrovascular occlusion (Öznur et al., 2011; Rogers, 2011). That case had diabetes mellitus for 17 years and his serum glucose levels were generally high. Although the pathophysiologic mechanism of Charcot's foot is not clearly understood it is estimated to be multifactorial. Joints and periarticular soft tissues are damaged by repeating micro and macro traumas in foot with loss of protective sensation, and proprioception. Abnormal vasomotor regulation which is caused by autonomic denervation results in increased local blood flow, arteriovenous shunting, increased osteoclastic activity, and bone resorption. Additionally motor neuropathy makes some contribution to development of Charcot's neuroarthropathy by causing muscle weakness which leads to unequal weight loading on the joint, and development of progressive deformity especially in weight-bearing joints. Rocker bottom deformity in which medial arch of foot collapses and large ulcers may form under the foot is characteristic for Charcot's foot (Pakarinen et al., 2002; Öznur et al., 2011; [http://www.turkendoktrin.org/files/pdf/diabetes\\_klvz2011\\_2013](http://www.turkendoktrin.org/files/pdf/diabetes_klvz2011_2013)).

Einichenholtz divided neuroarthropathy into three stages according to clinical and radiological findings:

**Stage I:** Acute inflammation stage (dissolution); It is characterized by hyperemia, edema, and erythema. It may be easily misdiagnosed as infection. Demineralization, periarticular fragmentation, and dislocation may be seen radiographically.

**Stage II:** Edema, and inflammation decrease in repair (coalescence) phase. Bone debris is absorbed and a periosteal reaction is seen if there is a fracture, and the fractured bone is more stable now.

**Stage III:** Sclerosis, blunting of edges of bone fragments, and bony or fibrous ankylosis develop. Persistent edema and fixed deformity are present in the foot, and ankle joint. Skin temperature returns to normal, and swelling seen after daily

activity decreases even more. We detected that our patient had completed stage I, and stage II so he was in Stage III (Öznur et al., 2001).

Infection and venous thrombosis are misdiagnosed, and antibiotic treatment is given unnecessarily in a patient admitting with the first symptoms of diabetic neuroarthropathy such as painless deformity, erythema, increased local skin temperature, and edema. Cellulitis, osteomyelitis, and gout disease should be remembered in differential diagnosis of acute neuroarthropathy. Although pain is not a common symptom in neuroarthropathic patients infection can cause pain even in the presence of neuropathy. X-ray is useful because it gives information about bone structure, bony fragmentation, and periosteal new bone formation but radiological findings of CN typically appear late in the course of the disease. Our patient's complete blood count, erythrocyte sedimentation rate, and C-reactive protein levels were normal, and X-rays showed diffuse osteoporosis of bones, decrease in bone density, more evident trabecular pattern, and ventrally luxated metatarsal bones in the level of tarsometatarsal joints. Communited displaced fracture lines in proximal parts of the first, second and third metatarsal bones and increased opacity in adjacent soft tissues were seen.

Magnetic Resonance Imaging (MRI) may catch CN in earlier stages but it is not useful in discrimination between neuroarthropathy, and infection because bone marrow edema is seen in both of those situations. Technetium 99m (Tc 99m) bone scintigraphy, and Indium-111-labeled white blood cell scintigraphy should be used together in order to exclude the diagnosis of osteomyelitis. It has been recently reported that Positron Emission Tomography (PET) can also be used for

discrimination between CN, and osteomyelitis. We performed Tc 99m bone scintigraphy in our patient because MRI could not give enough information for discrimination between neuroarthropathy and infection. Scintigraphy findings were interpreted as supporting the diagnosis of CN by correlating them with patient's current clinical situation.

The first step in the treatment is deciding correct diagnosis and defining accompanying risks. Therefore the diagnosis should be made by using medical history, clinical findings, and imaging methods. Clinical stage, radiographic findings, and the presence or absence of deformity, ulcer, and infection should be taken into account. Medical treatment includes treatment of bone diseases, and factors that may cause local bone resorption or secondary osteoporosis if any is present.

The foot thought to has CN should be immobilized by using total contact casts, standard below knee casts, or splints to prevent more harm to affected joint before it loses its functionality totally. Immobilization should be continued until edema subsides and temperature difference between two feet decreases to 2 °C. Then patient may use a brace or proper shoes. Patients who have prominent instability, recurrent ulcers or acute fractures may need surgical treatment (Öznur et al., 2001; Rogers, 2011 ).

In conclusion, CN which is generally seen as a complication of diabetes mellitus is even more important today because uncontrolled diabetes incidence tends to increase. Early diagnosis and treatment of that situation which should be included in differential diagnosis of a diabetic patient admitting with an edematous foot without any pain provide opportunity to prevent neuroarthropathies that decrease quality of life.

## REFERENCES

- [http://www.turkendokrin.org/files/pdf/diabetes\\_klvz2011..](http://www.turkendokrin.org/files/pdf/diabetes_klvz2011..), 2013).
- Jordan WR., 1936. Neuritic manifestations in diabetes mellitus. *Arch Intern Med.* 57, 307-366.
- Kumar, D.R., Aslinia, F., Yale, S.H., Mazza, J.J., 2011. Jean-Martin Charcot: The father of neurology. 9, 46-49.
- Öznur, A., Alanay, A., Gürlek, A., Surat, A., 2001. Birinci metatarsofalangeal eklem nöroartropatisi. *Hacettepe Ortopedi Dergisi Hacettepe Ortopedi Dergisi.* 11, 38-42.
- Pakarinen, T.K., Laine, H.J, Honkonen, S.E., Peltonen, J., Oksala, H., Lahtela, J., 2002. Charcot arthropathy of the diabetic foot. Current concept and review of 36 cases. *Scandinavian Journal of Surgery.* 91, 195-201.
- Rogers, L., C., 2011. The Charcot Foot in Diabetes. *Diabetes Care.* 34, 2123-2129.
- Yağcı, İ., 2009. Siringomiyeliye bağlı el-el bileği nöropatik artropatisi: Olgu sunumu. *Fiziksel Tıp ve Rehabilitasyon Dergisi.* 55, 176-178.