

## Hyperbaric Oxygen Experience on Treatment of the Bisphosphonate-Related Osteonecrosis of Jaw (Bronj): Case Report of a Metastatic Breast Cancer Patient

<sup>1,2</sup>Evrım Bayman, <sup>3</sup>Nilüfer Bıçakçı, <sup>4</sup>Evin Koç Gülen

<sup>1</sup>Eskisehir Osmangazi University Medical Faculty Department of Radiation Oncology,

<sup>2</sup>Samsun Education and Investigation Hospital Clinic of Radiation Oncology,

<sup>3</sup>Samsun Education and Investigation Hospital Clinic of Nuclear Medicine,

<sup>4</sup>Samsun Baroklinik Hyperbaric Oxygen Therapy Center - Turkey  
e-posta: evrimbayman@hotmail.com

**SUMMARY:** The Bisphosphonate-Related Osteonecrosis of the Jaw (BRONJ) is an exposed necrotic alveolar bone associated with intravenous (IV) administration of Bisphosphonate (BP) therapy of multiple myeloma and bone metastases without previous radiation therapy (RT) to the maxillo-facial region (1,2,3). Hyperbaric Oxygen (HBO) treatment is one of the option which used on treatment of BRONJ, via increasing stem cell mobilisation, decreasing oedema, inflammation, and accelerating to wound healing (4,5). In this report, the case with metastatic breast cancer who has BRONJ was presented, and treatment of BRONJ with HBO was discussed.

**KEY WORDS:** Bronj (Bisphosphonate-Related Osteonecrosis of the Jaw), Hyperbaric Oxygen (HBO), radiotherapy

**ÖZET:** Bifosfonata bağlı çene osteonekrozisi (BBCO) kemik metastazı veya multipl myeloma'da kullanılan intravenöz bifosfonat ile ilişkili, daha önce radyoterapi uygulanmamış maksillofasiyal bölge alveoler kemiklerinin nekrozudur (1,2,3). Hiperbarik oksijen (HBO) kök hücre mobilizasyonu artırma, ödem, inflamasyonu azaltma ve hasar iyileşmesini hızlandırması yoluyla, BBCO tedavisinde kullanılan seçeneklerden biridir (4,5). Bu raporda metastatik meme kanserli bir BBCO olgusu sunulacak ve BBCO tedavisinde HBO tartışılacaktır.

**ANAHTAR KELİMELER:** Bifosfonata bağlı çene osteonekrozisi (BBCO), Hiperbarik oksijen (HBO), radyoterapi

### 1. Introduction

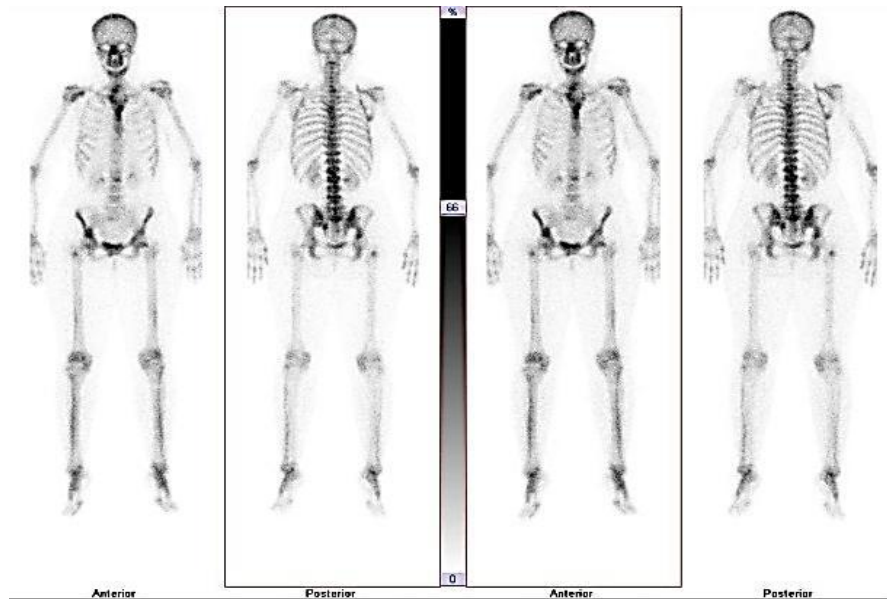
Use of bisphosphonates is not very rare in the treatment of bone metastasis related cancers and Multiple Myeloma. Bisphosphonate-Related Osteonecrosis of the Jaw (BRONJ) rate had differences from 0.8% to 12% in series in the literature (1,2,3). That generally occurs after tooth extraction as a soft tissue healing problems on the maxillo-facial region (1,2,3). Guidelines offer local supportive care to the oral cavity, surgery, and antibiotherapy in the treatment of BRONJ. Hyperbaric Oxygen (HBO) treatment, as an adjunct to that

approaches, is used on the BRONJ because of regenerative effects of the woundy tissue via stem cell mobilisation (4,5).

### Case report

The patient who was 41 years old premenopausal woman at the diagnosis of local advanced breast cancer was referred for adjuvant radiotherapy (RT) after left modified radically mastectomy and chemotherapy. RT was given to the left

chest wall and lymphatic field. She continued to routine control regularly after



**Figure 1.** August 2008 Bone scintigraphy

treatment. Eighteen months after diagnosis, she complained the lumbar pain. CA 15-3 elevation in blood test, and multiple bone metastasis on total body bone scintigraphy were detected (Figure 1).

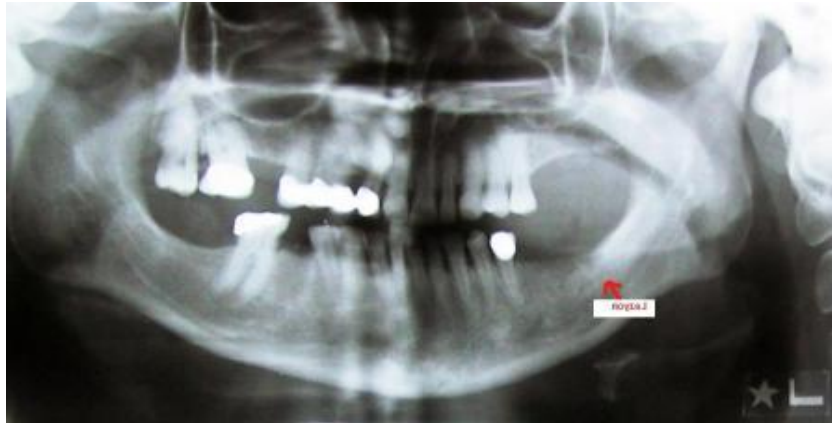
Palliative RT was given to the painful lumbosacral field and proximal of right femur as 10 fraction X 300 cGy. The monthly intravenous bisphosphonate (BP) (Zoledronic Acid, 4 mg, IV) was started after dental control. She was referred to the dentist because of tooth pain, 33 months after diagnosis (14th month of BP). The dentist extracted the tooth. Two months after operation, she came with recovery problem of the extraction cavity, minimal bone erosion was seen in the panoramic mandibular radiography (Figure 2).

She underwent the biopsy from that cavity by referred dentist, and the pathology was reported an "osteonecrosis". Monthly bisphosphonate administration was stopped. The oral antibiotic (Amoxicillin and Clavulanate), Chlorhexidine mouthwash, and analgesic (Diclofenac sodium) has

been started to the patient. She complained the pain at the left side of mandibular region. She referred to the Hyperbaric Oxygen Therapy Center. She has been offered 40 sessions, 2.5 ATA (Atmosphere Absolute) pressure HBO treatment. She has continued eighteen sessions, and tolerated well. That necrotic area recovered, the oral mucosa covered there, and pain compliance stopped. The panoramic mandibular radiography reported normal. There was no progression about primary disease at the new screen test, compared old examination. She is alive with stable disease, and there are no complaints and findings on her BRONJ area.

## 2. Discussion

Bisphosphonates (BP) are commonly used agents in the treatment of metastatic bone disease, malignant hypercalcemia, multiple myeloma, and osteoporosis. These drugs are specific inhibitors of osteoclastic activity. Bisphosphonate-related



**Figure 2.** *The panoramic mandibular graphy after tooth extraction*

osteonecrosis of the jaw (BRONJ) is recognized as a serious complication among patients who long term administrated BP therapy (1-3)..

BRONJ is a significant side effect in a receiving patients especially intravenous preparations of BP. BRONJ rate is differences from 0.8% to 12% in series in the literature (1-3)

Any oral surgical procedure or traumatic event such as tooth extraction may precipitate osteonecrosis of the jaw (BRONJ) (1-3,6-8). Hoff et al found that, dental extraction, and use of Zoledronic Acid as a BP were statistically significant risk factors in metastatic breast cancer patients (3). Pathogenesis of BRONJ is not very clear, BP may cause the soft tissue damage via an inhibition of periodontal fibroblasts, and supression of angiogenesis (7,9). It's also related with the microtrauma, inflamation, and chronic infection (1,2,6-9). Oral hygiene, and education of patients are emphasized for

protection. Before start to a BP, dental risks such as infection, nutrition properties, drug, alcohol usage, smooking and comorbidity should be controlled. Prophylaxis is recommended for the prevention of periodontal infection. The dose, duration, type and potency of BP may increase the risk of BRONJ (1,2,4).

It may be asymptomatic for long time. The typically clinical symptoms are swelling, and pain or paresthesia. Oro-cutaneous fistula can develop. Radiological alterations are not significant until involving the bone tissue. Late radiographic aspect is similar an osteomyelitis. Biopsy specimen shows the necrotic bone areas and debris at the microscopic examination (1). The American Association of Oral and Maxillofacial Surgeons (AAOMS) decribed definition and staging system for BRONJ (10). According to Ruggiero et al, treatment was conducted according to the staging system (Table I) (11,12).

**Table 1**  
*BRONJ Staging system*

Stage 1	Asymptomatic patients,exposed and necrotic bone with no clinical evidence of infection, only antibacterial mouth rinses with oral hygiene measures and patient education about the risks of developing BRONJ.
Stage 2	Local infection in the area of bony exposure, treatment with antibacterial mouth rinse, pain control, superficial debridement to relieve soft tissue irritation, antibiotic therapy.
Stage 3	Pathological fracture, extraoral fistula or extensive osteolysis, all previous measures were used along with surgical debridement and/or resection, in addition, long-term oral or/and i.v. antibiotics were used.

The other treatment approach is HBO. It has been used more than 30 years for prevention and treatment of radionecrosis of the jaw (13). HBO effects via increasing stem cell mobilisation, decreasing oedema and inflammation, accelerating wound healing (4,5).

HBO improves wound healing by amplifying oxygen gradients along the periphery of ischaemic wounds (14). The physiological effects of HBO extend beyond the elevation of oxygen concentration in body tissues (15,16). Although arterial oxygen tension is 100 mmHg, and tissue oxygen tension 55 mmHg in breathing normobaric air, at 3 ATA 100% oxygen can increase arterial oxygen tensions to 2000 mmHg, and tissue oxygen tensions to 500 mmHg. HBO also

increases generation of oxygen free radicals, also improves the oxygen-dependent transport of antibiotics across bacterial cell walls, damages DNA, inhibits bacterial metabolic functions, and it's particularly effective against anaerobes (16-18). In our patient, after HBO treatment, necrotic areas, and debris healed, tissue defect covered by normal mucosa, pain stopped.

### 3. Conclusion

Although bisphosphonates are beneficial in metastatic cancer patients, long-term routine use of these drugs occur the BRONJ. HBO treatment may be used in treatment of BRONJ with conventional treatment modalities, because of effects on wound healing via especially stem cell mobilisation.

### REFERENCES

1. Ficarra, G. Beninati, F. (2007). Bisphosphonate-related Osteonecrosis of the Jaws: An Update on Clinical, Pathological and Management Aspects. *Head and Neck Pathol* 1, 132-40.
2. Vescovi, P. Nammour, S. (2010). Bisphosphonate-Related Osteonecrosis of the Jaw (BRONJ) therapy. A critical review. *Minerva Stomatol.* 59(4), 181-203, 204-13.
3. Hoff, A.O. Toth, B.B. Altundag, K. et al. (2008). Frequency and Risk Factors associated with osteonecrosis of the jaw in cancer patients treated with intravenous bisphosphonates. *J Bone Miner Res.* 23, 826-36.
4. Freiburger, J.J. Padilla-Burgos, R. Chhoeu, A.H. et al. (2007).

- Hyperbaric oxygen treatment and bisphosphonate-induced osteonecrosis of the jaw: a case series. *J Oral Maxillofac Surg.* 65(7), 1321-7.
5. Freiburger, J.J. (2009). Utility of hyperbaric oxygen in treatment of bisphosphonate-related osteonecrosis of the jaws. *J Oral Maxillofac Surg.* 67(5), 96-106.
  6. Feller, L. Wood, N.H. Khammissa, R. A. et al. (2011). Bisphosphonate-related osteonecrosis of the jaw. *SADJ.* 66(1), 30-2.
  7. Agis, H. Blei, J. Watzek, G. et al. (2010). Is zoledronate toxic to human periodontal fibroblasts? *J Dent Res.* 89(1), 40-5.
  8. Ripamonti, C.I. Maniezzo, M. Campa, T. et al. (2009). Decrease occurrence of osteonecrosis of the jaw after implementation of dental preventive measures in solid tumour patients with bone metastases treated with bisphosphonates. The experience of the National Cancer Institute of Milan. *Annals of Oncology.* 20, 137- 45.
  9. Sanna, G. Preda, L. Bruschini, R. et al. (2006). Bisphosphonates and jaw osteonecrosis in patients with advanced breast cancer. *Annals of Oncology.* 17, 1512-16.
  10. Advisory Task Force on Bisphosphonate-Related Osteonecrosis of the Jaws, (2007). American Association of Oral and Maxillofacial Surgeons. American Association of Oral and Maxillofacial Surgeons position paper on bisphosphonate-related osteonecrosis of the jaws. *J Oral Maxillofac Surg.* 65(3), 369-76.
  11. Ruggiero, S.L. Dodson, T.B. Assael, L.A. et al. (2009). American Association of Oral and Maxillofacial Surgeons position paper on bisphosphonate-related osteonecrosis of the jaws—2009 update. *J Oral Maxillofac Surg.* 67(5), 2-12.
  12. Baqain, Z. H. Sawair, F. A. Tamimi, Z. et al. (2010). Osteonecrosis of jaws related to intravenous bisphosphonates :the experience of a Jordanian teaching hospital. *Ann R Coll Surg Engl.* 92(6), 489-94.
  13. Feldmeier, J.J. Hampson, N.B. (2002). A systematic review of the literature reporting the application of hyperbaric oxygen prevention and treatment of delayed radiation injuries: an evidence based approach. *Undersea Hyperb Med.* 29(1), 4-30.
  14. Knighton, D.R. Silver, I.A. Hunt, T.K. (1981). Regulation of wound-healing angiogenesis-effect of oxygen gradients and inspired oxygen concentration. *Surgery.* 90, 262-70.
  15. Migliorati, C. A. Schubert, M. M. Peterson, D. E. et al. (2005). Bisphosphonate-associated osteonecrosis of mandibular and maxillary bone: an emerging oral complication of supportive cancer therapy. *Cancer.* 104(1):83-93.
  16. Gill, A. L. Bell, C. N. (2004). Hyperbaric oxygen: its uses, mechanisms of action and outcomes. *QJM;*97(7), 385-95.
  17. Sverzut, C.E. Sverzut, A.T. de Matos, F. P. et al. (2012). Mandibular bisphosphonate-related osteonecrosis after dental implant rehabilitation: a case report. *Implant Dent.*21(6), 449-53.
  18. Assaf, A.T. Smeets, R. Riecke, B. et al. (2013). Incidence of Bisphosphonate-related Osteonecrosis of the Jaw in Consideration of Primary Diseases and Concomitant Therapies. *Anticancer Res.* 33(9), 3917-24