

Cuttig balloon use in below knee disease

Nuri İlker Akkuş

Department of Cardiology, Searcy Medical Center, Arkansas, USA

Özet

Dear Editor,

A 73-year-old white male has been admitted with pain in his feet. Lower extremity angiogram revealed 70% lesion in the ostium of the left anterior tibial artery which was the only vessel supplying the foot (Figure 1). A wire was advanced up the distal anterior tibial artery. A 6 x 45 cm sheath was advanced over the wire. In order to minimize plaque shifting to peroneal artery, a 3,5 x 10 mm cutting balloon was advanced over the wire and inflated. Post inflation there was no significant residual stenosis (Figure 2).

Key words: Peripreral artery disease, cutting balloon

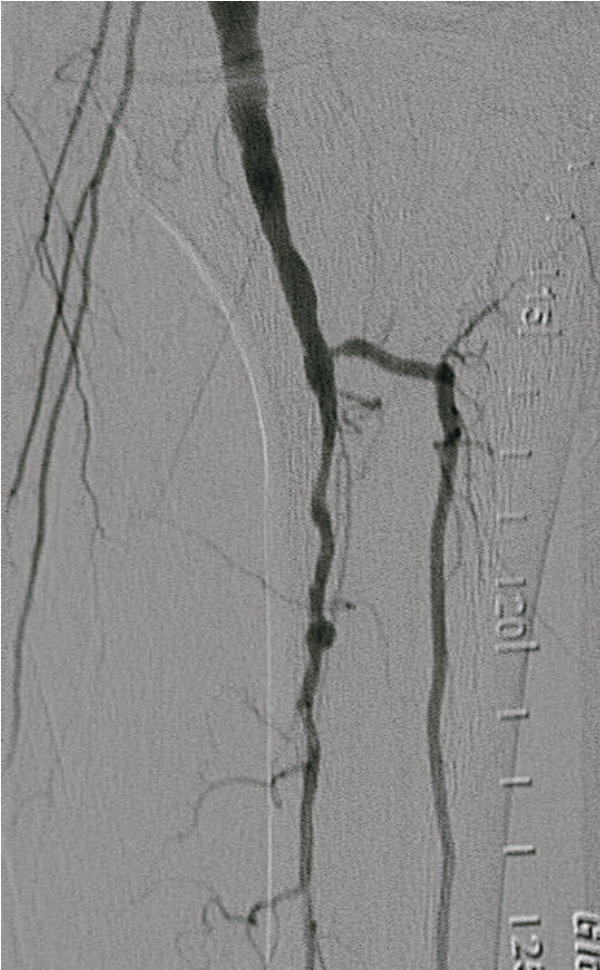


Figure 1

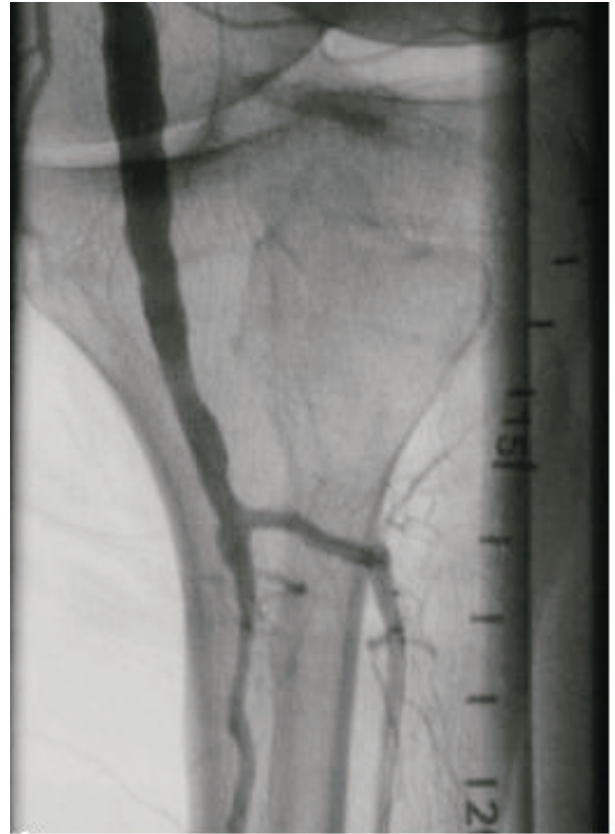

Figure 2

Corresponding Address: Nuri İlker Akkuş, MD
Searcy Medical Center Searcy, 72143, Arkansas, USA
Tel: 501-2783062, Mobile Tel: 501-5935560
E-mail: nuriilkerakkus@yahoo.com, iakkus@hotmail.com

Müracaat tarihi: 21.12.2009
Kabul tarihi: 05.03.2010