

Successful use of vincristine in the management of Kasabach-Merritt Phenomenon

Duran Canatan*, M Asım Aydın**, Ayça Esra Kuybulu***, Aslıhan Boyacı***, Tuğba Koca***.

*Süleyman Demirel University, Faculty of Medicine, Department of Pediatric Hematology, Isparta, Turkey.

**Süleyman Demirel University, Faculty of Medicine, Department of Plastic and Reconstructive Surgery, Isparta, Turkey

***Süleyman Demirel University, Faculty of Medicine, Department of Pediatrics, Isparta, Turkey

Özet

Kasabach Merritt Fenomeninde başarılı Vincristinin kullanımı

İki aylık erkek bebek, lumbosakral bölgede retroperitonu tutan Kaposiform Hemangioendothelioma ile, Kasabach Merritt Fenomeni (KMF) tanısı konarak hastaneye kabul edildi. Kortikosteroid ve interferon tedavileri hastalığın ilerlemesinde başarısız oldu. Vincristin mono tedavisi ile fibrinojen ve trombosit sayısı hızlı yükseldi, lezyon büyümesi geriledi. Remisyon sağlandı ve tedavi süresince yan etkiler gözlenmedi. Tedavisi kesildikten 6 ay sonra rölaps oluşmadı. KMF de çoklu ilaç tedavisi yerine ilk seçenek olarak vincristin tedavisi düşünülebilir.

Anahtar kelimeler: Kasabach Merritt Fenomeni, Vincristin

Abstract

A 2-month old boy with Kaposiform Hemangioendothelioma of the lumbosacral region invading the retroperitoneum was admitted with Kasabach-Merritt Phenomenon. After corticosteroid and interferon treatments failed with progression of the disease to a life threatening condition, vincristine monotherapy granted a rapid rise in platelet counts, fibrinogen levels and a resolution in the enlargement of the lesion. The remission was maintained and no adverse effects were observed during the treatment. Vincristin therapy may be suggested instead of multidrugs as first line therapy in patients with KMP.

Key words: Kasabach-Merritt Phenomenon, Vincristine

Introduction

Kasabach-Merritt Phenomenon (KMP) is a life threatening clinical picture characterized by thrombocytopenia, consumption coagulopathy with a low fibrinogen level and microangiopathic hemolytic anemia in the presence of a rapidly enlarging vascular lesion (1). Affected infants may manifest high output cardiac failure as a result of increased blood flow through the vascular lesions. It can be lethal; the estimated overall mortality rate ranges from 10-37% (2). Kaposiform hemangioendothelioma is the responsible lesion most of the time, Retroperitoneal involvement is significant determinant of the mortality. Early treatment is important to prevent fatal bleeding. MRI and ultrasonography are both effective tools for determining the extension of the lesion hence the prognosis and for assessing their response to therapy (3,4).

We would like to present a 2 month old boy with KMP, successfully treated with vincristine therapy.

Case

A two month old patient was admitted to our outpatient clinic with rapid enlargement of a congenital mass in his back and an echymosis extending around it. Physical findings on admission showed an elevated, tense, dark purple to red tumor of about 15 ×20 cm in size at the right lumbosacral region (Fig. 1). His family history was unremarkable. His mother was gravida 1, para 1. His birth weight was 3420 g, and Apgar score was 9/10. Laboratory findings on admission: hematological examination revealed anemia (Hb 9.2 g/dL) and decreased platelets count ($9 \times 10^3/\text{mm}^3$) and prothrombin time more than 18 seconds, partial prothrombin time more than 78 seconds and fibrinogen level of 1.5 mg/dl. Ultrasonography revealed affluent vessels into the tumor, and computed tomography disclosed a tumor affluent with vessels in the lumbosacral region. The

Yazışma Adresi: Prof. Duran Canatan, MD
Süleyman Demirel University, Medical Faculty,
Department of Pediatric Hematology Isparta, Turkey
E-mail: dcanatan@superonline.com

Müracaat tarihi: 29.09.2010

Kabul tarihi: 11.05.2011

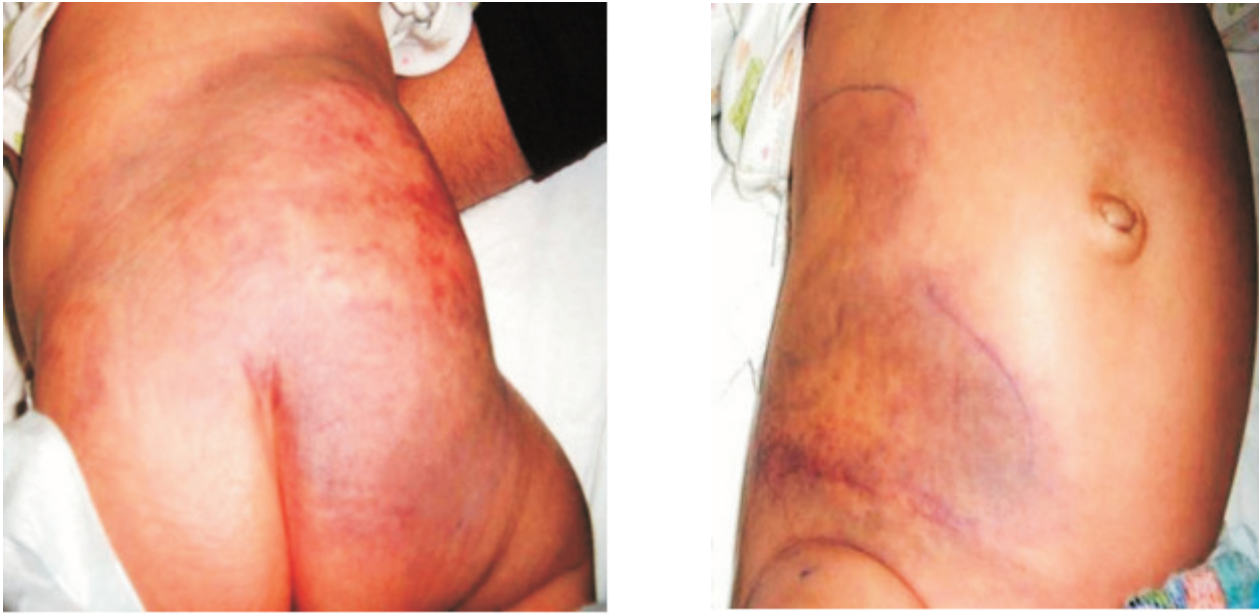


Figure 1. Huge echimotic lesion at presentation

patient was diagnosed as having kaposiform hemangioendothelioma accompanied by KMP. He was immediately treated with intravenous mega dose methylprednisolone pulse therapy (30 mg/kg per day for 3 days and 20 mg/kg per day for the following 4 days) and intravenous fresh frozen plasma. After mega dose methylprednisolone treatment, dose tapered to 2 mg/kg day in three divided dose and continued for four weeks. Course after steroid therapy is seen in (Fig. 2). Although the deep purple discoloration of the lesion resolved a little bit towards pink, platelet and fibrinogen levels did not improve, requiring platelet transfusions and fresh frozen plasma almost daily. His platelet count was between $1-50 \times 10^3/\text{mm}^3$. Then, the patient was lost to follow-up for two weeks. When the patient showed up we learned that interferon was applied in another center during this periods but his condition got worse and congestive heart failure was developed. He was admitted to our pediatric intensive care unit.. After obtaining informed consent from the parents, we started 1 mg/m^2 per dose of Vincristine (VCR) once a week when he was 4 months of age. His hemoglobin level was 9.4 g/dL, platelets count: $6 \times 10^3/\text{mm}^3$ and prothrombin time more than 16.2 seconds, partial prothrombin time 30.3 seconds and fibrinogen level of 91 mg/dl. Reduction of the haemangioma size was recognized after the fourth dose of VCR, the platelet count increased to $115 \times 10^3/\text{mm}^3$ and coagulation abnormality improved at one month of therapy. Then, additional five times of VCR was administered to

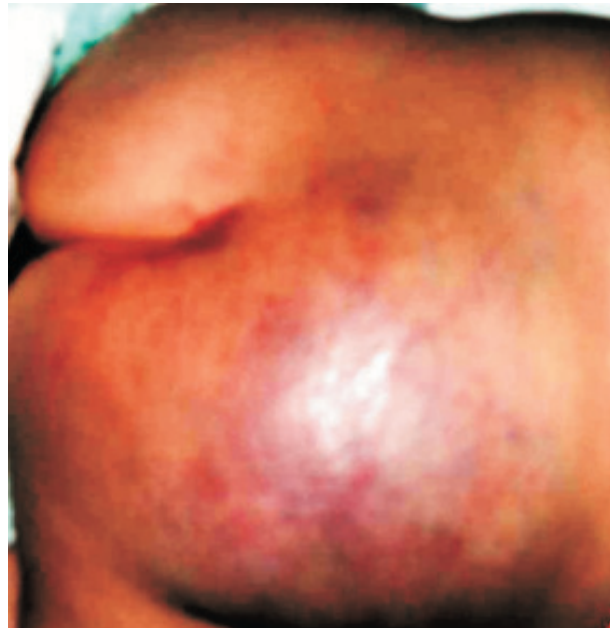

Figure 2. After steroid therapy, thrombocyte and fresh frozen plasma, ecchymoses regresses.

the patient once a month. The platelet count normalized and coagulation abnormality was not detected when he was x months of age (Fig. 3).

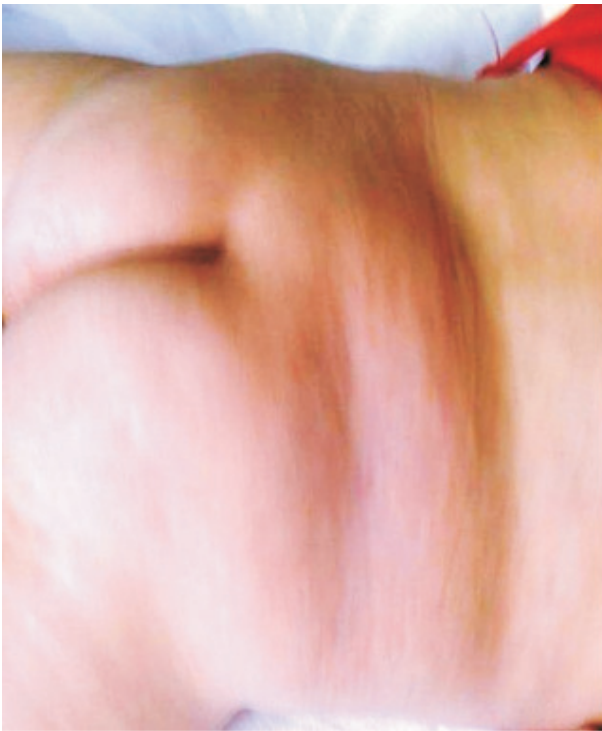

Figure 3. After 2 months of vincristine treatment.

Discussion

Kasabach-Merritt Phenomenon never occurs with the common infantile hemangiomas. Rather it is associated with Kaposiform hemangioendothelioma that is a more invasive vascular tumor and usually present at birth. Contrary to common cutaneous hemangiomas, MRI shows a large and infiltrative lesion involving multiple tissue planes and unsuitable for surgical resection. It is not expected to demonstrate complete regression after thrombocytopenia subsided. Therefore, cure is not expected, but KMP is not usual after infancy. In cases of Kasabach-Merritt phenomenon, heparin or aspirin plus dipyridamole, pentoxifylline, and steroids plus epsilon-aminocaproic acid, fresh frozen plasma have proven to be useful in treating the associated consumptive coagulopathy (5-7). Interferon α 2a or 2b has demonstrated promising results in cases resistant to corticosteroids (8-10). If all of the above treatment modalities fails, chemotherapy with vincristine may be an alternative choice. Most studies showed that vincristine successfully controlled the disease complications (11-15). We tried mega-dose corticosteroid as a first line therapy but his conditions got worse. Interferon-alpha was started in another center and continued for 15 days, there after congestive heart failure developed and radiation therapy was offered.

We started vincristine therapy and got a dramatic answer. Neuropathy is the most expected side effect. With the dosage we applied no side effects were observed. Multimodal treatment with antiproliferative drugs may be selected when bleeding threatens life. Vincristine was also reported to result in less residue which also favors it as a first line choice. Vincristine therapy represents a safe and effective treatment option for the management of those alarming hemangiomas (16).

As a conclusion, vincristine therapy may be suggested instead of multidrugs as first line therapy in patients with KMP.

References

1. Hall GW: Kasabach-Merritt syndrome: pathogenesis and management. *Br J Haematol* 2001;112(4):851-862.
2. Kwok-Williams M, Perez Z, Squire R, Glaser A, Bew S, Taylor R. Radiotherapy for life-threatening mediastinal hemangioma with Kasabach-Merritt syndrome. *2007;49(5):739-44.*
3. Chung T, Hoffer FA, Burrows PE, et al. MR imaging of hepatic hemangiomas of infancy and changes seen with interferon alpha-2a treatment. *Pediatr Radiol* 1996;26(5):341-348.
4. Akyuz C, Yaris N, Kutluk MT, et al. Management of cutaneous hemangiomas: a retrospective analysis of 1109 cases and comparison of conventional dose prednisolone with high-dose methylprednisolone therapy. *Pediatr Hematol Oncol* 2001;18(1): 47-55.
5. Koerper MA, Addiego JE Jr, deLorimier AA, et al. Use of aspirin and dipyridamole in children with platelet trapping syndromes. *J Pediatr* 1983;102(2):311-314.
6. Prost Y, Teillac D, Bodemer C, et al. Successful treatment of Kasabach-Merritt syndrome with pentoxifylline. *J Am Acad Dermatol* 1991;25(5 Pt 1):854-855.
7. Dresse MF, David M, Hume H, et al. Successful treatment of Kasabach-Merritt syndrome with prednisone and epsilon-aminocaproic acid. *Pediatr Hematol Oncol* 1991;8(4):329-334.
8. Ezekowitz A, Mulliken J, Folkman J. Interferon alpha therapy of hemangiomas in newborns and infants. *Br J Haematol* 1991;79(Suppl 1):67-68.
9. Ezekowitz RA, Mulliken JB, Folkman J. Interferon alpha-2a therapy for life-threatening hemangiomas of infancy. *N Engl J Med* 1992;326(22):1456-1463.
10. Harper L, Michel JL, Enjolras O, Raynaud-Mounet N, Rivière JP, Heigele T, De Napoli-Cocci S. Successful management of a retroperitoneal kaposiform hemangioendothelioma with Kasabach-Merritt phenomenon using alpha-interferon. *Eur J Pediatr Surg*. 2006;16(5):369-72.

11. Haisley-Royster C, Enjolras O, Frieden IJ, Garzon M, Lee M, Oranje A, de Laat PC, Madern GC, Gonzalez F, Frangoul H, Le Moine P, Prose NS, Adams DM. Kasabach-Merritt phenomenon: a retrospective study of treatment with vincristine. *J Pediatr Hematol Oncol* 2002;24(6):459-462.
12. Abass K, Saad H, Kherala M, Abd-Elsayed AA. Successful treatment of kasabach-merritt syndrome with vincristine and surgery: a case report and review of literature. *Cases J* 2008;1(1):9.
13. Yesudian PD, Parslew R, Klafowski J, Gould D, Pizer B. Tufted angioma-associated Kasabach-Merritt syndrome treated with embolization and vincristine. *Plast Reconstr Surg*. 2008;121(2):692-3.
14. Thomson K, Pinnock R, Teague L, Johnson R, Manikkam N, Drake R. Vincristine for the treatment of Kasabach-Merritt syndrome: recent New Zealand case experience. *N Z Med J*. 2007;120(1249):U2418.
15. Taki M, Ohi C, Yamashita A, Kobayashi M, Kobayashi N, Yoda T, Horiuchi T, Aikyou M, Horikoshi Y, Mimaya J. Successful treatment with vincristine of an infant with intractable Kasabach-Merritt syndrome. *Pediatr Int*. 2006;48(1):82-4.
16. Hoyoux C: Vincristine treatment for management of alarming hemangiomas in infancy. *Rev Med Liege*.2008;63(1):14-7.