

A case of synovial sarcoma following etanercept use in a patient with rheumatoid arthritis

Yunus Ugan*, Mehmet Sahin*, Sevket Ercan Tunc*, Ozgur Arıcı**, Nilgun Kapucuoglu***, Fatih Ermis****.

*Suleyman Demirel University Faculty of Medicine, Department of Internal Medicine Division of Rheumatology, Isparta, Turkey

**Suleyman Demirel University Faculty of Medicine, Department of Internal Medicine, Isparta, Turkey

***Suleyman Demirel University Faculty of Medicine Department of Pathology, Isparta, Turkey

****Isparta State Hospital, Department of Gastroenterology, Isparta, Turkey

Dear Editor,

New targeted therapies have been noted after illumination of the pathogenesis of rheumatic diseases particularly in rheumatoid arthritis (RA), recently. These are usually cytokine-based therapies, tumor necrosis factor alpha (TNF- α) blocker is one of them. Etanercept which is a soluble TNF- α surface receptor has been reported to be associated with various solid organ tumors development. Here in, we wanted to report a case of synovial sarcoma after 3-months of etanercept therapy in a patient with RA that has never been reported in literature, before. A 73-year-old male patient with active RA referred to our rheumatology clinic. He was diagnosed as RA five years ago. Firstly, there was involvement just only in hand joints, bilateral hip pain started to become for one year. FABERE and FADIR was positive on the right side where FABERE was found to be slightly positive on the left side in physical examination. There was no other joints of arthritis. Laboratory findings were determined as follows: erythrocyte sedimentation rate: 32 mm/h, CRP: 83 mg/L (0-6), RF: 128 IU/ml, anti-CCP(+). Leflunomide 20 mg/day, methotrexate 15 mg/week, sulfasalazine 4000 mg/day, prednisolone 5 mg/day and indomethacin 75 mg/day was commenced firstly. In order to rule out avascular necrosis diagnosis hip MRI was taken. There was no pathological finding except minimal fluid in the joint range. Since DAS 28 score was 5.17, subcutaneous etanercept 25 mg twice weekly was commenced. Pretreatment PPD was determined as 0 mm two times. After chest diseases consultation isoniazid treatment was planned for nine months for tuberculosis prophylaxis. In the third month of treatment a solid mass of 35x30 mm in size 10-12 cm below the knee was determined. Newly diagnosed that immobile mass was painless and fixed under muscle tissue. MR imaging of the right cruris region demonstrated that solid mass had showed malignant character and invaded surrounding tissues (Figure-1). Excisional biopsy of the mass lesion revealed the diagnosis of synovial sarcoma grade III. The most important side effect of TNF- α blockers is development of malignancy. Up to date solid and hematological cancers have been reported in many patients given anti-TNF therapy (1-3). However it had not been understood thoroughly as if it developed due to treatment or due to course of the primary disease or it was just a coincidence. Recently there are some studies reporting that anti-TNF therapy didn't increase the risk of cancer. Lombardy Rheumatology Network (LORHEN) registry is one of them (4). In general, hematologic malignancies such as lymphoma is much more seen than solid organ tumors in anti-TNF therapy receiving patients. In our case the mass in the right cruris appeared in a short period of time such as three months after anti-TNF therapy, etanercept is thought to be as responsible factor. This is the first case report of synovial sarcoma development due to etanercept use in literature.

Key Words: Rheumatoid Arthritis, Synovial Sarcoma, Etanercept

Corresponding Address: Yunus Ugan, MD
Modernevliler Mah. 142. Cadde Boylu Sitesi B Blok 32100/40/4,
Isparta, Turkey.
Phone: 00 90 246 2119219 Fax: 00 90 246 2370240
E-mail: dryunusugan@hotmail.com

Müracaat tarihi: 09.08.2011
Kabul tarihi: 24.05.2012

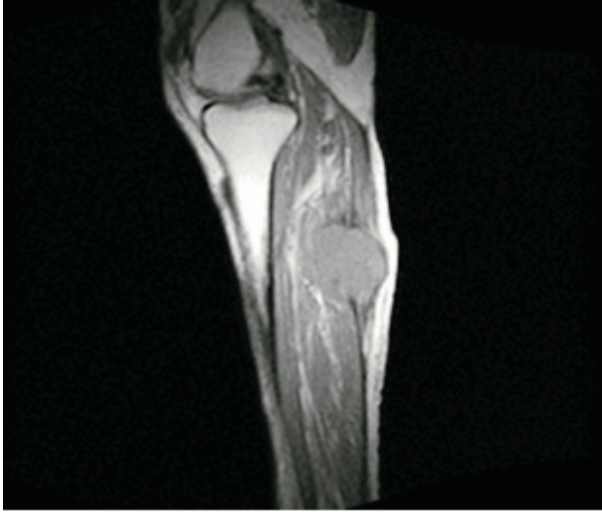


Figure 1: MR image of right cruris

References

1. Simsek I, Pay S, Dinc A, Erdem H, Kurt B. Atypical carcinoid tumor of the thymus with ectopic ACTH production developed during the course of etanercept treatment-case report. *Clin Rheumatol* 2007; 26: 1561-1562.
2. Aksu K, Donmez A, Ertan Y, Keser G, Inal V, Oder G, Tombuloglu M, Kabasakal Y, Doganavsargil E. Hodgkin's lymphoma following treatment with etanercept in ankylosing spondylitis *Rheumatol Int* 2007; 28: 185-187.
3. Cansu DU, Kasifoglu T, Acikalın M, Korkmaz C. The Development of Primary Cutaneous Adenoid Cystic Carcinoma in a Patient with Ankylosing Spondylitis Treated with Etanercept. *South Med J* 2009; 102 : 738-740.
4. Pallavicini FB, Caporali R, Sarzi-Puttini P, Atzeni F, Bazzani C, Gorla R, Marchesoni A, Favalli EG, Montecucco C. Tumour necrosis factor antagonist therapy and cancer development: Analysis of the LORHEN registry. *Autoimmun Rev* 2010; 9: 175-180.