

Comparison of Suture-Button Versus Hook-Plate Fixation for Acromioclavicular Joint Injuries

Osman Yağız Atlı¹  Hüseyin Bilgehan Çevik¹  Hakan Aslan¹ 
Evrin Duman¹ 

¹ Dışkapı Yıldırım Beyazıt Training and Research Hospital, Department of Orthopedics and Traumatology, Ankara, Turkey

Abstract

Background: This retrospective study aimed to compare the clinical and radiological results of clavicular hook plate fixation versus suture-button fixation of acromioclavicular joint (ACJ) dislocations.

Methods: 21 patients are retrospectively evaluated in the present study whom diagnosed as type III-V ACJ dislocations and treated by two different surgical methods. The hook plate group comprised 9 patients to whom acromioclavicular fixation. The suture-button group comprised 12 patients to whom coracoclavicular fixation. All patients were evaluated by Constant Murley Score (CMS) and visual analogue score (VAS). Loss of reduction and radiological results were evaluated with the coracoclavicular distance (CCD).

Results: The average follow-up was 31 months (range, 15–56 months). There was no significant difference between hook-plate and suture-button groups in terms of CMS. However, VAS in hook plate group better than suture-button group ($p = 0.038$). Suture-button fixation adjusted the CCD more than hook plate fixation compared to the opposite shoulder ($p = 0.482$).

Conclusions: There was no statistically significant difference between the hook plate and suture-button group in terms of the clinical outcomes. However, CCD in the suture-button group was better adjusted to the hook plate group. Suture-button fixation is a good option for the treatment of ACJ dislocations, as implant removal may be required in most cases in which the hook plate is applied.

Key words: Acromioclavicular Dislocation, Suture-Button, Hook Plate.

Cite this article as: Atlı OY, Çevik HB, Aslan H, Duman E. Comparison of suture-button versus hook-plate fixation for acromioclavicular joint injuries. Arch Curr Med Res. 2021;2(2):115-120

INTRODUCTION

Acromioclavicular joint (ACJ) dislocation is one of the common shoulder injuries(1, 2). ACJ dislocations associated with acromioclavicular (AC) and coracoclavicular (CC) ligament injuries are radiologically classified as type I-VI according to the Rockwood classification system(3, 4). There is no consensus on which of the several treatment methods reported in the literature should be applied for which type of dislocation(5-8). Therefore, the patient's functional expectation and the orthopedic surgeon's preference guide the choice of treatment.

Good clinical and radiological results have been reported for hook-plate fixation and suture-button fixation, which are widely used nowadays(2, 9). Hook plates keep constant the ACJ for the natural healing of the AC and CC ligaments in ACJ dislocations (10). With suture-button fixation, AC and CC bonds are somewhat imitated and the main advantages of this method are that the implant does not need to be removed (11).

There are a lot of reports comparing the outcomes and complications associated with the surgical treatment of ACJ dislocations. However, it was thought that different studies with different patient groups would contribute to the literature on this subject. Aim of the present study was to compare short-mid-term clinical and radiological results of suture-button and hook plate fixation methods in patients with ACJ dislocation.

MATERIALS AND METHODS

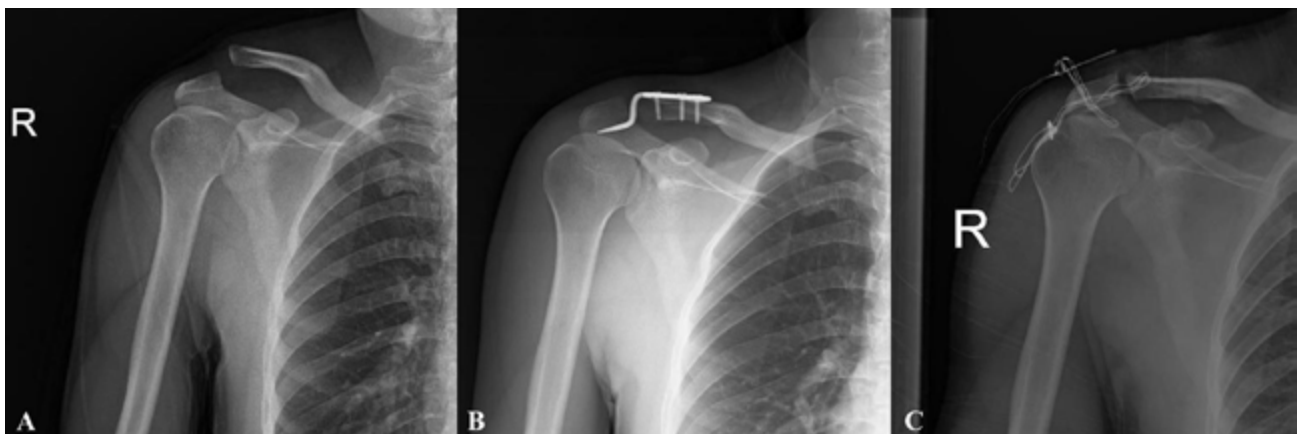
After approval was obtained from Health Sciences University, Dışkapı Yıldırım Beyazıt Training and Research Hospital Ethics Committee (approval number: 100/07, date: 14.12.2020),

This retrospective cohort study was initiated. A retrospective review was made of all cases of ACJ dislocation surgically treated using either hook plate or suture-button fixation in our clinic between January 1st, 2016 and July 30th, 2020. The electronic documentation system review revealed 24 cases of ACJ dislocation. Patients were excluded from study if they have chronic (more than two weeks after trauma) ACJ dislocation, type I, II, VI ACJ dislocation, surgical fixation other than either hook plate fixation or suture-button fixation, concomitant injuries to ipsilateral upper limb, and less than 1-year follow-up. Three patients were excluded including chronicity of ACJ dislocation (n:1), different surgical technique (n:1), and concomitant proximal humeral fracture (n:1). Of the 24 patients, 3 patients excluded from the study, so the study was conducted with evaluation of 21 patients.

Surgical Technique for Hook-Plate Application

All the patients were operated on under general anesthesia in the beach-chair position by the several different orthopedic surgeons. The skin over the distal clavicle towards the acromion was incised. After anatomical reduction in the ACJ, an anatomical hook plate (Zimed®, Gaziantep, Turkey) was inserted in the subacromial space (Figure 1). After that, the hook plate was fixed to the distal clavicle with cortical and/or locking screws. The position of the hook plate and reduction of ACJ were controlled under fluoroscopy. The operated shoulders were immobilized with an arm sling for 4-6 weeks.

Figure 1. (A) Preoperative radiograph of patient with acute right ACJ dislocation (B) The post-operative radiograph of patient after hook plate fixation after 3 months of surgery (C) The hook plate was removed after 1 year of surgery

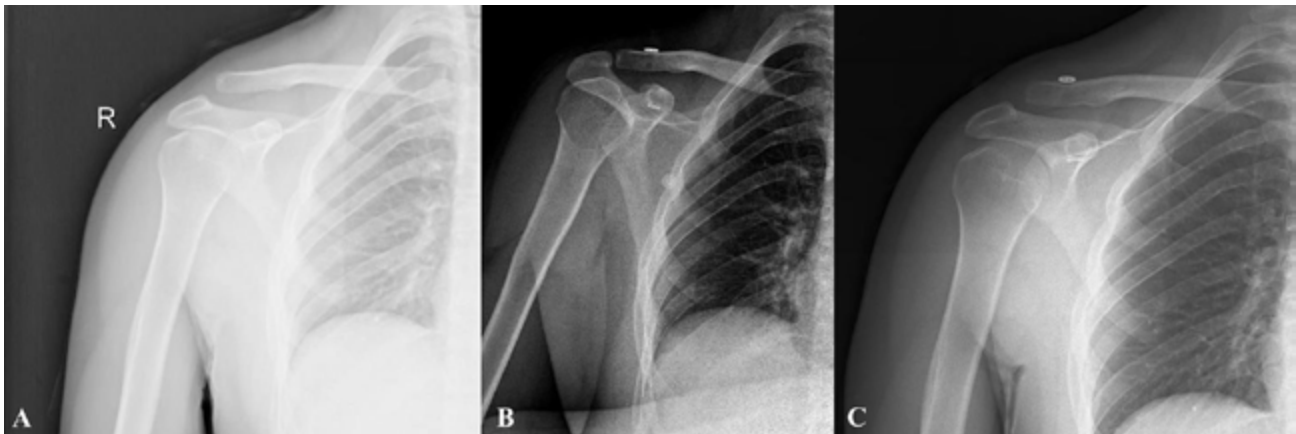


Surgical Technique for Suture-Button Application

An approximately 5-cm skin incision was made extending from the distal clavicle towards the coracoid process. The ACJ was then manually reduced and a smooth K-wire was drilled from 2 cm medial of the ACJ to the coracoid. The bony tunnels were done using subsequent over-drilling of the K-wire with a 4.0 mm cannulated drill in the clavicle and coracoid. Using a passing wire, the suture-button device (Aleda, Ankara, Turkey) was passed with the

oblique metal button first through the clavicle and then through the coracoid (Figure 2). After the coracoid passage of the button was flipped to the horizontally by pulling one of two traction sutures. The proximal round button was advanced until touch with the superior surface of the distal clavicle. The position of the buttons and reduction of ACJ were controlled under fluoroscopy. The suture button device was tensioned and tied with a locking knot. The operated shoulders were immobilized with an arm sling for 3-4 weeks.

Figure 2. (A) Preoperative radiograph of patient with acute right ACJ dislocation (B) The post-operative radiograph of patient after suture-button fixation after 3 months of surgery (C) The loss of reduction of ACJ after 1 years of surgery



Postoperative Management

Pendulum exercises were started in the immediate post-operatively for both hook-plate and suture-button groups. The exercises progressed gradually, according to the patient's pain tolerance, to achieve passive and passive assisted abduction. Active range of motion was allowed after 6th weeks. In the postoperative period, the patients were advised to avoid movements such as heavy lifting that would cause a significant downward traction in the upper limb until the fourth month. The rehabilitation protocols were explained to the patients, the necessary training was given and they were made to do it on their own at home. All patients were followed up clinically and radiologically for a period of 12 months. The clinical and radiological evaluations were performed immediately postoperatively, then at 2 and 6 weeks, 3, 6 and 12 months. The hook plates of 2 patients were removed in the postoperative 1st year.

Evaluations

A total of 21 patients were included in study. Functional results were evaluated using the Constant Murley Score (CMS)(12) and the visual analogue scale (VAS) for pain by two independent orthopedic surgeons post-operatively. CMS is divided into four subscales, including pain (15 points maximum), activities of daily living (20 points maximum), range of motion (40 points maximum), and strength (25 points maximum). A higher score corresponds to a higher quality of function (minimum 0, maximum 100). Radiological results were evaluated with the coracoclavicular distance (CCD).

Statistical Analysis

The sample size was calculated with an open source online application (<http://www.openepi.com/>) based on a 20% difference in functional scores between the 2

treatment groups with an alpha level of 5% and a power of 80%. Consequently, Inclusion of five patients for each group suggested (13). However, all patients who was appropriate for inclusion and exclusion criteria was added to analysis. Statistical analysis was performed using SPSS for Windows, version 19 (SPSS Inc, Chicago, Illinois). Chi-square test was used for the comparison of categorical variables. The data does not conform to the normal distribution due to the limited number of sample size, thus the non-parametric analysis was performed. Mann Whitney U was used to compare suture-Button and hook-plate fixation. The means were compared between the groups, with 95% confidence intervals and a p value of less than 0.05 was considered statistically significant.

RESULTS

The mean follow-up period was 31 ± 11.2 months (range: 15–56 months). The general characteristics of patients was given in Table 1. Postoperatively, the mean modified CMS value was 83.8 ± 14.7 (range: 51–98), the mean VAS was 2.0 ± 1.9 (range: 0–6). There were no statistically significant differences in the preoperative injury-related variables including the time between trauma and surgery, age, Rockwood classification of ACJ injury or CCD between the two groups. At the last final follow-up visit, there were no significant difference between hook-plate and suture-button groups in terms of CMS. However, VAS in hook plate group better than suture-button group ($p:0.038$) (Table 2). Suture-button fixation compared to the opposite shoulder was normalized the CCD more than hook plate fixation ($p:0.482$).

Table 1. The general characteristics of patients

	Hook plate	Suture-button	Total
Age	43.4±11.1	44.1±17.4	43.8±14.7
Gender (n)			
Female	0	2	2
Male	9	10	19
Trauma Type(n)			
Sport	2	3	5
Traffic accident	2	2	4
Fall	5	7	12

Table 2. The clinical and radiological results of patients (mean ± standard deviation) (CMS: Constant Murley Score; VAS: Visual Analogue Score; CCD: Coracoclavicular distance)

	Hook plate	Suture-button	p	
CMS	90.5 ± 3.5	78.7 ± 17.8	0.064	
VAS	1 ± 1	2.7 ± 2.2	0.038	
CCD	Pre-operative	19.1 ± 3.6	17.5 ± 4.1	0.361
	Post-operative	7.7 ± 3.2	8.3 ± 2.5	0.645

At the final follow-up visit, all patients were observed to have full shoulder joint range of motion. There were no complications including vascular or nerve damage in any patient intra-operatively. In follow-up, there were 6 patients with complications including 3 ACJ arthritis in hook plate group, and 3 reduction loss in suture-button group. In the present study, the hook plate was removed due to pain in a patient with ACJ arthritis.

DISCUSSION

In the present study, we compared the clinical and radiological outcomes of patients who underwent hook plating and suture-button fixation for type III-V ACJ dislocation. There was no statistically significant difference between both groups in respect of clinical and radiological findings.

Typically, ACJ injuries result from direct trauma from a fall or in contact sports when the arm is in an adducted position. There are acromioclavicular fixation, coracoclavicular fixation, and dynamic muscle transfer methods for management of ACJ dislocations. Of course, conservative approach may be preferred for type III ACJ dislocations according to some authors (14, 15). On the other hand, the superiority of surgical treatment for ACJ dislocations has also been reported (2, 8). The debate about the choice of conservative and surgical treatment for ACJ dislocations and which surgical treatment to choose still continues.

Some complications are encountered in both conservative and surgical treatment including implant failure, superficial wound infection, ACJ arthrosis and persistent pain (2, 5, 10, 16). In the present study, the patients who have Type III-V ACJ dislocations, hook plate group had

3 arthritis and suture-button group had reduction loss. Among the patients in the study, the worst clinical results in terms of VAS and CMS evaluations were seen in these patients.

It has been reported that early surgical treatment is associated with low complication rate and high patient satisfaction in ACJ dislocations (17, 18). In the present study, on the other hand, we did not have the opportunity to compare the early and late surgical interventions, as there were no patients who underwent late surgical treatment.

It is known that there is an inverse relationship between ACJ reduction and arthritis (19, 20). Although degenerative changes of ACJ are generally seen radiologically, poor reduction of ACJ does not affect the clinical outcomes (21). The fact that the reduction loss observed in 3 patients in the suture-button group in the present study did not significantly affect the clinical results confirms this finding.

The hook-plate is a useful and easy applicable device for the treatment of ACJ dislocations. Although the main concerns in the application of hook plates are subacromial impingement, acromial osteolysis or needing implant removal, there were no significant differences in complications between the two techniques (22, 23). Because of such complications, implant removal is recommended. Implant removal was performed in only one of the patients in the present study. Other patients did not want a second surgical intervention, but this did not negatively affect the clinical results.

Bin Abd Razak et al. stated that suture-button had a significantly better CMS than hook plate fixation in short-term outcomes (2). Furthermore, they also found a significantly better shoulder abduction of suture-button than hook plate fixation at 6th months. The authors stated that the superiority of suture-button over hook plate fixation might be explained by the necessity of secondary surgical intervention for removal of hook plate. The current literature presented superior clinical results about suture button fixation unlike the present study (2, 10). The suture-button used in the patients in the present study was of UHMWPE structure which had higher failure load (24). Therefore, the better clinical results in the hook plate group compared to suture-button group in this study may

be due to a surgical technique rather than the implant used. However, the retrospective nature of the study prevents us from reaching more information on this subject.

Biomechanical complications have been reported for both techniques in the literature. In the hook plate technique, the most common complication was reported as re-dislocation of ACJ after removal of the implant (25). Sun et al. reported that it was developed loss of reduction in 30 (23.1%) of 130 patients in suture-button technique (26). In the present study, there was not enough data in the hook plate group for comparison. In addition, loss of reduction was detected in 3 of 12 patients in the suture-button group. Although not statistically significant, suture-button fixation, except 3 patients with loss of reduction, shortened the CCD more than hook plate fixation compared to the opposite shoulder.

There were several limitations of this present study. There was retrospective design, limited number of patients, and no long-term results. Another limitation was that the patients in the present study was operated by more than one surgeon. Also, due to the retrospective nature of the study, no evaluation has been made on type 3 ACJ subgroups.

In conclusion, there was no statistically significant difference between the hook plate and suture-button group in terms of the clinical outcomes. However, the suture-button technique was normalized CCD more than hook plate, as implant removal may be required in most cases in which the hook plate was applied. Although both techniques have positive and negative aspects, the orthopedic surgeon can determine which technique to use by considering them.

Declarations of interest: None

Ethical Approval: The study protocol was approved by the Health Sciences University, Dışkapı Yıldırım Beyazıt Training and Research Hospital Ethics Committee (Date: 14.12.2020, No: 100/07). The study was conducted in accordance with the principles of the Declaration of Helsinki.

Source of funding: No external funding was received in support of this work.

Disclosure: None of the authors received payments or services, either directly or indirectly (i.e., via his or her institution), from a third party in support of any aspect of this work.

No author has had any other relationships, or has engaged in any other activities, that could be perceived to influence or have the potential to influence what is written in this work.

REFERENCES

- Oussedik S. Injuries to the clavicle and acromioclavicular joint. *Br J Hosp Med (Lond)*. 2007;68(4):M68-70.
- Bin Abd Razak HR, Yeo EN, Yeo W, Lie TD. Short-term outcomes of arthroscopic TightRope® fixation are better than hook plate fixation in acute unstable acromioclavicular joint dislocations. *Eur J Orthop Surg Traumatol*. 2018;28(5):869-75.
- Rieser GR, Edwards K, Gould GC, Markert RJ, Goswami T, Rubino LJ. Distal-third clavicle fracture fixation: a biomechanical evaluation of fixation. *J Shoulder Elbow Surg*. 2013;22(6):848-55.
- Rockwood C. Injuries to the acromio-clavicular joint. Fracture in adults. 1984;1.
- Mardani-Kivi M, Mirbolook A, Salariyeh M, Hashemi-Motlagh K, Saheb-Ekhtiari K. The comparison of Ethibond sutures and semitendinosus autograft in the surgical treatment of acromioclavicular dislocation. *Acta Orthop Traumatol Turc*. 2013;47(5):307-10.
- Kezunović M, Bjelica D, Popović S. Comparative study of surgical treatment of acromioclavicular luxation. *Vojnosanit Pregl*. 2013;70(3):292-7.
- Basyoni Y, El-Ganainy AE, Aboul-Saad M. Acromioclavicular joint reconstruction using anchor sutures: surgical technique and preliminary results. *Acta Orthop Belg*. 2010;76(3):307-11.
- Bannister GC, Wallace WA, Stableforth PG, Hutson MA. The management of acute acromioclavicular dislocation. A randomised prospective controlled trial. *J Bone Joint Surg Br*. 1989;71(5):848-50.
- Johansen JA, Grutter PW, McFarland EG, Petersen SA. Acromioclavicular joint injuries: indications for treatment and treatment options. *J Shoulder Elbow Surg*. 2011;20(2 Suppl):S70-82.
- Wang C, Meng JH, Zhang YW, Shi MM. Suture button versus hook plate for acute unstable acromioclavicular joint dislocation: A meta-analysis. *Am J Sports Med*. 2020;48(4):1023-30.
- Mares O, Luneau S, Staquet V, Beltrand E, Bousquet PJ, Maynou C. Acute grade III and IV acromioclavicular dislocations: outcomes and pitfalls of reconstruction procedures using a synthetic ligament. *Orthop Traumatol Surg Res*. 2010;96(7):721-6.
- Constant CR, Murley AH. A clinical method of functional assessment of the shoulder. *Clin Orthop Relat Res*. 1987(214):160-4.
- Zhang L, Zhou X, Qi J, Zeng Y, Zhang S, Liu G, et al. Modified closed-loop double-endobutton technique for repair of Rockwood type III acromioclavicular dislocation. *Exp Ther Med*. 2018;15(1):940-8.
- Darrow JC, Jr., Smith JA, Lockwood RC. A new conservative method for treatment of Type III acromioclavicular separations. *Orthop Clin North Am*. 1980;11(4):727-33.
- Schlegel TF, Burks RT, Marcus RL, Dunn HK. A prospective evaluation of untreated acute grade III acromioclavicular separations. *Am J Sports Med*. 2001;29(6):699-703.
- Lancaster S, Horowitz M, Alonso J. Complete acromioclavicular separations. A comparison of operative methods. *Clin Orthop Relat Res*. 1987(216):80-8.
- Rolf O, Hann von Weyhern A, Ewers A, Boehm TD, Gohlke F. Acromioclavicular dislocation Rockwood III-V: results of early versus delayed surgical treatment. *Arch Orthop Trauma Surg*. 2008;128(10):1153-7.
- Weinstein DM, McCann PD, McIlveen SJ, Flatow EL, Bigliani LU. Surgical treatment of complete acromioclavicular dislocations. *Am J Sports Med*. 1995;23(3):324-31.
- Broos P, Stoffelen D, Van de Sijpe K, Fourneau I. [Surgical management of complete Tossy III acromioclavicular joint dislocation with the Bosworth screw or the Wolter plate. A critical evaluation]. *Unfallchirurgie*. 1997;23(4):153-9; discussion 60.
- Choi NH, Lim SM, Lee SY, Lim TK. Loss of reduction and complications of coracoclavicular ligament reconstruction with autogenous tendon graft in acute acromioclavicular dislocations. *J Shoulder Elbow Surg*. 2017;26(4):692-8.
- Taft TN, Wilson FC, Oglesby JW. Dislocation of the acromioclavicular joint. An end-result study. *J Bone Joint Surg Am*. 1987;69(7):1045-51.
- Chen CY, Yang SW, Lin KY, Lin KC, Tarng YW, Renn JH, et al. Comparison of single coracoclavicular suture fixation and hook plate for the treatment of acute unstable distal clavicle fractures. *J Orthop Surg Res*. 2014;9:42.
- Pan X, Lv RY, Lv MG, Zhang DG. Tight rope vs clavicular hook plate for Rockwood III-V acromioclavicular dislocations: A meta-analysis. *Orthop Surg*. 2020;12(4):1045-52.
- Hapa O, Akşahin E, Erduran M, Davul S, Havıtcıođlu H, LaPrade RF, et al. The influence of suture material on the strength of horizontal mattress suture configuration for meniscus repair. *Knee*. 2013;20(6):577-80.
- Kienast B, Thietje R, Queitsch C, Gille J, Schulz AP, Meiners J. Mid-term results after operative treatment of rockwood grade III-V acromioclavicular joint dislocations with an AC-hook-plate. *Eur J Med Res*. 2011;16(2):52-6.
- Sun LJ, Lu D, Tao ZY, Yu XB, Hu W, Ma YF, et al. Analysis of risk factors for loss of reduction after acromioclavicular joint dislocation treated with the suture-button. *J Orthop Sci*. 2019;24(5):817-21.